



Correction to: Bilateral atypical ulnar fractures occurring after long-term treatment with bisphosphonate for 7 years and with teriparatide for 2 years: a case report

Y. Asano¹ · K. Tajiri¹ · S. Yagishita¹ · H. Nakanishi¹ · T. Ishii¹

Published online: 20 October 2020

© International Osteoporosis Foundation and National Osteoporosis Foundation 2020

Correction to: Osteoporosis International

<https://doi.org/10.1007/s00198-020-05618-3>

The original version of this article, published on 10 September 2020 contained a mistake.

Figure 2 was shown incorrectly. The correct version is given below:

The original article has been corrected.

The online version of the original article can be found at <https://doi.org/10.1007/s00198-020-05618-3>

✉ Y. Asano
you.you.mounin@gmail.com

¹ Department of Orthopaedic Surgery, Municipal Tsuruga Hospital, 1-6-60, Mishimamachi, Tsuruga-shi, Fukui 914-8502, Japan

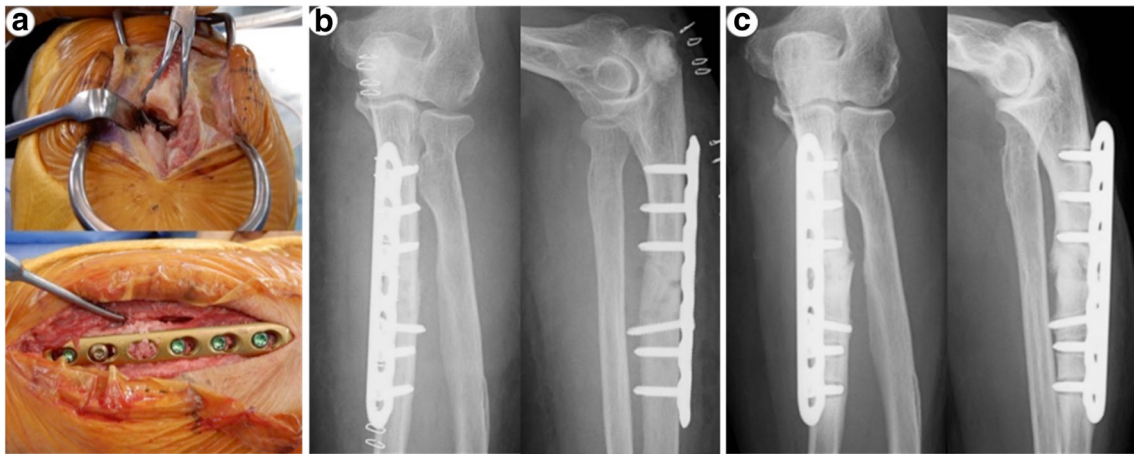


Fig. 2 **a** Intraoperative photographs showed cortical thickening and osteosclerotic changes at the fracture site, and an autologous cancellous bone graft from the ipsilateral olecranon was inserted. **b** Postoperative plain radiography. **c** Plain radiography of 1 year after surgery

Publisher's note Springer Nature remains neutral with regard to jurisdictional claims in published maps and institutional affiliations.