



Anterior bilateral sacrospinous ligament fixation with concomitant anterior native tissue repair: a pilot study

Charlotte Delacroix¹ · Lucie Allegre¹ · Kyriaki Chatziioannidou^{1,2} · Armance Gérard¹ · Brigitte Fatton¹ · Renaud de Tayrac¹

Received: 24 October 2021 / Accepted: 4 January 2022 / Published online: 28 February 2022
© The International Urogynecological Association 2022

Abstract

Introduction and Hypothesis Anterior bilateral sacrospinous ligament fixation (ABSSLF) was first described in 2000 but only evaluated in a limited number of studies. However, due to the FDA's ban on transvaginal mesh, interest in this technique has re-emerged. The SSLF procedure is known for its inherent high risk for anterior compartment failure; hence, in our center we started performing a preemptive concomitant anterior repair with the intention to reduce such risk. The aim of this study was to review the feasibility and clinical outcomes of this innovative technique.

Methods We performed a retrospective cohort study of all the women who had an ABSSLF and a concomitant anterior native tissue repair between May 2019 and July 2020 in a tertiary hospital in France. Our primary endpoint was surgical feasibility, while as secondary endpoints we wanted to explore the perioperative morbidities and clinical outcomes associated with this technique.

Results A total of 50 women were operated on in the studied period. The median follow-up time was 10 [8.5] months. It was feasible to perform the combined ABSSLF and concomitant anterior native tissue repair in all cases. The most frequent perioperative complications reported were urinary tract infection (14%) and difficulty in resuming voiding (16%). Anatomical and functional results were improved. The rate of anterior compartment recurrence was 37%.

Conclusions ABSSLF with a concomitant anterior native tissue repair is feasible and relatively safe for treating anterior and apical pelvic prolapse. However, anterior compartment failure rate is still a limitation. Further larger studies with long-term anatomical and functional results comparing this technique to alternative transvaginal surgical approaches are needed.

Keywords Anterior approach · Bilateral sacrospinous ligament fixation (BSSLF) · Native tissue repair · Pelvic organ prolapse · Uterosacral ligament suspension · Vaginal prolapse repair

Abbreviations

ABSSLF	Anterior bilateral sacrospinous ligament fixation
FDA	Food and Drug Administration
QoL	Quality of life
POP-Q	Pelvic Organ Prolapse Quantification
SSLF	SacroSpinous ligament fixation

Introduction

Pelvic organ prolapse (POP) occurs in up to 50% of women who have given birth [1]. POP is a pathology that impacts the quality of life of patients and whose prevalence, and hence its management, is increasing because of the aging of the population [2]. Currently, different surgical techniques, using laparoscopic and vaginal approaches, are commonly used to treat concomitant anterior and apical prolapse. However, vaginal surgery remains widespread and has many benefits including the possibility of locoregional anesthesia, lower morbidity, ability to simultaneously manage stress incontinence, the possibility to treat isolated cystoceles or rectoceles, an alternative option to manage recurrences following sacrocolpopexy and a significantly lower mean cost compared to abdominal or laparoscopic sacrocolpopexy [3].

✉ Charlotte Delacroix
cha.delacroix@gmail.com

¹ Urogynecology Unit, Nimes University Hospital, Nimes, France

² Urogynecology Unit, GHOL Group, Nyon Hospital, Nyon, Switzerland

Vaginal mesh surgery has recently become a widely used technique worldwide. Although associated with improved anatomical results and reduced recurrence rates, there have been concerns about increased morbidities [1]. This led to the eventual FDA ban on the sale and distribution of surgical mesh intended for transvaginal repair of anterior compartment prolapse in 2019 [4]. Since that date, surgeons have had to provide patients with alternative transvaginal procedures that are effective and safe for the treatment of anterior compartment defects. Therefore, surgical techniques utilizing native tissue repairs have come back into the spotlight.

Vaginal sacrospinous ligament fixation (SSLF) is one of the most commonly performed approaches [3]. This technique corrects the prolapse by attaching the cervix or vaginal vault to the sacrospinous ligament with a non-absorbable suture that passes through an opening in the paravaginal or pararectal space depending on whether the approach is anterior or posterior, respectively. It can be performed unilaterally or bilaterally. The procedure risks injuries to the bladder, rectum, pudendal nerve and artery, inferior gluteal artery and sciatic nerve [5]. Initially described by Richter in 1968 [6], SSLF is usually performed unilaterally [7–9] via a posterior approach [6]. However, the choice of the technique and approach influences the anatomical results and recurrence risks. The posterior approach tends to deviate the vaginal apex downwards leaving the anterior compartment more vulnerable to recurrent POP [10, 11]. Therefore, some authors recommend a bilateral approach allowing the vagina to lie in a more horizontal plane and hence lowering the incidence of postoperative cystocele recurrence, proximal vaginal narrowing, de novo dyspareunia and bowel dysfunction [12, 13]. Furthermore, performing a bilateral anterior approach would additionally offer the possibility to perform a concomitant anterior repair in an attempt to reduce anterior compartment recurrences and better respect the natural vaginal axis.

The anterior bilateral sacrospinous ligament fixation (ABSSLF) was first described in 2000 by Cespedes [14]. In his work he reported that the technique was easy to learn and reproduce and that the sacrospinous ligament was easier to visualize and be accessed through an anterior approach with good safety and anatomical results.

Furthermore, Cespedes postulated that bilateral fixation should provide additional support and better long-term outcomes over a single fixation point by increasing the vaginal area above the pelvic floor, thus improving the ability of the vagina to withstand increased intra-abdominal pressure.

Although more recent reports on this technique seem to show good anatomical results with low morbidity [13], there are a limited number of studies that have assessed bilateral fixation using anterior vaginal dissection. Additionally, the high rate of anterior recurrence after SSLF, which seems to occur in more than a third of cases [15], provides

justification for the idea of performing a preemptive concomitant anterior repair [16]. It is for these reasons that we wanted to review the results of a combined ABSSLF and a preemptive concomitant anterior native tissue repair that we started to systematically perform in our unit in 2019. The main aim of this work was to evaluate the surgical feasibility of this approach. As secondary objectives, we wanted to explore the perioperative morbidities, anatomical and functional outcomes associated with this technique.

Materials and methods

This was a retrospective cohort study that included all women who had an ABSSLF with a concomitant anterior native tissue repair between May 2019 and July 2020 in a tertiary urogynecology unit in France. The operative indications for ABSSLF were: POPQ stage ≥ 2 with cystocele and/or apex prolapse ≥ -1 , failure of conservative management and indication for vaginal surgery. All surgical procedures were performed by or under the direct supervision of qualified urogynecologists experienced in this technique. IRB approval was granted for the study by the Delegation for Clinical Research and Innovation of Nimes Hospital on 17 September 2020 (no. 20.09.05).

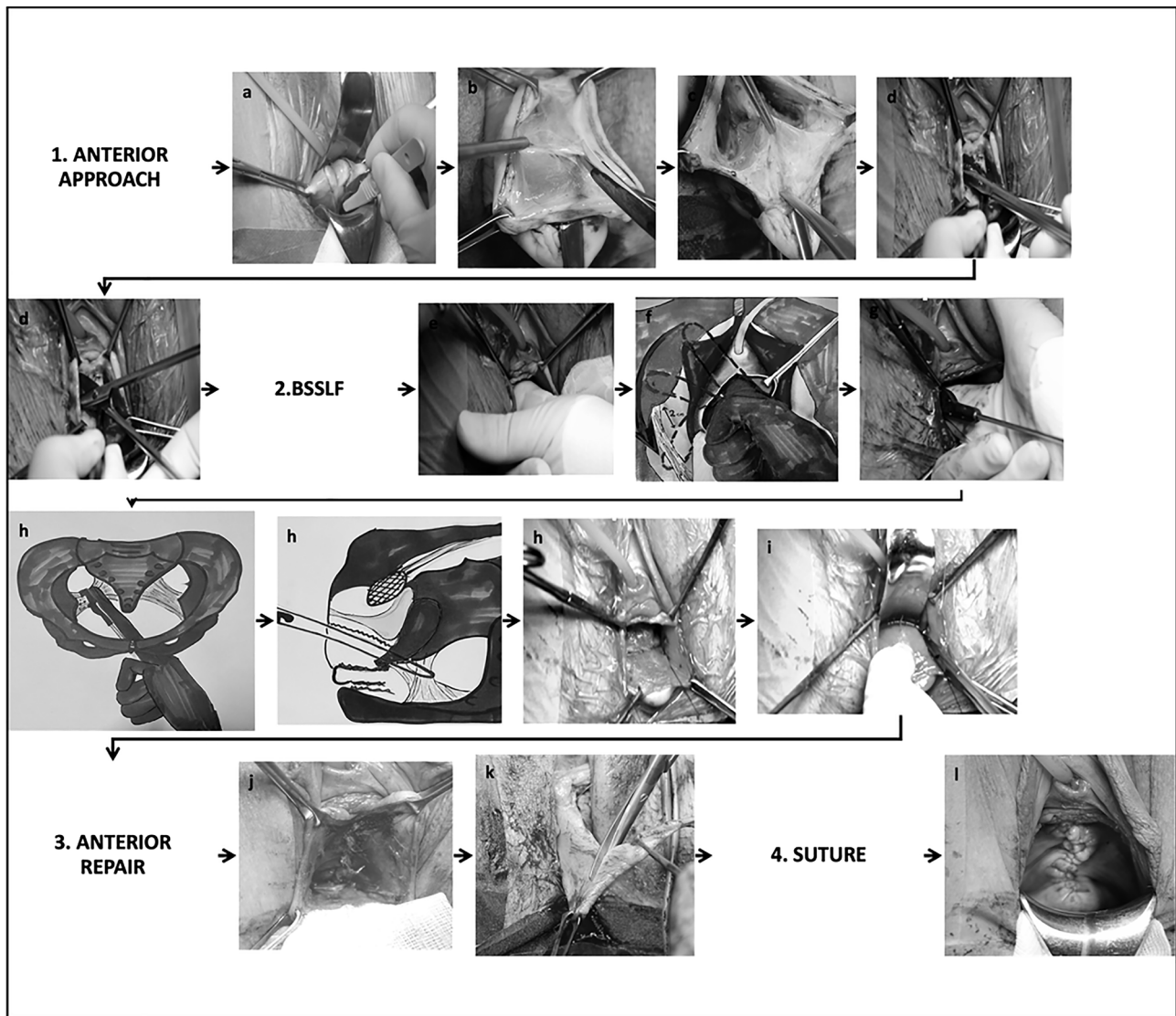
Surgical technique

The surgical steps are shown in Fig. 1. Following infiltration of the anterior vaginal wall, a midline anterior colpotomy extended approximately 3 cm below the urethral meatus to about 2 cm before the cervix. The paravesical spaces were then opened bilaterally to expose both sacrospinous ligaments, which were bluntly dissected.

A polypropylene suture was inserted on either side, approximately 2 cm medial to the ischial spines using a Capio Slim device (Capio Slim™ Boston Scientific, Montigny-le-Bretonneux, France). These were anchored with stitches to the anterior part of the cervix (or the uterosacral ligaments in case of a previous or planned concomitant hysterectomy). Some surgeons used a tape attached to the cervix and crossed by propylene yarn (Advantage Fit™ Boston Scientific, Montigny-le-Bretonneux, France) to strengthen the cervical stitches. For the anterior repair, the vesicovaginal fibromuscular tissue was placated followed by a vaginal wall repair (colporrhaphy). Any additional concomitant surgeries were performed at the surgeon's discretion and medical indication; these included hysterectomy, rectocele repair and midurethral sling.

Endpoints

The primary endpoint was the feasibility of surgery defined as the ability to perform an ABSSLF with a



1. Anterior approach : a. anterior deep incision, b. cystocele dissection, c. cervix exposition, d. paravesical fossa opening and dissection, **2. BSSLF** : bilateral sacrospinous ligament fixation : e. spine and sacrospinous ligament palpation, f. blunt dissection, g. capio introduction, h. one polypropylene suture (n°0) on both sacrospinous ligament, i. stitch on the cervix, **3. Anterior repair** : j. anterior colporrhaphy, k. vaginal resection if needed, **4. Suture** : l. vaginal closure

Fig. 1 Surgical technique

concomitant anterior native tissue repair. The secondary endpoints for the study were perioperative morbidities and clinical outcomes. The perioperative complications were reported based on the Clavien-Dindo [17] and ICS-IUGA classifications [18]. Clinical efficacy was assessed between 6 and 12 months after surgery. Anatomical success was objectively assessed by a clinician independent of the study team using the POP-Q score [19], where a

score signifying a POP-Q stage ≥ 2 in the compartment(s) operated on was used as a cut-off for recurrence. The functional results were measured using the validated French versions of the Pelvic Organ Prolapse/Urinary Incontinence Sexual Questionnaire (PISQ-IR) [20], the Pelvic Floor Distress Inventory (PFDI-20) questionnaire, the Pelvic Floor Impact Questionnaire (PFIQ-7) [21] and the Patient Global Impression scale Index (PGI-I) [22].

Statistical analysis

Data on clinical characteristics are presented as numbers and frequencies for categorical data and as medians and interquartile ranges [IQR] for continuous data.

Continuous variables were compared using Student's *t*-test or Mann-Whitney test when normal distribution was not verified, while categorical data were compared using chi-square test. The comparison of QoL scores and mean POP-Q scoring between baseline and follow-up was calculated using paired Student's *t*-test or paired Wilcoxon test according to the variable distribution. The threshold of significance was set at 5%. Data analysis were performed using R 2.9.2 (R Development Core Team (2009), R Foundation for Statistical Computing, Vienna, Austria) and XLStat [23].

Results

A total of 50 women were listed for ABSSLF and a concomitant anterior native tissue repair between May 2019 and July 2020. The baseline characteristics of the patients are summarized in Table 1. The median age was 72 years and the median parity was two children. All study participants were menopausal at the time of surgery.

According to the preoperative POP-Q scores, 36 (72%) patients had an apical and/or anterior prolapse stages III–IV and 6 women had previous prolapse surgery.

The main preoperative reported symptoms were urinary and included difficulty in micturition [$n = 30$ (60%)], stress

urinary incontinence [$n = 17$ (34%)] and an overactive bladder [$n = 16$ (32%)].

The operative parameters and perioperative complications are summarized in Table 2. The procedure was feasible in all cases; of these, 37 (74%) patients had a hysteropexy while 13 (26%) patients had uterosacral ligament fixation to the sacrospinous ligaments due to 10 (20%) and 3 (6%) concomitant and previous hysterectomies, respectively. The median length of hospital stay was 3 [2] days. The rate of postoperative morbidity was 40%. The majority of these were Clavien-Dindo II (34%) and mostly urinary related in the form of urinary tract infection [$n = 7$ (14%)] and postoperative urinary retention [$n = 8$ (16%)] resolved by self-catheterization. There was one serious complication that resulted in left renal colic and acute renal failure secondary to ureteric kinking. However, this resolved with a ureteric catheter without the need for SSLF reoperation.

The median follow-up time was 10 [8.5] months. Compared to baseline, the POP-Q score showed significant improvement in all compartments, and the POP-Q stage was \leq I in 27 women (59%). Three patients (6%) were classified as stage II and one patient (2%) stage III on POP-Q because of a de novo rectocele (Table 3). No apical or posterior recurrences were reported. Nevertheless, using our a priori set cut-off, 17 patients (37%) in the study cohort had evidence of an anterior compartment recurrence. However, all these recurrences were limited to stage II ($Ba \leq 1$). There was improvement in most symptoms postoperatively including difficulty in micturition ($p < 0.001$), stress urinary incontinence ($p = 0.3$), overactive bladder ($p = 0.3$) and sexual activity ($p = 0.1$). However, there was a trend to worsening in reported constipation, but this did not reach statistical significance [$n = 15$ (3%) vs. $n = 13$ (2.6%), $p = 0.5$]. Two patients (4%) underwent a mid-urethral sling procedure for de novo stress urinary incontinence at 2 and 10 months after their prolapse surgery, respectively.

Regarding functional outcomes, the patient global impression scale (PGI) showed good results with 98% of patients reporting considering themselves to be in a “very much better” or “much better” condition compared to before the operation (Table 4). In general, the PFDI-20 and PFIQ-7 questionnaires showed low scores indicating improved QoL. Nonetheless, higher scores tended to be related to the urinary items. The PSIQ-IR showed a weak impact of the condition on sexual function for women who were not sexually active, except for the partner-related items. However, the scores for sexually active women indicated good sexual function (Table 4).

Discussion

This retrospective study confirms that anterior bilateral sacrospinous fixation using the vaginal non-mesh approach combined with an anterior native tissue repair is a feasible

Table 1 Baseline characteristics of the study population ($n = 50$)

	Median [IQR] or n (%)
Demographics	
Age	72 [8]
BMI	24 [7]
Parity	2 [2]
Postmenopausal	49 (98)
Diabetics	6 (12)
Smoker	3 (6)
Prior surgeries	
Hysterectomy	3 (6)
Prolapse surgery	6 (12)
Urinary incontinence surgery	2 (4)
Sexually activity status	
Sexually active	32 (71)
Not sexually active	13 (29)
Unknown	5

BMI body mass index

Table 2 Operative parameters and perioperative complications (n = 50)

	Median [IQR] or n (%)
Anesthesia	
General	34 (68)
Spinal	16 (32)
Local	0
Procedure	
ABSSLF with cystocele repair exclusive	12 (24)
Concomitant surgery	38 (76)
Rectocele repair	31 (62)
Hysterectomy	10 (20)
Midurethral sling for stress incontinence	2 (4)
Surgery time, min	
ABSSLF with cystocele repair exclusive	70 [16]
Concomittent surgery included	126 [20]
ABSSLF feasibility	50 (100)
ABSSLF procedure	
Anatomical suspension	
Hysteropexy	37 (74)
Uterosacral ligament fixation	13 (26)
Suture technique	
PP sutures	28 (60)
PP sutures + tape	19 (40)
ND	3
Early morbidities (< 15 days)	
Overall	20 (40)
Clavien-Dindo classification	
I	2 (4)
II	17 (34)
IIIb	1 (2)
IV	0
V	0
IUGA classification	
4BeT1S5	16 (32)
4CeT1S5	1 (2)
6BeT1S4	1 (2)
4BeT2S5	8 (16)
2BT2S1	1 (2)
Category	
Ureteral stenosis	1 (2)
Urinary tract infection	7 (14)
Urinary retention	8 (16)
Self-catheterization	14 (28)
Self-catheterization > 10 days	5 (10)
Scar disunion	1 (2)
Hematoma	0
Acute neurological pain	0
New hospitalization	0
New reintervention	1 (2)

Table 2 (continued)

	Median [IQR] or n (%)
Late morbidities (15 days to 10 months)	
Overall	4 (8)
IUGA classification	
4BaT3S5	1 (2)
6BbT3S4	1 (2)
6BeT3S5	1 (2)
2AaT4S1	1 (2)
Category	
Chronic pelvic pain	2 (4)
Vaginal tape exposition	2 (4)

IQR interquartile range, *ABSSLF* anterior bilateral sacrospinous ligament fixation, *ND* non-data

and relatively safe technique for treating anterior and apical pelvic prolapse.

Both the clinical and functional results were satisfactory, but the efficacy and longer-term recurrence remain to be demonstrated. The technique was feasible in 100% of our study cohort, which is consistent with previous studies showing that intraoperative morbidity is rare with no bowel or bladder accidents or severe bleeding that would have forced the surgeon to interrupt the procedure [13, 16, 24].

The operative durations were variable, and this mainly depended on the additional procedures concomitantly performed. Our average operative duration is comparable to the operative duration reported by Wu et al. [25] of 92 min given that the bilateral approach and rate of additional surgeries performed were similar to ours. However, Shkarupa [24] and Petruzzelli [16] and their associates reported shorter average surgical times of 26 and 41 min, respectively, but they performed a unilateral approach with no concomitant additional procedures undertaken by the former team. According to Plair et al. [9], an anterior sacrospinal hysteropexy has similar short-term efficacy to hysterectomy with an apical repair but with a shorter operative time and a tendency to fewer serious complications. This view supports the current trend to spare the uterus if there is no other reason to remove it.

The most frequent morbidities encountered in our study were urinary tract infection or difficulty in resuming voiding while the most serious was related to ureteric kinking. These findings concur with other reports where Solomon et al. [13] reported difficulty to void with catheter at discharge in about 37% of their patients, and Plair et al. [9] reported one case of ureteral kinking and another of urethral injury. Bastawros and co-workers tested giving nitrofurantoin prophylactically in women with urinary retention after pelvic reconstructive surgery in an attempt to prevent postoperative urinary tract

Table 3 Comparative anatomical results before surgery and at follow-up (median follow-up time = 10 months)

	Before surgery	After surgery	Pre- to postoperative median difference and 95% [CI]	<i>p</i> value
POP Q points (centimeters)				
Ba				
Min	−2.5	−3		<0.001
Med [IQR]	2 [3.5]	−2 [1.5]	3.5 [2.7–4.5]	
Max	6	1		
C				
Min	−7	−8		<0.001
Med [IQR]	1 [3]	−6 [2]	7 [5.5–8]	
Max	8	−2		
Bp				
Min	−3	−3		<0.001
Med [IQR]	−1 [−1.75]	−3 [0.5]	1.5 [0.75–2.25]	
Max	1	2		
POP Q stage (<i>n</i> (%))				
Global				
0	0	12 (26)	-	<0.001
I	1 (2)	15 (33)	-	<0.001
II	13 (26)	18 (39)	-	0.17
III	27 (54)	1 (2)	-	<0.001
IV	9 (18)	0	-	0.003
ND	0	4	-	-
Anterior domain				
0	0	14 (30)	-	<0.001
I	2 (4)	15 (33)	-	<0.001
II	18 (36)	17 (37)	-	0.9
III	26 (52)	0	-	<0.001
IV	4 (8)	0	-	0.05
ND	0	4	-	-
Apical domain				
0	5 (10)	43 (94)	-	<0.001
I	5 (10)	3 (6)	-	0.5
II	15 (30)	0	-	<0.001
III	19 (38)	0	-	<0.001
IV	6 (12)	0	-	0.002
ND	0	4	-	-
Posterior domain				
0	1 (2)	31 (68)	-	<0.001
I	25 (53)	12 (26)	-	0.008
II	20 (43)	2 (4)	-	<0.001
III	1 (2)	1 (2)	-	0.99
IV	0	0	-	-
ND	3	4	-	-

Med median, *POP-Q* Pelvic Organ Prolapse Quantification, *ND* non-data

infections, but there was no reduction in the infection rate compared to the placebo group [26]. Regarding the risk of urinary retention, Chapman et al. demonstrated in a randomized placebo-controlled trial that the use of tamsulosin

was associated with reduced rates of postoperative urinary retention after female pelvic reconstructive surgery [27].

Based on the POP-Q score, there was a significant improvement in the anatomical outcomes in line with those reported by Petruzzelli who treated prolapse using a

Table 4 Functional results at follow-up

PGI-I (<i>n</i> = 40)	<i>n</i> (%)
Better (1–2)	39 (98)
Unchanged (3–4–5)	1 (2)
Worst (6–7)	0
PFDI-20 (<i>n</i> = 42)	Median [IQR]
Summary score	31 [62]
POPDI-6	4 [21]
CRADI-8	9 [19]
UDI-6	8 [25]
PFIQ-7 (<i>n</i> = 41)	Median [IQR]
Summary score	0 [24]
UIQ-7	0 [10]
CRAIQ-7	0 [6]
POPIQ-7	0 [0]
PISQ-IR (<i>n</i> = 37)	
Sexual activity status	<i>n</i> (%)
NSA	23 (46)
SA	14 (28)
Scale scores: NSA ^a	Mean ± SD
NSA-PR	90 ± 27
NSA-CS	15 ± 36
NSA-GQA	30 ± 27
NSA-CI	8 ± 21
Scale scores: SA ^b	Mean ± SD
SA-AO	55 ± 16
SA-PR	73 ± 20
SA-CS	86 ± 16
SA-GQ	57 ± 30
SA-CI	93 ± 10
SA-D	39 ± 14

IQR interquartile range, SD standard deviation

PGI-I Patient Global Impression scale Index

PFDI-20 Pelvic Floor Distress Inventory

It included three domains with lower scores associated with better quality of life (min 0—max 300)

POPDI-6 Pelvic Organ Prolapse Distress Inventory (min 0—max 100)

CRADI-8 Colorectal-Anal Distress Inventory (min 0—max 100)

UDI-6 Urinary Distress Inventory (min 0—max 100)

PFIQ-7 Pelvic Floor Impact Questionnaire

It included three domains with lower scores associated with better quality of life (min 0—max 300)

UIQ-7 Urinary Impact Questionnaire

CRAIQ-7 Colorectal-Anal Impact Questionnaire

POPIQ-7 Pelvic Organ Prolapse Impact Questionnaire

PISQ-IR Pelvic Organ Prolapse/Urinary Incontinence Sexual Questionnaire

NSA not sexually active

SA sexually active

^aHigher scores indicate greater impact of condition on sexual function (high score negative) (min 0—max 100)

Table 4 (continued)

^bHigher scores indicate better sexual function (high scores positive) (min 0—max 100)

NSA-PR not sexually active: partner related

NSA-CS not sexually active: condition specific

NSA-GQA not sexually active: global quality rating

NSA-CI not sexually active: condition impact

SA-AO sexually active: arousal, orgasm

SA-PR sexually active: partner related

SA-CS sexually active: condition specific

SA-GQ sexually active: global quality

SA-CI sexually active: condition impact

SA-D sexually active: desire

combined approach of sacrospinous hysteropexy and cystopexy through a single anterior incision [16]. Similarly, our study demonstrated improvement in several functional outcomes, which is consistent with the findings reported by Yalcin et al. [28]. Nevertheless, we observed a notable rate of persistent constipation after surgery (30% versus 26%, *p* = 0.5). Women should be made aware of the risk of persistence of this problem and that it might require long-term medical management.

Despite performing a routine concomitant anterior repair, the anterior compartment recurrence rate remained high, reaching 37%. However, it is important to stress that all these recurrences were limited to stage II (Ba ≤ 1) and that our results are not an outlier compared to those reported in the literature. Although our recurrence rate was high, it is lower than that reported by other studies that did not perform a prophylactic cystocele like Shkarupa et al. [24] and Jelovsek et al. [29] who reported recurrence rates of 45% at 12 months and 70% at 5 years, respectively. Shkarupa et al. performed an anterior bilateral approach while Jelovsek et al. performed unilateral or bilateral SSLF, but the approaches, anterior or posterior, were not specified. A recent meta-analysis [15] including two randomized controlled trials and four cohort studies on sacrospinous hysteropexy via a posterior approach calculated the failure rate in the anterior compartment of 35%. Moreover, our recurrence rate was better than the 90% recurrence rate at 1 year (50% stage I, 40% stage II) reported by De Castro et al. who also hoped to obtain a reduction in previous recurrences by undertaking a prophylactic cystocele cure. However, they used a posterior approach for their unilateral SSFL procedures [30]. In contrast, Solomon et al. [13] reported no recurrence rates but they only followed up their patients at 6 months. Furthermore, our study participants had preoperative prolapses of stages II to IV compared to the majority of patients in the study by Salomon et al. being stage II. Indeed, with native tissue apical vaginal surgery, the degree of preoperative

prolapse is an important predictor of anatomical outcomes [31]. Interestingly, in a relatively large study of 453 patients who had unilateral SSLF, with or without a concomitant cystocele cure, and an average 5-year follow-up, anterior compartment prolapse was the most frequently encountered type of recurrence at a rate of about 12.6%, and a statistical regression analysis showed that anterior colporrhaphy was not a significant risk factor contributing to this recurrence [25].

The anterior and bilateral approach is attractive because it allows for a concomitant anterior repair and is suggested to reduce the risk of anterior compartment recurrence rate by more uniform distribution of the tensile forces and thus respecting the anatomical axis. Hence, some authors suggest that, pending further randomized clinical trials, an anterior repair should be considered for women with higher-stage prolapse undergoing an SSLF [31]. Nevertheless, we have not shown this benefit in our preliminary study.

Apart from the additional data this study adds to the literature regarding ABSSLF and a concomitant native anterior repair, our study has the main strength that experienced urogynecological surgeons carried out all the procedures. Furthermore, we assessed a comprehensive set of outcomes that included both clinical and patient-reported outcomes. Our anatomical outcomes were assessed independently, and all our patient-reported outcomes were evaluated using validated measures. However, we appreciate that the retrospective nature and short-term follow-up are limitations to our work. We also recognize that our sample size is relatively small; this was mainly secondary to the recurrent COVID-19 restrictions imposed on elective procedures during the studied period. Moreover, there is a degree of heterogeneity in the surgical techniques used among our surgeons, at least initially, where some used a cervical tape. At present, we only use sutures because of the potential risk and the lack of evidence demonstrating the superiority of the tape.

Conclusion

Anterior bilateral sacrospinous ligament fixation using the vaginal non-mesh approach combined with a routine anterior native tissue repair is a feasible and relatively safe technique for treating anterior and apical pelvic prolapse with satisfactory anatomical and functional results at the short term. However, anterior compartment failure rates are still a limitation. Assessing the long-term anatomical and functional outcomes of this technique compared to other available surgical options is needed before drawing final conclusions.

Acknowledgments The authors thank the staff in our unit who helped to obtain patients' medical files. The authors also thank F. Wang for the help with statistical analysis and Superviseme Ltd. medical writing

services (<http://www.superviseme.eu>) for the help with the medical writing and editing of the manuscript.

Author contributions C. Delacroix: Data collection, data management and manuscript writing.

L. Allegre: Protocol development, data analysis and manuscript writing.

K. Chatziioannidou: Data collection and data analysis.

A. Gérard: Data management, data analysis.

B. Faton: Data analysis, data interpretation.

R. De Tayrac: Principal investigator during this work, project development, data analysis, data interpretation and manuscript writing.

All authors reviewed and/or edited the manuscript prior to submission.

Declarations

Conflict of interest Prof. De Tayrac and Dr. Faton are consultants for Boston Scientific; remaining authors claim no conflict of interest.

References

1. Maher C, Feiner B, Baessler K, Christmann-Schmid C, Haya N, Brown J. Surgery for women with anterior compartment prolapse. *Cochrane Database Syst Rev*. 2016;11:CD004014.
2. Wu JM, Hundley AF, Fulton RG, Myers ER. Forecasting the prevalence of pelvic floor disorders in US women: 2010 to 2050. *Obstet Gynecol*. 2009;114(6):1278–83.
3. Lua LL, Vicente ED, Pathak P, Lybbert D, Dandolu V. Comparative analysis of overall cost and rate of healthcare utilization among apical prolapse procedures. *Int Urogynecol J*. 2017;28(10):1481–8.
4. FDA Public Health Notification (Medical Devices): Urogynecologic Surgical Mesh Implants. 2019. <http://www.fda.gov/medical-devices/implants-and-prosthetics/urogynecologic-surgical-mesh-implants>. Accessed 17 June 2019.
5. Ouzaid I, Ben Rhouma S, de Tayrac R, Costa P, Prudhomme M, Delmas V. Sacrospinofixation mini-invasive avec le dispositif CAPIO : étude anatomique [Mini-invasive posterior sacrospinous ligament fixation using the CAPIO needle driver: an anatomical study]. *Prog Urol*. 2010;20(7):515–9. French.
6. Richter K. Die chirurgische Anatomie der Vaginaefixatio sacrospinalis vaginalis. Ein Beitrag zur operativen Behandlung des Scheidenblindsackprolapses [The surgical anatomy of the vaginaefixatio sacrospinalis vaginalis. A contribution to the surgical treatment of vaginal blind pouch prolapse]. *Geburtshilfe Frauenheilkd*. 1968;28(4):321–7. German.
7. Winkler HA, Tomesko JE, Sand PK. Anterior sacrospinous vaginal vault suspension for prolapse. *Obstet Gynecol*. 2000;95(4):612–5.
8. Meyer I, Whitworth RE, Lukacz ES, Smith AL, Sung VW, Visco AG, Ackenbom MF, Wai CY, Mazloomdoost D, Gantz MG, Richter HE; NICHHD. Pelvic Floor Disorders Network and the National Institutes of Health Office of Research on Women's Health. Outcomes of native tissue transvaginal apical approaches in women with advanced pelvic organ prolapse and stress urinary incontinence. *Int Urogynecol J*. 2020;31(10):2155–2164.
9. Plair A, Dutta R, Overholt TL, Matthews C. Short-term outcomes of sacrospinous hysteropexy through an anterior approach. *Int Urogynecol J*. 2021;32(6):1555–1563.
10. Goldberg RP, Tomesko JE, Winkler HA, Koduri S, Culligan PJ, Sand PK. Anterior or posterior sacrospinous vaginal vault

- suspension: long-term anatomic and functional evaluation. *Obstet Gynecol.* 2002;99(2):344.
11. Bowen ST, M.P., Abramowitch SD, Lockhart M, Weidner AC, Ferrando CA, Richter HE, Rardin CR, Komesu YM, Harvie HS, Nager CW, Mazloomdoost D, Sridhar A, Gantz MG. Vaginal angulation after vaginal hysterectomy with uterosacral ligament suspension or vaginal mesh hysteropexy: Investigating the role of vaginal configuration in anatomic failure of apical prolapse repair. In: AUGS PFD Conference 2020. 2020, Female Pelvic Medicine & Reconstructive Surgery: Virtual. p. S4–5.
 12. David-Montefiore E, Barranger E, Dubernard G, Nizard V, Antoine JM, Darai E. Functional results and quality-of-life after bilateral sacrospinous ligament fixation for genital prolapse. *Eur J Obstet Gynecol Reprod Biol.* 2007;132(2):209–13.
 13. Solomon ER, St Marie P, Jones KA, Harmanli O. Anterior bilateral sacrospinous ligament fixation: a safe route for apical repair. *Female Pelvic Med Reconstr Surg.* 2020;26(8):e33–6.
 14. Cespedes RD. Anterior approach bilateral sacrospinous ligament fixation for vaginal vault prolapse. *Urology.* 2000;56(6 Suppl 1):70–5.
 15. Kapoor S, Sivanesan K, Robertson JA, Veerasingham M, Kapoor V. Sacrospinous hysteropexy: review and meta-analysis of outcomes. *Int Urogynecol J.* 2017;28(9):1285–94.
 16. Petruzzelli P, Chiadò Fiorio Tin M, Cosma S, Parisi S, Garofalo A, Todros T. Combined sacrospinous hysteropexy and cystopexy using a single anterior incision. *Int J Gynaecol Obstet.* 2016;135(1):101–6.
 17. Dindo D, Demartines N, Clavien PA. Classification of surgical complications: a new proposal with evaluation in a cohort of 6336 patients and results of a survey. *Ann Surg.* 2004;240(2):205–13.
 18. IUGA ICS Joint Terminology and Classification of the Complications Related to Native Tissue Female Pelvic Floor Surgery. Bernard T, Haylen, Robert M Freeman, Joseph Lee, Steven E. Swift, Michel Cosson, G Willy Davila, Jan Deprest, Peter L. Dwyer, Brigitte Fatton, Ervin Kocjancic, Chris Maher, Diaa E. Rizk, Eckhard Petri, Peter K. Sand, Gabriel N. Schaer, Ralph Webb, Terminology and Standardization Committee (IUGA), Standardization Steering Committee (ICS), Joint IUGA/ICS Working Group on Complications Terminology. Joint publication in NAU & IUJ April 2012.
 19. Persu C, Chapple CR, Cauni V, Gutue S, Geavlete P. Pelvic Organ Prolapse Quantification System (POP-Q) - a new era in pelvic prolapse staging. *J Med Life.* 2011;4(1):75–81.
 20. Rockwood TH, Constantine ML, Adegoke O, Rogers RG, McDermott E, Davila GW, Domoney C, Jha S, Kammerer-Doak D, Lukacz ES, Parekh M, Pauls R, Pitkin J, Reid F, Ridgeway B, Thakar R, Sand PK, Sutherland SE, Espuna-Pons M. The PISQ-IR: considerations in scale scoring and development. *Int Urogynecol J.* 2013;24(7):1105–22.
 21. De Tayrac R, Deval B, Fernandez H, Marès P; Mapi Research Institute. Validation linguistique en français des versions courtes des questionnaires de symptômes (PFDI-20) et de qualité de vie (PFIQ-7) chez les patientes présentant un trouble de la statique pelvienne [Development of a linguistically validated French version of two short-form, condition-specific quality of life questionnaires for women with pelvic floor disorders (PFDI-20 and PFIQ-7)]. *J Gynecol Obstet Biol Reprod (Paris).* 2007;36(8):738–48. French.
 22. Srikrishna S, Robinson D, Cardozo L. Validation of the Patient Global Impression of Improvement (PGI-I) for urogenital prolapse. *Int Urogynecol J.* 2010;21(5):523–8.
 23. XLSTAT (Version 2021.2.2 Copyright Addinsoft) Statistical Software for Excel. Access dates July–August 2021 <https://www.xlstat.com>
 24. Shkarupa D, Kubin N, Shapovalova E, Zaytseva A. The resurrection of sacrospinous fixation: unilateral apical sling hysteropexy. *Int Urogynecol J.* 2020;31(2):351–7.
 25. Wu CJ, Chang WC, Huang KJ, Hsieh YC, Wei LH, Sheu BC. Long-term follow-up of 453 patients with pelvic organ prolapse who underwent transvaginal sacrospinous colpopexy with Veronikis ligature carrier. *Sci Rep.* 2020;10(1):4997.
 26. Bastawros D, Kaczmarek K, Zhao J, Bender R, Myers E, Tarr ME. Twice-daily nitrofurantoin administration following short-term transurethral catheterization after pelvic reconstructive surgery: a randomized clinical trial. *Female Pelvic Med Reconstr Surg.* 2021;27(3):202–7.
 27. Chapman GC, Sheyn D, Slopnick EA, Roberts K, El-Nashar SA, Henderson JW, Mangel J, Hijaz AK, Pollard RR, Mahajan ST. Tamsulosin vs placebo to prevent postoperative urinary retention following female pelvic reconstructive surgery: a multicenter randomized controlled trial. *Am J Obstet Gynecol.* 2021:S0002–9378(21)00466–X.
 28. Yalcin Y, Demir Caltekin M, Eris YS. Quality of life and sexuality after bilateral sacrospinous fixation with vaginal hysterectomy for treatment of primary pelvic organ prolapse. *Low Urin Tract Symptoms.* 2020;12(3):206–10.
 29. Jelovsek JE, Barber MD, Brubaker L, Norton P, Gantz M, Richter HE, Weidner A, Menefee S, Schaffer J, Pugh N, Meikle S; NICHD Pelvic Floor Disorders Network. Effect of Uterosacral Ligament Suspension vs Sacrospinous Ligament Fixation With or Without Perioperative Behavioral Therapy for Pelvic Organ Vaginal Prolapse on Surgical Outcomes and Prolapse Symptoms at 5 Years in the OPTIMAL Randomized Clinical Trial. *JAMA.* 2018;319(15):1554–1565.
 30. de Castro EB, Juliato CR, Piedemonte LA, dos Santos Júnior LC. Impact of sacrospinous colpopexy associated with anterior colporrhaphy for the treatment of dome prolapse on all three vaginal compartments. *Rev Bras Ginecol Obstet.* 2016;38(2):77–81.
 31. Nager CW, Grimes CL, Nolen TL, Wai CY, Brubaker L, Jeppson PC, Wilson TS, Visco AG, Barber MD, Sutkin G, Norton P, Rardin CR, Arya L, Wallace D, Meikle SF; Pelvic Floor Disorders Network. Concomitant Anterior Repair, Preoperative Prolapse Severity, and Anatomic Prolapse Outcomes After Vaginal Apical Procedures. *Female Pelvic Med Reconstr Surg.* 2019;25(1):22–28.

Publisher's note Springer Nature remains neutral with regard to jurisdictional claims in published maps and institutional affiliations.