



Physician preferences in diagnostics and treatment of juvenile osteochondritis dissecans are diverse across the knee, ankle and elbow: an ESSKA survey

Laura A. M. Kemmeren¹ · Christiaan J. A. van Bergen^{1,2} · Max Reijman¹ · Tom M. Piscaer¹

Received: 9 June 2023 / Accepted: 30 August 2023 / Published online: 3 October 2023
© The Author(s) 2023

Abstract

Purpose To investigate the current preferences regarding the work-up and treatment choices of juvenile osteochondritis dissecans (JOCD) of the knee, ankle and elbow among orthopaedic surgeons.

Methods An international survey was set up for all European Society of Sports Traumatology, Knee Surgery and Arthroscopy (ESSKA) members, which assessed various questions on diagnosis and treatment of JOCD of different joints. Respondents answered questions for one or more joints, based on their expertise. Proportions of answers were calculated and compared between joints. Consensus was defined as more than 75% agreement on an item; disagreement was defined as less than 25% agreement.

Results Fifty physicians responded to the survey, of whom forty-two filled out the questions on the knee, fourteen on the ankle and nine on the elbow. Plain radiography and MRI were the most used imaging modalities for the assessment and follow-up of JOCD in the knee and ankle, but not for the elbow. MRI was also the preferred method to assess the stability of a lesion in the knee and ankle. There was universal agreement on activity and/or sports restriction as the non-operative treatment of choice for JOCD. Size, stability and physal closure were the most important prognostic factors in determining the operative technique for the elbow. For the knee, these factors were size and stability and for the ankle, these were size and location.

Conclusion Activity and/or sports restriction was the non-operative treatment of choice. Furthermore, plain radiography and MRI were the preferred imaging modalities for the knee and ankle, but not for the elbow. For determining the operative technique, physicians agreed that the size of the lesion is an important prognostic factor in all joints. These findings help us understand how juvenile osteochondritis dissecans is treated in current practice and may provide opportunities for improvement.

Level of evidence Level V.

Keywords Osteochondritis dissecans · Juvenile osteochondritis dissecans · Osteochondral defect · Elbow · Knee · Ankle · Adolescent · Paediatric · Cartilage · Survey · ESSKA · Arthroscopy · Drilling

Abbreviations

ESSKA European Society of Sports Traumatology, Knee Surgery and Arthroscopy
JOCD Juvenile osteochondritis dissecans
NSAID Non-steroidal anti-inflammatory drug

OCD Osteochondritis dissecans
PROM Patient-reported outcome measure
PRP Platelet-rich plasma

Introduction

Osteochondritis dissecans (OCD) is a disorder of the articular cartilage and subchondral bone that is frequently seen in children participating in sports [5, 18]. Juvenile osteochondritis dissecans (JOCD) occurs in skeletally immature children, i.e. children with open physes. The disorder may occur in different joints, the most common being the knee, ankle and elbow, respectively [21]. Irrespective of the location,

✉ Laura A. M. Kemmeren
l.kemmeren@erasmusmc.nl

¹ Department of Orthopaedic Surgery and Sports Medicine, Erasmus Medical Centre, Sophia Children's Hospital, Dr. Molewaterplein 40, 3015GD Rotterdam, The Netherlands

² Department of Orthopaedic Surgery, Amphia Hospital, Breda, The Netherlands

JOCD may cause pain and mechanical symptoms in the affected joint, which could limit the mobility and athletic activities of the patient [3].

JOCD is a relatively rare condition, but it can greatly impact a child's life [24]. So far, almost no randomised controlled trials have been performed and relatively little research has been conducted around the treatment of this condition. The aetiology of JOCD is not entirely clear [24]. This might be another reason this condition has no clear optimal treatment, resulting in a lack of standard treatment protocols. Additionally, there have only been a few consensus meetings [4].

JOCD in children appears to have better healing potential than OCD in adults [11, 14, 30]. Probably because of this, treatment choices differ between children and adults. Although certain features, such as lesion size and stability, must be considered for each JOCD, different joints may also require different treatments [21]. On the other hand, treatment principles between joints may have much in common.

An orthopaedic landscape gradually changing from general orthopaedic surgeons to joint specialists potentially causes us to work on 'islands', which may create knowledge segregation. Instead, we could learn from each other in this situation, as this same pathology affects different joints. Therefore, an international survey was developed to investigate current practices and preferences on the diagnosis and treatment of JOCD of the knee, ankle and elbow among orthopaedic surgeons.

Materials and methods

An online survey was developed using Microsoft Forms. This survey included questions regarding symptoms, physical examination, imaging, non-operative and operative treatment and follow-up of JOCD. Similar questions were created for the knee, ankle and elbow. The respondents could answer the questions for all the joints for which they treated JOCD. There were 5 general questions and 21 questions per joint, including 2 cases per joint. Before they could submit the survey, all questions had to be answered for the joints physicians stated to treat. The survey is provided in the supplementary material.

Reach

The survey was placed on the website of the European Society of Sports Traumatology, Knee Surgery and Arthroscopy (ESSKA). It was also available through the web link, which was provided at the ESSKA congress in Paris in 2022. The web link was also distributed through social media platform LinkedIn.

Survey

General questions

The general questions included nationality, current profession, the number of years in practice and the approximate number of annual JOCD cases. Respondents were also asked to provide their definitions of JOCD.

Diagnosis

Respondents were asked how many JOCD lesions they annually treat per joint. Furthermore, respondents had to name differentiating symptoms and findings in the physical examination, which they thought were suggestive of JOCD. The use of imaging modalities, timing of imaging and imaging of the contralateral joint was also assessed. Furthermore, respondents were asked whether they determined skeletal age or requested genetic testing for JOCD.

Treatment

Physicians were asked what their preferred non-operative treatment plan was for JOCD and after what time or in what stage they would move on to operative treatment if symptoms were not alleviated. Respondents were also asked which types of operative treatment they used, which prognostic factors were most important in deciding what operative technique to use and which type of treatment they would use in two different cases (see supplementary material).

Follow-up

Physicians were also asked for what period of time they followed up on their patients, what imaging modalities they used for monitoring recovery and whether they recorded any patient-reported outcome measures (PROMs).

Analysis

Absolute numbers and percentages are given for each question. Consensus was set at 75% agreement [27]. Likewise, disagreement on a statement was set at less than 25% of respondents opting for that item. Analysis was done using Microsoft Excel.

Results

General questions

Fifty physicians filled out the survey. Their answers to the general questions are given in Table 1.

Knee

Forty-two physicians reported treating JOCD lesions of the knee (84%). Consensus was reached that during the patient interview, joint effusion and pain during activities are the most characteristic findings for JOCD (Table 2). For the physical examination, consensus was only obtained for joint effusion (88%).

Plain radiography (40 physicians, 95%) and MRI (42 physicians, 100%) are almost always used in the diagnostic work-up of JOCD in the knee (Fig. 1). CT is used by 8 physicians (17%). The physicians who chose to acquire plain radiography, agreed to request an AP and a lateral view. When complaints are unilateral, physicians were divided

on whether to request imaging for one knee (22 physicians, 52%) or both knees (20 physicians, 48%). 16 respondents (38%) use a classification system. Examples of classifications that were used included the Clanton and DeLee classification, DiPaola classification, Hefti classification and Nelson classification.

To determine whether a JOCD lesion is stable, respondents almost unanimously use MRI (41 physicians, 98%). Plain radiography (8 physicians, 19%), physical examination (6 physicians, 14%) and CT (3 physicians, 7%) are discouraged for this purpose. Most physicians use imaging of the knee that is already present (27 physicians, 64%) to determine skeletal age, although no method reached consensus.

Activity and/or sports restriction is the non-operative treatment of choice (41 physicians, 98%). The use of non-steroidal anti-inflammatory drugs (NSAIDs), injection therapy through corticosteroids and immobilisation on their own reached consensus not to be used.

Different surgical techniques, including internal fixation with bioabsorbable and non-absorbable devices, antegrade and retrograde drilling, debridement, microfracturing, loose body removal and osteochondral autograft transfer are used. In addition, 8 physicians (20%) mentioned using biologicals, such as platelet-rich plasma (PRP, 6 physicians, 15%) and bone marrow aspirate concentrate (2 physicians, 5%) in the treatment of JOCD.

Consensus was reached that stability (36 physicians, 86%) and size (33 physicians, 79%) of the lesion are the most important prognostic factors in determining the operative technique. Being a high-performing athlete does not influence the operative technique according to respondents. During follow-up after operative treatment, respondents agreed that MRI is the best imaging technique (32 physicians, 76%), although plain radiography was also chosen by 29 physicians (69%). CT was infrequently used (2 physicians, 5%). Most physicians do not record any PROMs. PROMs that were mentioned to be collected were the IKDC score, the Tegner score, the Pedi-IKDC, the KOOS score and the Pedi-FABS score.

Ankle

Fourteen respondents treated JOCD lesions of the ankle (28%). It was agreed that joint effusion and pain during activities are the most suggestive of OCD in a patient interview. Consensus or disagreement was not reached for the physical examination for any item. Respondents agreed that plain radiography and MRI are the most useful imaging modality. CT was used by 7 respondents (50%).

There was no consensus on whether to perform imaging of one or both ankles when complaints are unilateral. Physicians agreed not to use a classification system for OCD of the ankle. Systems that were mentioned to be used are

Table 1 Respondent characteristics^a

	N=50
Profession	
Orthopaedic surgeon	41 (82)
Orthopaedic surgeon in training	9 (18)
Years of experience since residency	
0–5	6 (12)
5–10	9 (18)
10–15	9 (18)
15–20	10 (20)
20+	8 (16)
Country of practice	
The Netherlands	21 (42)
Greece	4 (8)
Portugal	3 (6)
Germany	2 (4)
Spain	2 (4)
Other	11 (22)
Did not specify	7 (14)
Cases treated annually	
1–10	27 (54)
10–20	18 (36)
20+	5 (10)
Key factor in definition of JOCD	
Skeletal maturity	23 (46)
Age	2 (4)
Both	26 (52)

^aNumbers are given as absolute number (percentage)

Table 2 Outcomes of the survey per joint^{a, b}

Joint	Knee (<i>n</i> =42)	Ankle (<i>n</i> =14)	Elbow (<i>n</i> =9)
Lesions treated annually			
1–5	14 (33)	6 (43)	7 (78)
5–10	11 (26)	4 (29)	1 (11)
10–20	13 (31)	2 (14)	1 (11)
20+	4 (10)	2 (14)	0 (0)
Characteristic findings during patient interview			
Pain on radial side of elbow	N/A	N/A	9 (100)
Pain on ulnar side of elbow	N/A	N/A	1 (11)
Participation in a throwing sport	N/A	N/A	5 (56)
Joint effusion	37 (88)	11 (79)	N/A
Pain during activities	33 (79)	13 (93)	2 (22)
Locking	28 (67)	8 (57)	6 (67)
Clicking	19 (45)	4 (29)	N/A
History of trauma	7 (17)	3 (21)	1 (11)
Limited range of motion	7 (17)	5 (36)	N/A
Pain at night	1 (2)	1 (7)	1 (11)
Instability	1 (2)	2 (14)	0 (0.0)
Characteristic findings during physical examination			
Joint effusion	37 (88)	9 (64)	6 (67)
Point tenderness on palpation	27 (64)	8 (57)	6 (67)
Crepitus	10 (24)	6 (43)	5 (56)
Limited range of motion	17 (40)	5 (36)	5 (56)
Positive radiocapitellar test	N/A	N/A	3 (33)
Positive Wilson's test	6 (14)	N/A	N/A
Abnormal gait pattern	10 (24)	N/A	N/A
Limited stability/ligamentous laxity	1 (2)	4 (29)	N/A
Preferred imaging modality			
Plain radiography	40 (95)	13 (93)	5 (56)
CT	8 (17)	7 (50)	5 (56)
MRI	42 (100)	12 (86)	5 (56)
Radiography views			
AP	37 (88)	12 (86)	N/A
Lateral	40 (95)	13 (93)	5 (56)
AP in extension	N/A	N/A	5 (56)
AP in 45° flexion	N/A	N/A	2 (22)
Radial head	N/A	N/A	2 (22)
Rosenberg	11 (26)	N/A	N/A
Tunnel	20 (48)	N/A	N/A
Sunrise	4 (10)	N/A	N/A
Whole leg	6 (14)	N/A	N/A
Mortise	N/A	8 (57)	N/A
Heel rise	N/A	1 (7)	N/A
Horizontal beam lateral	N/A	1 (7)	N/A
Imaging of one or both joints			
One	22 (52)	5 (36)	6 (67)
Both	20 (48)	9 (64)	3 (33)
Preferred method of determining stability ^c			
History of patient	13 (31)	4 (29)	1 (11)
Physical examination	6 (14)	2 (14)	1 (11)
Range of motion	1 (2)	3 (21)	1 (11)
Plain radiography	8 (19)	2 (14)	0 (0)

Table 2 (continued)

Joint	Knee (<i>n</i> =42)	Ankle (<i>n</i> =14)	Elbow (<i>n</i> =9)
CT	3 (7)	6 (43)	4 (44)
MRI	41 (98)	12 (86)	6 (67)
Arthroscopy	20 (48)	6 (43)	4 (44)
Preferred non-operative treatment			
Activity/sports restriction	41 (98)	14 (100)	8 (89)
Limited weight bearing	20 (48)	9 (64)	N/A
Immobilisation through casting	0 (0)	1 (7)	1 (11)
Immobilisation through bracing	6 (14)	3 (21)	0 (0)
Non-steroidal anti-inflammatory drugs	9 (21)	1 (7)	1 (11)
Injection therapy through corticosteroids	1 (2)	0 (0)	0 (0)
Injection therapy through platelet-rich plasma	3 (7)	3 (21)	1 (11)
Operative treatment arsenal			
Drilling	N/A	9 (64)	2 (22)
Internal fixation with non-absorbable devices	17 (40)	4 (29)	2 (22)
Internal fixation with bioabsorbable devices	26 (62)	7 (50)	3 (33)
Bone grafting	10 (24)	4 (29)	1 (11)
Debridement	22 (50)	10 (71)	7 (78)
Microfracturing	20 (48)	9 (64)	6 (67)
Autologous chondrocyte implantation	4 (10)	0 (0)	1 (11)
Osteochondral autograft plugs	14 (33)	3 (21)	2 (22)
Osteochondral allograft	3 (7)	2 (14)	0 (0)
Loose body removal	23 (55)	8 (57)	7 (78)
Antegrade drilling	20 (48)	N/A	N/A
Retrograde drilling	21 (50)	N/A	4 (44)
Transarticular drilling	3 (7)	N/A	N/A
Use of biologicals ^d			
No	36 (86)	10 (71)	8 (89)
Yes, platelet-rich plasma	6 (14)	3 (21)	1 (11)
Yes, bone marrow aspirate concentrate	2 (5)	2 (14)	0 (0)
Most prognostic factor for determining operative technique			
Size of lesion	33 (79)	13 (93)	8 (89)
Stability of lesion	36 (86)	8 (57)	7 (78)
Location of lesion	17 (40)	11 (79)	2 (22)
Lesion of cartilage only vs osteochondral lesion	17 (40)	4 (29)	2 (22)
Physcal closure	16 (38)	6 (43)	8 (89)
High-performing athlete	4 (10)	1 (7)	0 (0)
Imaging modality during follow-up after operative treatment			
Plain radiography	29 (69)	8 (57)	5 (56)
CT	2 (5)	5 (36)	2 (22)
MRI	34 (81)	11 (79)	5 (56)
None/only when indicated	2 (5)	2 (14)	2 (22)

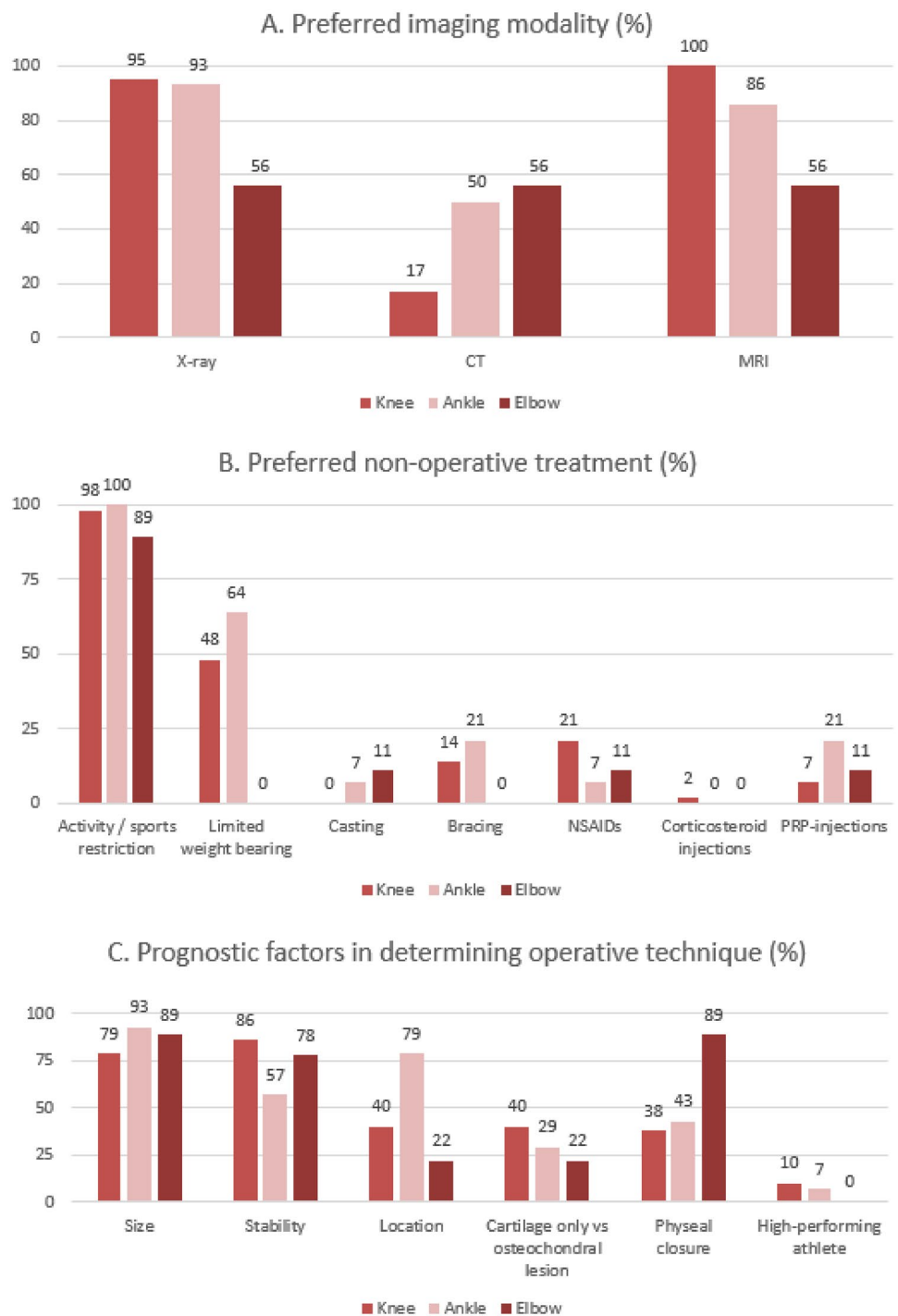
^aNumbers are given as absolute number (percentage). When the total percentage exceeds 100%, multiple answers could be given to a question

^bFor all items in bold, consensus was reached that these are the most suitable options. For all items in italics, this option was considered to have reached disagreement. Some items exceeding 75% or below 25% were not marked, as the nature of the question does not aim for a consensus to be reached on this topic

^cFor this question, the option 'Other' was given. For the elbow, two respondents answered skeletal maturity and whether the physis was closed. The 'Other' option was not chosen for the knee or ankle

^dFor this question, answers exceeding 75% or below 25% were not marked to have reached consensus, as this technique is fairly new, which is probably the reason not many respondents used it yet and would not recommend or disregard it

Fig. 1 Survey results given in histograms. Numbers given above columns represent percentages of physicians that chose that option



the Berndt and Harty classification, the Hefti classification and the Ferkel and Sgaglione classification. Consensus was reached that MRI is the way to determine whether a lesion is stable (12 physicians, 86%). Respondents agreed that determining this through plain radiography or physical examination alone is not appropriate. 13 physicians (93%) did not use any genetic testing.

Regarding non-operative treatment for JOCD of the ankle, respondents unanimously use activity and/or sports restriction. Respondents agreed that any form of immobilisation, injection therapy or the use of NSAIDs on their own are not an appropriate treatment. Many different operative techniques are used to treat JOCD of the ankle, of which debridement, microfracturing, drilling and loose

body removal were mentioned the most. In addition, 3 physicians (21%) use PRP and 2 (14%) use bone marrow aspirate concentrate in their treatment. It was agreed that the most important prognostic factors in determining the operative technique are size and location of the lesion and that the level of the athlete did not influence the operative technique.

MRI was the preferred imaging modality for follow-up after operative treatment. Not using any imaging as follow-up was discouraged by respondents. No consensus was reached on how long to follow up on a patient after treatment. 10 respondents did not use any PROMs (71%), outcome measures that were recorded were the FAOS, AOFAS and FAAM score.

Elbow

Out of fifty respondents, nine answered that they treat JOCD lesions of the elbow (18%). Pain on the radial side of the elbow was unanimously the most characteristic finding in the patient interview. Findings that were agreed on not being indicative of JOCD of the elbow are a history of trauma, instability, pain at night, pain on the ulnar side of the elbow and pain only during activities.

No consensus was reached on characteristic findings during physical examination or the use of an imaging modality in the diagnostic process. There was no consensus on whether to perform imaging of one or both elbows when complaints are unilateral. 6 respondents do not use a classification system (67%), the ones that do use the Minami classification. There was no consensus on a method to determine the stability of the lesion, although most (6 physicians, 67%) use MRI. To assess skeletal age, 6 physicians (67%) use the imaging already present, but no consensus was reached. 8 physicians do not use genetic testing (89%), 1 (11%) uses a SMAD3 mutation test in specific cases.

Agreement was reached that activity and/or sports restriction is the preferred non-operative treatment (8 physicians, 89%). Any other method of non-operative treatment is not recommended by the respondents. Operative treatment options that were used the most are debridement, loose body removal and microfracturing. It was agreed that the size of the lesion, aspect of the physes and stability of the lesion are the most important prognostic factors in determining the operative technique. Location of the lesion, whether the lesion is osteochondral or chondral only and being a high-performing athlete are not deemed to be of prognostic value. There was no consensus on the best imaging technique during follow-up. 6 physicians do not use any PROMs (67%), the ones that do use the Oxford Elbow score (3 physicians, 33%) and the Mayo Elbow Performance score (1 physician, 11%).

Discussion

The most important finding of this study is that physician preferences are diverse across joints. This shows that JOCD has many entities and treatment options. It also shows that there is a lack of consensus between orthopaedic surgeons when it comes to the optimal diagnostic and treatment process. Nevertheless, similarities and agreements can definitely be found. Physicians agreed that the preferred non-operative method for JOCD is activity and/or sports restriction. Furthermore, plain radiography and MRI are the preferred imaging modalities for the knee and ankle, but not the elbow, for which no consensus was reached on any imaging modality. For determining the operative technique, physicians agreed that size of the lesion is an important prognostic factor in all joints.

To our knowledge, a study that explores the diagnosis and treatment preferences for juvenile osteochondritis dissecans for the elbow, knee or ankle has not been performed before. There are multiple guidelines and reviews on the optimal treatment of osteochondritis dissecans, but how these are implemented in everyday practice has not been investigated before. Guidelines on treating juvenile osteochondritis dissecans are scarcer than those of adult OCD, so gathering expert opinion on this form of OCD is even more valuable.

Forty-two out of fifty respondents treated JOCD of the knee, which was the part of the survey that was filled out most often. This supports the literature that the knee joint is most affected [5, 21].

Joint effusion and pain during activities were considered to be the most characteristic findings during the patient interview for the knee and ankle. Interestingly, this was not the case for the elbow. Only pain on the radial side of the elbow was considered to be a characteristic finding for this joint, which is also the only suggestive finding for JOCD of the elbow in the beginning stages in the literature [9, 23]. It is interesting to see that these symptoms are all non-specific. It was agreed that a history of trauma, pain at night and instability complaints were not typical for JOCD in any joint.

There were also some interesting findings concerning physical examination. For the knee, the Wilson's test is a test that if positive, might indicate the presence of OCD [31]. However, only 14% of physicians thought this test to be characteristic of OCD, supporting previous research that the Wilson's test, although specifically designed for OCD, is of little diagnostic value [7]. Therefore, we recommend not to perform this test. A test that might indicate the presence of OCD in the elbow is the radiocapitellar test. However, its sensitivity and specificity are not well known [10]. Only 33% of physicians in this survey thought this test to be indicative of OCD, which suggests that the clinical value of this test is also low. We also recommend not to perform this test.

Plain radiography and MRI were considered the preferred imaging modalities for the knee and ankle. Consensus was reached that CT is not the best imaging technique for diagnosing JOCD of the knee.

For the elbow, however, no consensus was reached for any imaging modality. Half or more of the physicians in the elbow and ankle group also routinely use CT. Previous research has shown that MRI is the imaging modality of choice over CT for OCD of the knee [15, 17, 20]. For the elbow, however, there is little research to prefer one over the other, although multiple studies have suggested that CT is more sensitive in detecting OCDs of the elbow [26]. For the ankle, despite there being a preference for MRI over CT in this survey, there is no convincing evidence in literature that prefers MRI over CT or vice versa, as both techniques have advantages and disadvantages and have a similar sensitivity and specificity in diagnosing JOCD [25, 27, 29].

Plain radiography is recommended as a screening instrument for JOCD of the knee, ankle and elbow. For the knee, if JOCD is still suspected after a normal radiograph, we recommend performing an MRI scan. For the elbow and ankle, evidence for CT or MRI is not as conclusive, as they both have advantages and disadvantages. We also recommend using MRI for pre-operative planning and post-operative follow-up for the knee. Again, evidence for the elbow and ankle is not as conclusive for pre-operative planning and post-operative follow-up.

Activity and/or sports restriction was the preferred non-operative treatment in all joints. These measures on their own tend to be a relatively successful treatment for JOCD in the beginning stages [13, 22]. All other treatment options, except for limited weight bearing, reached disagreement, meaning that on their own, these treatments are discouraged. This concurs with the literature, which shows that non-operative measures other than activity and/or sports restriction, such as immobilisation and injection therapy, are of little therapeutic value [1, 19]. Therefore, we recommend that activity and/or sports restriction should be the only non-operative treatment for JOCD, unless additional factors indicate different treatment.

Across the different joints, agreement was reached that size of the lesion is an important prognostic factor in determining the operative technique. Additionally, stability was deemed an important prognostic factor for the elbow and knee. Size, stability and location of the lesion have proved to be important prognostic factors for treatment of OCD of the knee in previous research [2, 16]. Another important prognostic factor for the elbow was physeal closure, which was not the case for the knee or ankle. Finally, it was agreed that being a high-performing athlete does not influence the operative technique for any joint.

Studies have shown that a capitellar OCD in a patient with closed physes has worse outcomes than those with open

physes. This trend has also been described for OCDs of the knee and ankle, but did not come forward as much in this survey [5, 8, 13]. Location of the lesion was deemed to be an important prognostic factor in the ankle, although its prognostic value remains unclear in literature [6, 12, 28].

Despite spreading this survey through numerous media, this study was limited by its sample size of 50 physicians. With more respondents, a more representative view of orthopaedic surgeons' preferences could have been given and hard conclusions could have been drawn. However, it still provides valuable insight into the preferences of orthopaedic surgeons when it comes to treating this relatively rare condition. Another limitation is that because of the many different treatment options that are used and the many different severities JOCD can present itself in, it is hard to distinguish which method is best in which situation. We tried to tackle this problem using cases, but answers were still very diverse and challenging to compare between joints (see supplementary material).

In conclusion, this survey was conducted to assess physicians' current diagnosis and treatment preferences in different countries for juvenile osteochondritis dissecans of the knee, ankle and elbow. Results were diverse across joints, but generally aligned with current knowledge. These findings help us to understand how research on juvenile osteochondritis dissecans is applied in current practice. The information that was gained through this survey can be used towards future studies on developing a diagnostic and treatment algorithm for JOCD of the elbow, knee and ankle.

Conclusion

Activity and/or sports restriction was the non-operative treatment of choice. Furthermore, plain radiography and MRI were the preferred imaging modalities for the knee and ankle, but not for the elbow. For determining the operative technique, physicians agreed that the size of the lesion is an important prognostic factor in all joints. These findings help us understand how juvenile osteochondritis dissecans is treated in current practice and may provide opportunities for improvement.

Supplementary Information The online version contains supplementary material available at <https://doi.org/10.1007/s00167-023-07563-0>.

Acknowledgements H. Aagaard, MD, PhD, Seeland university hospital, Denmark. E. Andriadis, MD, Private clinic, Greece. A. Apostolopoulos, MD, Red Cross hospital, Greece. T. Baltes, MD, Noordwest hospital, the Netherlands. L. Bengoa, MD, Hospital Nacional Guillermo Almenara, Peru. M. van den Borne, MD, Amphia hospital, the Netherlands. N. Bulatovic, MD, Clinica center of Montenegro, Montenegro. A. Espejo-Baena, MD, Vithas hospital Malaga, Spain. J. Espregueira-Mendes, MD, prof, Clinica Espregueira, Portugal. S. Geraets, MD, Anna hospital, the Netherlands. E. Gomez-Barrena, MD,

Hospital La Paz, Spain. M. van Haagen, MD, Bergman clinics, the Netherlands. M. Hantes, MD, PhD, prof, university hospital of Larisa, Greece. A. Joosten, MD, Amphia hospital, the Netherlands. H. Kaptijn, MD, Reinier Haga orthopedic centre, the Netherlands. R. Keijsers, MD, Amphia hospital, the Netherlands. A. Kjellsen, MD, Haukeland university hospital, Norway. B. Koc, MD, Zuyderland Medical Centre, the Netherlands. P. Maathuis, MD, PhD, University medical centre Groningen, the Netherlands. A. van der Made, MD, PhD, Amphia hospital, the Netherlands. H. Madry, MD, prof, Saarland university hospital, Germany. B. Martinkieniene, MD, Vilnius university hospital, Lithuania. D. Meuffels, MD, PhD, prof, Erasmus Medical Centre, the Netherlands. M. Mosquera, MD, Clinica la Carolina, Colombia. W. Nijhuis, MD, University medical centre Utrecht, the Netherlands. H. Pereira, Hospital da Luz, Portugal. M. Porter, MD, Canbarra Orthopaedics and Sports Medicine, Australia. N. Pujol, MD, Centre Hospitalier de Versailles, France. P. Rodrigues, MD, Hospital dona Estefania, Portugal. M. Savvidis, MD, PhD, 424 Military Hospital, Greece. M. Sietsma, MD, Martini hospital, the Netherlands. P. Spennacchio, MD, Centre hospitalier de Luxembourg, Luxembourg. K. Tecklenburg, MD, Medalp Sportclinic Imst, Austria. B. The, MD, Amphia hospital, the Netherlands. T. Tischer, MD, prof, Malteser Waldkrankenhaus, Germany. K. Urbasek, MD, University hospital Brno, Czech Republic. S. de Vos-Jakobs, MD, Erasmus Medical Centre, the Netherlands. T. Voskuijl, Reinier Haga orthopedic centre, the Netherlands. J. Wiegnerinck, MD, PhD, Bergman clinics, the Netherlands. L. Wörner, MD, Reinier de Graaf hospital, the Netherlands. P. van der Woude, MD, Albert Schweitzer hospital, the Netherlands.

Author contributions All authors have contributed significantly to the study. LK, CB and TP developed the survey questions. LK developed the survey itself. LK wrote the manuscript and all authors commented on all previous versions of the manuscript. All authors read and approved the final manuscript.

Funding No funding was received related to this study by any of the authors.

Data availability Data was supplied in the supplementary material.

Declarations

Conflict of interest The authors of this article declare that they have no conflicts of interest relevant to the content of this article.

Ethical approval N/A.

Informed consent N/A.

Social media handles LinkedIN: Laura Kemmeren, Christiaan van Bergen, Max Reijman, Tom Piscaer.

Open Access This article is licensed under a Creative Commons Attribution 4.0 International License, which permits use, sharing, adaptation, distribution and reproduction in any medium or format, as long as you give appropriate credit to the original author(s) and the source, provide a link to the Creative Commons licence, and indicate if changes were made. The images or other third party material in this article are included in the article's Creative Commons licence, unless indicated otherwise in a credit line to the material. If material is not included in the article's Creative Commons licence and your intended use is not permitted by statutory regulation or exceeds the permitted use, you will need to obtain permission directly from the copyright holder. To view a copy of this licence, visit <http://creativecommons.org/licenses/by/4.0/>.

References

- Andriolo L, Candrian C, Papio T, Cavicchioli A, Perdisa F, Filardo G (2019) Osteochondritis dissecans of the knee—conservative treatment strategies: a systematic review. *Cartilage* 10:267–277
- Anthony CE, Paul S (2018) Osteochondritis Dissecans of the knee. In: Alessandro RZ, Joao Batista de M, eds. *Cartilage Repair and Regeneration*:<https://doi.org/10.5772/intechopen.70275>. Rijeka: IntechOpen:123–141.
- Bruns J, Werner M, Habermann C (2018) Osteochondritis dissecans: etiology, pathology, and imaging with a special focus on the knee joint. *Cartilage* 9:346–362
- Chambers HG, Shea KG, Anderson AF, Brunelle TJ, Carey JL, Ganley TJ et al (2012) American academy of orthopaedic surgeons clinical practice guideline on: the diagnosis and treatment of osteochondritis dissecans. *J Bone Joint Surg Am* 94:1322–1324
- Chau MM, Klimstra MA, Wise KL, Ellermann JM, Tóth F, Carlson CS et al (2021) Osteochondritis dissecans: current understanding of epidemiology, etiology, management, and outcomes. *J Bone Joint Surg Am* 103:1132–1151
- Chuckpaiwong B, Berkson EM, Theodore GH (2008) Microfracture for osteochondral lesions of the Ankle: outcome analysis and outcome predictors of 105 cases. *Arthroscopy* 24:106–112
- Conrad JM, Stanitski CL (2003) Osteochondritis dissecans: Wilson's sign revisited. *Am J Sports Med* 31:777–778
- Dahmen J, Steman JAH, Buck TMF, Struijs PAA, Stufkens SAS, van Bergen CJA et al (2022) Treatment of osteochondral lesions of the talus in the skeletally immature population: a systematic review. *J Pediatr Orthop* 42:e852–e860
- Eyendaal D, Bain G, Pederzini L, Poehling G (2017) Osteochondritis dissecans of the elbow: state of the art. *JISAKOS* 2:47–57
- Greife RM, Saifi C, Ahmad CS (2010) Pediatric sports elbow injuries. *Clin Sports Med* 29:677–703
- Hefti F, Beguiristain J, Krauspe R, Möller-Madsen B, Riccio V, Tschauer C et al (1999) Osteochondritis dissecans: a multicenter study of the European Pediatric Orthopedic Society. *J Pediatr Orthop B* 8:231–245
- Hurley DJ, Davey MS, Hurley ET, Murawski CD, Calder JDF, D'Hooghe P, et al. (2022) Paediatric ankle cartilage lesions: Proceedings of the International Consensus Meeting on Cartilage Repair of the Ankle. *JISAKOS* 7:90–94
- Kim HW, Park KB, Kim CW, Lee KY, Park H (2022) Healing predictors of conservative treatment for juvenile osteochondritis dissecans of the Talus. *Clin J Sport Med* 32:e635–e643
- Kocher MS, Micheli LJ, Yaniv M, Zurawski D, Ames A, Adriano AA (2001) Functional and radiographic outcome of juvenile osteochondritis dissecans of the knee treated with transarticular arthroscopic drilling. *Am J Sports Med* 29:562–566
- Luhmann SJ, Schootman M, Gordon JE, Wright RW (2005) Magnetic resonance imaging of the knee in children and adolescents. Its role in clinical decision-making. *J Bone Joint Surg Am* 87:497–502
- Masquijo J, Kothari A (2019) Juvenile osteochondritis dissecans (JOCD) of the knee: current concepts review. *EFORT Open Rev* 4:201–212
- Müller SA, Müller-Lebschi JA, Shotts EE, Bond JR, Tiegs-Heiden CA, Collins MS et al (2022) Advantages of CT versus MRI for preoperative assessment of osteochondritis dissecans of the capitellum. *Am J Sports Med* 50:3941–3947
- Nissen CW, Albright JC, Anderson CN, Busch MT, Carlson C, Carsen S et al (2022) Descriptive epidemiology from the research in osteochondritis dissecans of the knee (ROCK) prospective cohort. *Am J Sports Med* 50:118–127

19. Perumal V, Wall E, Babekir N (2007) Juvenile osteochondritis dissecans of the talus. *J Pediatr Orthop* 27:821–825
20. Quatman CE, Quatman-Yates CC, Schmitt LC, Paterno MV (2012) The clinical utility and diagnostic performance of MRI for identification and classification of knee osteochondritis dissecans. *J Bone Joint Surg Am* 94:1036–1044
21. Roatan J, Guevel B, Heyworth B, Kocher M (2022) Osteochondritis dissecans lesions of the pediatric and adolescent knee. *Orthop Clin North Am* 53:445–459
22. Takahara M, Ogino T, Fukushima S, Tsuchida H, Kaneda K (1999) Nonoperative treatment of osteochondritis dissecans of the humeral capitellum. *Am J Sports Med* 27:728–732
23. Takahara M, Shundo M, Kondo M, Suzuki K, Nambu T, Ogino T (1998) Early detection of osteochondritis dissecans of the capitellum in young baseball players. Report of three cases. *J Bone Joint Surg Am* 80:892–897
24. Turati M, Anghilieri FM, Bigoni M, Rigamonti L, Tercier S, Nicolaou N et al (2023) Osteochondritis dissecans of the knee: Epidemiology, etiology, and natural history. *J Child Orthop* 17:40–46
25. van Bergen CJ, Gerards RM, Opdam KT, Terra MP, Kerkhoffs GM (2015) Diagnosing, planning and evaluating osteochondral ankle defects with imaging modalities. *World J Orthop* 6:944–953
26. van Bergen CJ, van den Ende KI, Ten Brinke B, Eygendaal D (2016) Osteochondritis dissecans of the capitellum in adolescents. *World J Orthop* 7:102–108
27. van Bergen CJA, Baur OL, Murawski CD, Spennacchio P, Carreira DS, Kearns SR, et al. (2018) Diagnosis: History, Physical Examination, Imaging, and Arthroscopy: Proceedings of the International Consensus Meeting on Cartilage Repair of the Ankle. *Foot Ankle Int* 39:3S-8S
28. van Diepen PR, Dahmen J, Altink JN, Stufkens SAS, Kerkhoffs GMMJ (2021) Location distribution of 2,087 osteochondral lesions of the Talus. *Cartilage* 13:1344S-1353S
29. Verhagen RA, Maas M, Dijkgraaf MG, Tol JL, Krips R, van Dijk CN (2005) Prospective study on diagnostic strategies in osteochondral lesions of the talus. Is MRI superior to helical CT? *J Bone Joint Surg Br* 87:41–46
30. Wall E, Von Stein D (2003) Juvenile osteochondritis dissecans. *Orthop Clin North Am* 34:341–353
31. Zaremski JL, Herman DC, Vincent KR (2015) Clinical utility of Wilson test for osteochondral lesions at the knee. *Curr Sports Med Rep* 14:430

Publisher's Note Springer Nature remains neutral with regard to jurisdictional claims in published maps and institutional affiliations.