

COVID-19 IN INTENSIVE CARE

Neurological complications of COVID-19



Virginia F. J. Newcombe¹, Neha S. Dangayach² and Romain Sonnevile^{3,4*} 

© 2021 Springer-Verlag GmbH Germany, part of Springer Nature

There is growing recognition that severe acute respiratory syndrome coronavirus-2 (SARS-CoV-2) infection can lead to both acute and long-term neurological sequelae [1]. In addition to the neurological consequences of severe illness in itself, proposed mechanisms of SARS-CoV-2-associated neurological complications include direct neuroinvasion, and indirect mechanisms, of vascular and inflammatory/autoimmune origin (Fig. 1). The identification and diagnosis of these neurological complications are challenging, particularly in the context of overstrained medical systems, where an under-recognition of neurological manifestations may contribute to an increase in acute and long-term complications and poor outcomes. In addition, there is a high incidence of general critical care complications, for example, hypoxia, metabolic derangements, general inflammation, and drug toxicity/side effects, which can make proper attribution to coronavirus disease 2019 (COVID-19) difficult. We discuss the neurological complications associated with COVID-19 (NeuroCOVID) for general intensivists with an emphasis on key symptoms and signs to look for which may change management and/or provide a potential avenue for targeted therapies to improve outcomes.

In an early case series from Wuhan >45% of COVID-19 patients had neurological symptoms that involved both the central nervous system (i.e. anosmia/ageusia, altered mental status, stroke, and seizure) and the peripheral nervous system (i.e. muscle/nerve disease) (Supplementary Table 1) [2]. Subsequent multicentre studies revealed that encephalopathy (31–42%) and stroke syndromes (36–62%) account for most of the COVID-19-associated neurological complications, with inflammatory syndromes, i.e. encephalitis (5–13%) and Guillain-Barré (5–9%) much less frequent [3, 4]. The overall incidence

of ischemic stroke is relatively high. It tends to occur in younger patients, with more frequent large vessel occlusion and higher mortality than described in patients without COVID-19 [5] and those with influenza [6]. Of the common sequelae, stroke and inflammatory syndromes seem to have the worst outcomes.

Delirium and coma are diagnosed in more than 50% and 80% of patients admitted to the intensive care unit (ICU) with COVID-19, respectively. Notably, a high exposure to sedatives, mainly benzodiazepines has been independently associated with higher rates of delirium [7]. After cessation of sedatives, patients with severe respiratory failure secondary to COVID-19 may have a prolonged period of unconsciousness which may be weeks before complete recovery [8]. Caution is therefore advised when prognosticating in these patients.

Abnormalities detected on neuroimaging in patients with COVID-19 who require critical care are described in Supplementary Table 2. The most common findings include leukoencephalopathy, ischemia/infarction with patterns of large vessel occlusion, leptomeningeal enhancement, encephalitis, haemorrhage in locations not typical for hypertension (lobar and/or cortical; which raises the question of whether it is secondary to anticoagulation), and perfusion abnormalities.

Microhaemorrhages are a frequent finding on susceptibility-weighted imaging. They are particularly located in callosal and juxtacortical regions in a distribution distinct from other causes of similar lesions, including traumatic brain injury. Such microhaemorrhages have also been described in critically ill ventilated patients who do not have COVID-19, and it is unclear whether these may be secondary to COVID-19 itself or a complication of being critically ill with prolonged respiratory failure and hypoxemia [9]. For both microhaemorrhages and leukoencephalopathy, an association with microvascular disease has been described in post mortem studies of patients with COVID-19 [10]. Advanced magnetic resonance imaging (MRI) using diffusion tensor imaging has

*Correspondence: romain.sonneville@aphp.fr

³ Université de Paris, INSERM UMR1148, team 6, F-75018 Paris, France
Full author information is available at the end of the article

Potential mechanisms and complications of NeuroCOVID

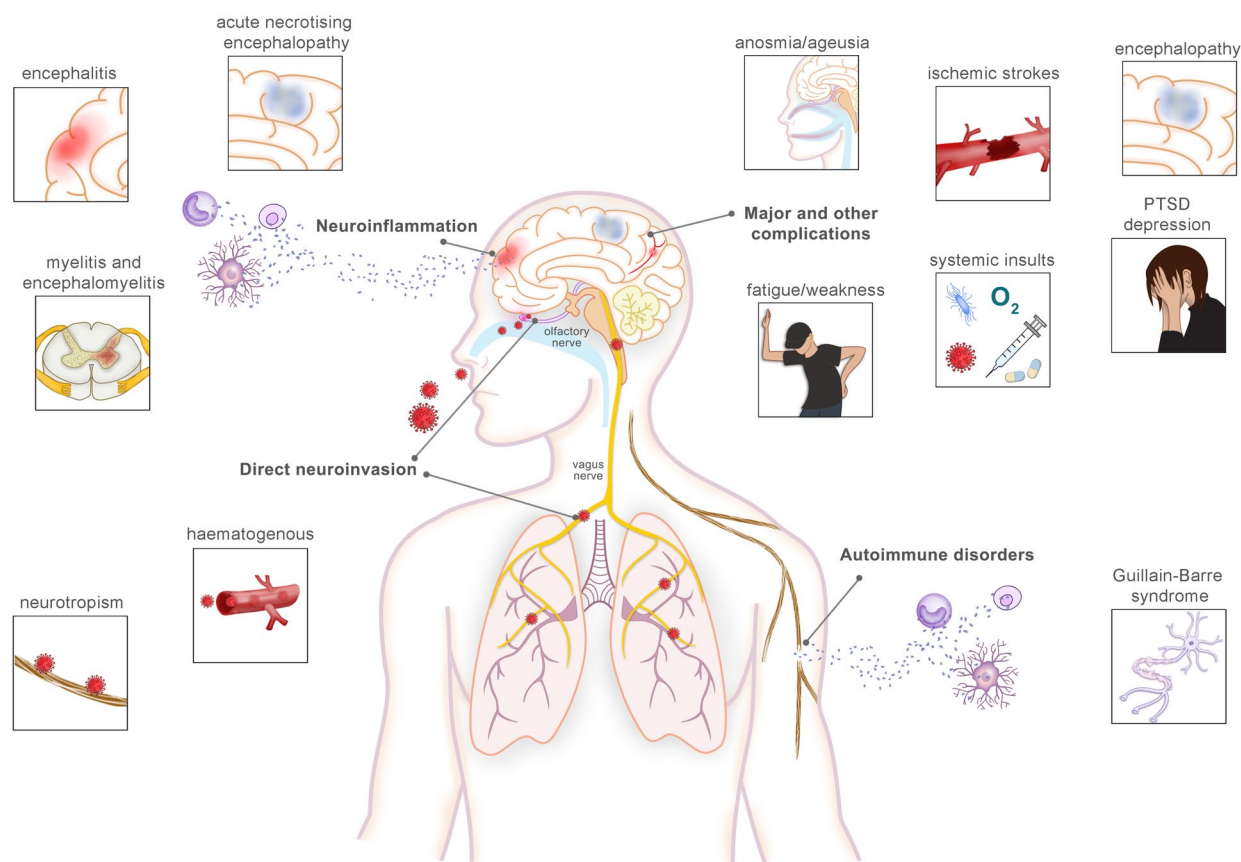


Fig. 1 Schematic of potential mechanisms and complications of NeuroCOVID. Direct infection and replication via transsynaptic spread of peripheral and cranial nerves (e.g. vagal or olfactory nerves) or blood–brain barrier dysfunction may lead to the clinical syndromes of encephalitis, myelitis and meningitis (S1). However, given that detection of SARS-CoV-2 in CSF via Polymerase Chain Reaction (PCR) or intrathecal antibodies is rare, direct neuroinvasion is likely to account for only a minority of cases (S2). Neuroinflammation with entry to the CNS of cytokines is thought to occur (S1). Autoimmune neurological syndromes including acute disseminated encephalomyelitis, myelitis, and Guillain–Barre Syndrome have also been reported (S3). Endotheliopathy and/or hypercoagulability have been implicated in the pathogenesis of stroke secondary to COVID-19 (S4, S5). PTSD post traumatic stress disorder. Image created with BioRender.com. References for the figure may be found in the Supplementary material

found abnormalities consistent with widespread oedema, including in crucial brainstem arousal nuclei in patients with persistent unresponsiveness [11]. These findings provide a potential explanation of prolonged altered sensorium and mental status in patients with COVID-19.

There is a growing number of studies confirming that neuroprotective measures should be maintained in patients with COVID-19. In one retrospective study, measurement using ultrasound of the Optic Nerve Sheath Diameter (ONSD) found that 19% of patients potentially had raised intracranial pressure, which was associated with a longer stay in ICU [12]. Electroencephalogram recordings obtained in critically ill patients also tend to be consistent with encephalopathy rather

than non-convulsive status epilepticus and may suggest COVID-19 related brain injury [13].

Neurointensive care management during the first COVID-19 waves has required adaptations to existing protocols for common neurological emergencies, including stroke, status epilepticus, neuroprotective strategies, venothromboembolism prophylaxis, and delirium management. Multimodal evaluation (MRI, cerebral spinal fluid analysis and electroencephalography) of COVID-19 patients with persistent encephalopathy allowed identification of rare cases of COVID-19 associated encephalitis, mainly of immune-mediated origin (including brainstem or limbic encephalitis, and acute disseminated encephalitis). For those with likely neuroinflammatory

syndromes, there is a need for careful consideration of therapy, as cases of steroid-responsive encephalitis have been described [14]. In such patients, a combination of high-dose steroids and intravenous immunoglobulins or plasma exchange may be considered.

Many survivors of critical illness develop post intensive care syndrome (PICS) which may cause cognitive, mental health, and physical impairments, with significant impacts on function and quality of life (Supplementary Fig. 1). The effects of this may be further compounded by post acute sequelae of COVID-19 (PASC), and so the rehabilitation needs of these patients may be significant [15]. Critical care recovery clinics with in-person and telehealth options have become valuable resources for ICU survivors and their families. The impact of COVID-19 centres with multidisciplinary services to address the ongoing medical and rehabilitation needs of COVID-19 survivors needs to be studied to guide hospitals and health systems in planning and preparing resources for millions of survivors. Unsurprisingly, given the trauma of a critical care admission, and the added stresses of the pandemic including a lack of family visits in many hospital systems, there is a high prevalence of post-traumatic stress symptoms [15].

There is a need to monitor patients with COVID-19 for neurological complications, at the acute phase and in the long term. In addition, those with a prolonged course of recovery will place additional burdens on overstretched systems. Ongoing studies will help identify patients at higher risk of developing neurological complications, streamline neuromonitoring strategies and guide management despite limitations on resources. Global collaboration and harmonization of such efforts will be important to facilitate rapid understanding of how best to manage the neurological complications of COVID-19, and so optimize outcomes.

Supplementary Information

The online version contains supplementary material available at <https://doi.org/10.1007/s00134-021-06439-6>.

Author details

¹ University Division of Anaesthesia, Department of Medicine, University of Cambridge, Cambridge, UK. ² Neurocritical Care Division, Departments of Neurosurgery and Neurology, Icahn School of Medicine at Mount Sinai, New York, NY, USA. ³ Université de Paris, INSERM UMR1148, team 6, F-75018 Paris, France. ⁴ Department of Intensive Care Medicine, AP-HP, Hôpital Bichat - Claude Bernard, 46 rue Henri Huchard, F-75877 Paris Cedex, France.

Funding

VFJN is supported by an Academy of Medical Sciences/The Health Foundation Clinician Scientist Fellowship, and holds a grant with Roche pharmaceuticals. NSD received grants from the Freidman Brain Institute (FBI), Neurocritical Care Society, Bee Foundation, University of Connecticut's Social Media and mHealth Institute, honoraria for Grand Rounds. RS received grants from the French Ministry of Health, the French society of intensive care medicine (SRLF), and the European society of intensive care medicine (ESICM).

Declarations

Conflict of interest

The authors declare that they have no conflict of interest.

Publisher's Note

Springer Nature remains neutral with regard to jurisdictional claims in published maps and institutional affiliations.

Received: 21 March 2021 Accepted: 17 May 2021

Published online: 7 June 2021

References

- Zubair AS, McAlpine LS, Gardin T, Farhadian S, Kuruvilla DE, Spudich S (2020) Neuropathogenesis and neurologic manifestations of the coronaviruses in the age of coronavirus disease 2019: a review. *JAMA Neurol* 77:1018–1027
- Mao L, Jin H, Wang M, Hu Y, Chen S, He Q, Chang J, Hong C, Zhou Y, Wang D et al (2020) Neurologic manifestations of hospitalized patients with coronavirus disease 2019 in Wuhan, China. *JAMA Neurol* 77:683–690
- Varatharaj A, Thomas N, Ellul MA, Davies NWS, Pollak TA, Tenorio EL, Sultan M, Easton A, Breen G, Zandi M et al (2020) Neurological and neuropsychiatric complications of COVID-19 in 153 patients: a UK-wide surveillance study. *Lancet Psychiatry* 7:875–882
- Meppiel E, Peiffer-Smadja N, Maury A, Bekri I, Delorme C, Desestret V, Gorza L, Hauteclouque-Raysz G, Landre S, Lannuzel A et al (2021) Neurologic manifestations associated with COVID-19: a multicentre registry. *Clin Microbiol Infect* 27:458–466
- Nannoni S, de Groot R, Bell S, Markus HS (2021) Stroke in COVID-19: a systematic review and meta-analysis. *Int J Stroke* 16:137–149
- Merkler AE, Parikh NS, Mir S, Gupta A, Kamel H, Lin E, Lantos J, Schenck EJ, Goyal P, Bruce SS et al (2020) Risk of ischemic stroke in patients with coronavirus disease 2019 (COVID-19) vs patients with influenza. *JAMA Neurol* 77(11):1366
- Pun BT, Badenes R, La Calle GH, Orun OM, Chen W, Raman R, Simpson BK, Wilson-Linville S, HinojalOlmedillo B, de la Cueva AV et al (2021) Prevalence and risk factors for delirium in critically ill patients with COVID-19 (COVID-D): a multicentre cohort study. *Lancet Respir Med* 9:239–250
- Abdo WF, Broerse CI, Grady BP, Wertenbroek A, Vijlbrief O, Buise MP, Beukema M, van der Kuil M, Tuladhar AM, Meijer FJA et al (2021) Prolonged unconsciousness following severe COVID-19. *Neurology* 96:e1437–e1442
- Thurnher MM, Boban J, Roggla M, Staudinger T (2021) Distinct pattern of microsusceptibility changes on brain magnetic resonance imaging (MRI) in critically ill patients on mechanical ventilation/oxygenation. *Neuroradiology*. <https://doi.org/10.1007/s00234-021-02663-5>
- Lee MH, Perl DP, Nair G, Li W, Maric D, Murray H, Dodd SJ, Koretsky AP, Watts JA, Cheung V et al (2021) Microvascular injury in the brains of patients with covid-19. *N Engl J Med* 384:481–483
- Newcombe VFJ, Spindler LRB, Das T, Winzeck S, Allinson K, Stamatakis EA, Menon DK (2021) Cambridge neurocovid imaging C: neuroanatomical substrates of generalized brain dysfunction in COVID-19. *Intensive Care Med* 47:116–118
- Battaglini D, Santori G, Chandraptham K, Iannuzzi F, Bastianello M, Tarantino F, Ball L, Giacobbe DR, Vena A, Bassetti M et al (2020) Neurological complications and noninvasive multimodal neuromonitoring in critically ill mechanically ventilated COVID-19 patients. *Front Neurol* 11:602114
- Vespignani H, Colas D, Lavin BS, Soufflet C, Maillard L, Pourcher V, Paccoud O, Medjbar S, Frouin PY (2020) Report on electroencephalographic findings in critically ill patients with COVID-19. *Ann Neurol* 88:626–630
- Cao A, Rohaut B, Le Guennec L, Saheb S, Marois C, Altmayer V, Carpentier VT, Nemlaghi S, Soulie M, Morlon Q et al (2020) Severe COVID-19-related encephalitis can respond to immunotherapy. *Brain* 143:e102
- Martillo M, Dangayach N, Tabacof L, Spielman L, Dams-O'Connor K, Chan C, Kohli-Seth R, Cortes M, Escalon M (2021) Postintensive care syndrome in survivors of critical illness related to coronavirus disease 2019. *Crit Care Med*. <https://doi.org/10.1097/CCM.0000000000005014>