

IMAGING IN INTENSIVE CARE MEDICINE



The 'blinking frog' ultrasound sign establishes the presence of pretracheal vasculature

Pieter R. Tuinman^{1,2,3,4*} , David van Westerloo⁵, Stefanie Slot¹ and Hugo R. W. Touw^{1,6}

© 2018 The Author(s)

Percutaneous dilatational tracheostomy is a common bedside procedure in intensive care units (ICUs) worldwide. A feared complication of the procedure is bleeding. Ultrasound guidance during percutaneous dilatational tracheostomy can reduce the risk of bleeding by identifying the presence of vasculature in the pretracheal or paratracheal regions and is recommended in recent guidelines.

In a 71-year-old patient with community-acquired pneumonia and ICU-acquired weakness, an indication for tracheostomy was made after a failed extubation. During ultrasound scanning of the trachea in the transverse plane, the presence of pretracheal vasculature was identified (Fig. 1a, b; Movie 1). The image of the trachea with two inferior thyroid veins on both sides above the trachea resembles the head of a frog with its eyes open (Fig. 1a). Applying slight pressure with the probe makes the vessels disappear, which looks like closing of the eyes (Fig. 1b). We call this the 'blinking frog sign'. The risk of per-procedural bleeding was considered to be increased.

In conclusion, the 'blinking frog' ultrasound sign establishes the presence of pretracheal vasculature and is a relative contraindication to tracheostomy at this particular part of the trachea. A higher or lower puncture location should be considered.

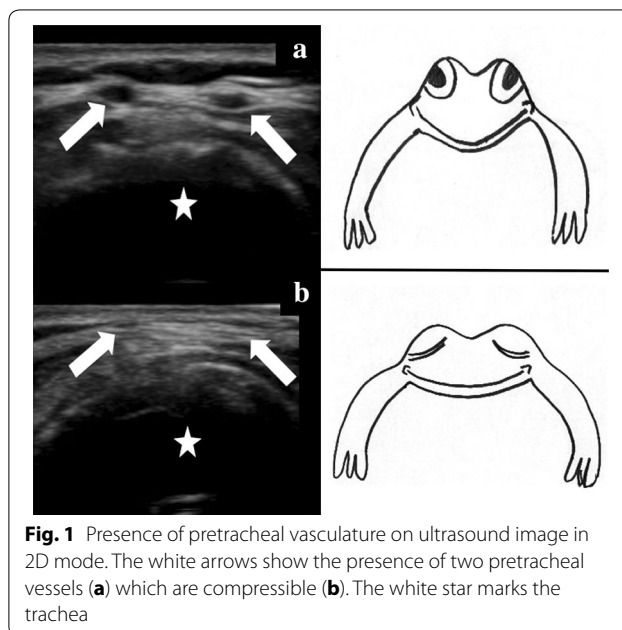


Fig. 1 Presence of pretracheal vasculature on ultrasound image in 2D mode. The white arrows show the presence of two pretracheal vessels (a) which are compressible (b). The white star marks the trachea

Electronic supplementary material

The online version of this article (<https://doi.org/10.1007/s00134-018-5435-y>) contains supplementary material, which is available to authorized users.

Author details

¹ Department of Intensive Care Medicine, Amsterdam UMC, Vrije Universiteit Medical Center, Room ZH, 7B-90, De Boelelaan 1117, PO Box 7057, 1007 MB Amsterdam, The Netherlands. ² Research VUmc Intensive Care (REVIVE), Amsterdam UMC, Vrije Universiteit Amsterdam, de Boelelaan 1117, Amsterdam, The Netherlands. ³ Amsterdam Cardiovascular Sciences (ACS), Amsterdam UMC, Vrije Universiteit Amsterdam, de Boelelaan 1117, Amsterdam, The Netherlands. ⁴ Amsterdam Infection and Immunity Institute (AI&II), Amsterdam UMC, Vrije Universiteit Amsterdam, de Boelelaan 1117, Amsterdam, The Netherlands. ⁵ Department of Intensive Care, Leiden University Medical Center, Leiden, The Netherlands. ⁶ Radboud University Medical Center, Nijmegen, The Netherlands.

*Correspondence: ptuinman@vumc.nl

¹ Department of Intensive Care Medicine, Amsterdam UMC, Vrije Universiteit Medical Center, Room ZH, 7B-90, De Boelelaan 1117, PO Box 7057, 1007 MB Amsterdam, The Netherlands

Full author information is available at the end of the article

Author contributions

PRT, DW, SS and HT contributed substantially to the study design and the writing of the manuscript.

Compliance with ethical standards**Conflicts of interest**

The authors declare they have no conflict of interest relevant to this manuscript

Ethical approval

The Commission for Medical Ethics (METc) of VUmc has approved this research: METC: 2016.053.

Informed consent

Written informed consent was given by the family of the patient.

Open Access

This article is distributed under the terms of the Creative Commons Attribution-NonCommercial 4.0 International License (<http://creativecommons.org/licenses/by-nc/4.0/>), which permits any noncommercial use, distribution, and reproduction in any medium, provided you give appropriate credit to the original author(s) and the source, provide a link to the Creative Commons license, and indicate if changes were made.

Received: 18 October 2018 Accepted: 24 October 2018

Published online: 30 October 2018