

20. Breuckmann F, Hochadel M, Darius H et al (2015) Guideline-adherence and perspectives in the acute management of unstable angina – Initial results from the German chest pain unit registry. *J Cardiol* 66(2):108–113
21. Breuckmann F, Hochadel M, Münzel T et al (2015) Timing of percutaneous coronary intervention in troponin-negative patients with acute coronary syndrome without persistent ST-segment elevation: preliminary results and status quo in German chest pain units. *Crit Pathw Cardiol* 14(1):7–11
22. Pollack CV Jr, Hollander JE, Chen AY et al (2009) Non-ST-elevation myocardial infarction patients who present during off hours have higher risk profiles and are treated less aggressively, but their outcomes are not worse: a report from Can Rapid Risk Stratification of Unstable Angina Patients Suppress ADverse Outcomes with Early Implementation of the ACC/AHA Guidelines CRUSADE initiative. *Crit Pathw Cardiol* 8(1):29–33
23. Illmann A, Riemer T, Erbel R et al (2014) Disease distribution and outcome in troponin-positive patients with or without revascularization in a chest pain unit: results of the German CPU-Registry. *Clin Res Cardiol* 103(1):29–40
24. Maier LS, Darius H, Giannitsis E et al (2013) The German CPU Registry: comparison of troponin positive to troponin negative patients. *Int J Cardiol* 168(2):1651–1653
25. Borna C, Thelin J, Ohlin B (2014) High-sensitivity troponin T as a diagnostic tool for acute coronary syndrome in the real world: an observational study. *Eur J Emerg Med* 21(3):181–188
26. Thiele H, Rach J, Klein N et al (2012) Optimal timing of invasive angiography in stable non-ST-elevation myocardial infarction: the Leipzig Immediate versus early and late Percutaneous coronary Intervention triAl in NSTEMI (LIPSIANSTEMI Trial). *Eur Heart J* 33(16):2035–2043

Herz 2016 · 41:731  
 DOI 10.1007/s00059-016-4507-4  
 Online publiziert: 7. November 2016  
 © Springer Medizin Verlag Berlin 2016



**A. Schmermund · J. Eckert · S. N. Schelle · H. Eggebrecht**  
 Cardioangiologisches Centrum Bethanien, Frankfurt am Main, Deutschland

## Erratum zu: Bildgebung bei struktureller Herzerkrankung

### Bedeutung für die interventionelle Therapie

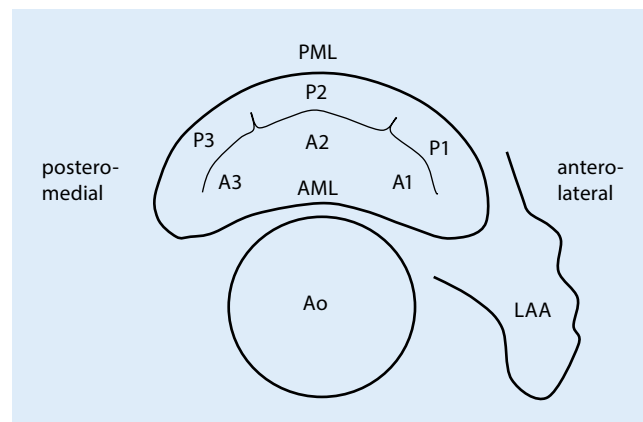
**Erratum zu:**  
**Herz (2016) 41:639–652**  
**DOI 10.1007/s00059-016-4481-x**

In **Abb. 1** ist leider ein Fehler vorhanden. Die Orientierung der P1/A1- und P3/A3-Segmente ist verkehrt herum dargestellt.

Wir bitten den Fehler zu entschuldigen.

#### Korrespondenzadresse

**Prof. Dr. A. Schmermund**  
 Cardioangiologisches Centrum Bethanien  
 Im Prüfling 23, 60389 Frankfurt am Main,  
 Deutschland  
[a.schmermund@ccb.de](mailto:a.schmermund@ccb.de)



**Abb. 1** ◀ Anatomie der Mitralklappe im Überblick (AML anteriores Mitralsegel mit den Segmenten A1–A3, Ao Aorta, LAA linkes Vorhofohr, PML posteriores Mitralsegel mit den Segmenten P1–P3)

Die Online-Version des Originalbeitrages finden Sie unter <http://dx.doi.org/10.1007/s00059-016-4481-x>