

problem, we usually pass an introducer (“bougie”) into the trachea through the ETT under vision and then guide the straight ETT into the trachea – under vision, this does require an extra maneuver.

Akihiro Suzuki MD PhD
Takayuki Kunisawa MD PhD
Hiroshi Iwasaki MD PhD
Asahikawa Medical College, Hokkaido, Japan
E-mail: masuikasuzuki@yahoo.co.jp
Accepted for publication May 23, 2007.

Reference

- 1 Koyama J, Aoyama T, Kusano Y, et al. Description and first clinical application of AirWay Scope for tracheal intubation. *J Neurosurg Anesthesiol* 2006; 18: 247–50.

In-line head and neck positioning facilitates tracheal intubation with the Airway Scope

To the Editor:

The Airway Scope, a new videolaryngoscope for tracheal intubation, has an anatomically shaped blade that provides a view of the glottis through a non-line-of-sight view with minimal airway manipulation. In contrast, the conventional Macintosh laryngoscope requires certain airway manipulation for laryngeal exposure, which involves alignment of the oral, pharyngeal and tracheal axes. To align these three axes, a pillow is placed under the head to facilitate direct exposure of the larynx. With respect to the Airway Scope, the importance of such a step is not clear. We report here the results of a study performed on a manikin to describe the preferable head and neck positioning for laryngeal exposure using the Airway Scope. This evaluation was performed as a part of our previously reported investigation.¹ In all, 40 operators intubated a 7-mm tracheal tube into the trachea of a manikin (Airway Management Trainer, Laerdal Medical Japan). Intubations with the aid of the Airway Scope were performed in both an in-line head and neck position without a pillow and in the sniffing position with a pillow (occipital elevation by 7 cm). The mean time required for accurate instrumentation was significantly shorter in an in-line head and neck position (8.9 ± 3.1 sec) than in the sniffing position (14.0 ± 10.8 sec, $P < 0.01$, \pm SD, paired t test). Our finding suggests that the device is particularly well suited for use in patients with an in-line head and neck position for proper airway management especially in

trauma patients with possible injury of the cervical spine where movement of the head and neck might be undesirable. Placement of a pillow under the head for the sniffing position during tracheal intubation with the Airway Scope does not seem to provide any advantage or speedier instrumentation.

Yoshihiro Hirabayashi MD
Jichi medical University, Tochigi, Japan
E-mail: yhira@jichi.ac.jp

Support was provided solely from institutional and/or departmental sources. The author has no affiliation with any manufacturer of any devices described in the manuscript.

Accepted for publication May 25, 2007.

Reference

- 1 Hirabayashi Y. Airway Scope versus Macintosh laryngoscope: a manikin study. *Emerg Med J* 2007; 24: 357–8.

Failure of the Airway Scope to reach the larynx

The Airway Scope (AWS) is a useful and possibly promising device for orotracheal intubation in a patient with a difficult airway,¹ because it provides an excellent view of the glottis without requiring alignment of the oral, pharyngeal, and laryngeal axes.² We, however, encountered a case in which the INTLOCK, the blade of the AWS, could not proceed beneath the epiglottis, and consequently the AWS failed to intubate the patient's trachea, probably because the distance from the mouth to the larynx of the patient was longer than the designed length of the INTLOCK.

A 74-yr-old man presented to the intensive care unit (ICU) because of respiratory failure from pneumonia one month after total gastrectomy. He had presented a Cormack and Lehane grade 3 view with a Macintosh laryngoscope on the day of the surgery. His trachea had been intubated using the McCoy laryngoscope (blade #4) with intense cricoid pressure according to the anesthetic chart.

In the ICU, since a Macintosh laryngoscopy again failed to expose the patient's glottis, we attempted to use the AWS for intubation. The INTLOCK was inserted into the pharynx without any difficulty, but the tip of the INTLOCK consistently advanced into the vallecula, and would not feed beneath the epiglottis. Although we could visualize the glottic opening under the epiglottis on the monitor of the AWS, we were unable to advance the tracheal tube into the

glottic opening because the epiglottis obstructed the laryngeal inlet. Ultimately, we intubated the patient's trachea using a McCoy laryngoscope (blade #4) with intense cricoid pressure once again.

The AWS is an excellent device for managing a difficult airway. One of the disadvantages of the device, possibly the most crucial disadvantage, however, is that it has only one fixed-size blade, which could cause failure to intubate. The blade, known as an INTLOCK, has an anatomically curved shape that seems to cover most of the adult population, but it can fail in a certain individuals, as described above. The present patient had a long neck with a thyromental distance of 9.5 cm, and hence the distance from his mouth to his larynx was probably longer than the designed length of the INTLOCK. When we attempted to reach the glottis by inserting the blade more deeply, the tip of the INTLOCK consistently advanced upward into the vallecula because of its natural curve. In contrast, in smaller patients the tracheal tube has a tendency to advance caudally, towards the esophagus, probably because the tip of the INTLOCK advances downward when it is inserted more shallowly. We feel that the AWS is an excellent device to manage the difficult airway, but we hope that different-sized INTLOCKS, including ones sized for children, will be available in the near future.

Nobuko Sasano MD PhD*
 Hiroki Yamauchi MD†
 Yoshihito Fujita MD PhD†
 Inabe General Hospital,*and Nagoya City University
 Graduate School of Medical Sciences,† Inabe City,
 Japan
 E-mail: nobusasano@aol.com
 Accepted for publication May 25, 2007.

References

- 1 Asai T, Enomoto Y, Okuda Y. Airway Scope for difficult intubation. *Anaesthesia* 2007; 62: 199.
- 2 Hirabayashi Y. AirWay Scope: initial clinical experience with novice personnel. *Can J Anesth* 2007; 54: 160-1.

Tracheal intubation through a single use laryngeal mask airway using a guidewire technique

To the Editor:

We report the case of a failed two-stage tracheal intubation through a single-use laryngeal mask airway (LMA), with subsequent rescue using a guidewire

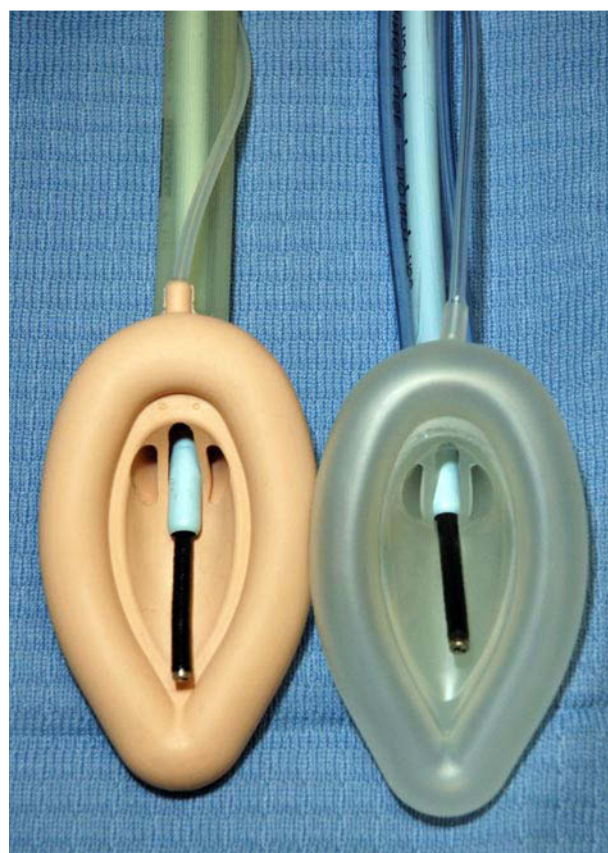


FIGURE the Aintree catheter loaded on a fibroscope and positioned between the aperture bars of a size 4 LMA® Classic and a size 4 LMA® -Unique.

technique. A 67-yr-old male patient weighing 65 kg presented for lumbar decompression. General anesthesia was induced with fentanyl and propofol. Atracurium 40 mg *iv* was administered after confirming adequacy of mask ventilation. Direct laryngoscopy revealed a grade 3 view (Cormack and Lehane) of the larynx despite optimization of head and neck position, and use of McCoy laryngoscope blade. A size 4 LMA® -Unique (Intavent Orthofix, Maidenhead, UK) was inserted, good seal was achieved, and adequate ventilation of the lungs was possible. We subsequently attempted to intubate using an Aintree intubation catheter (AIC) loaded on a fibroscope. A full view of the larynx was visible through the LMA and the fibroscope was easily advanced into the trachea. However, it was not possible to pass the Aintree catheter beyond the LMA aperture bars, despite adequate lubrication and rotational movement. At this stage a decision was made to pass a guidewire through the working chan-