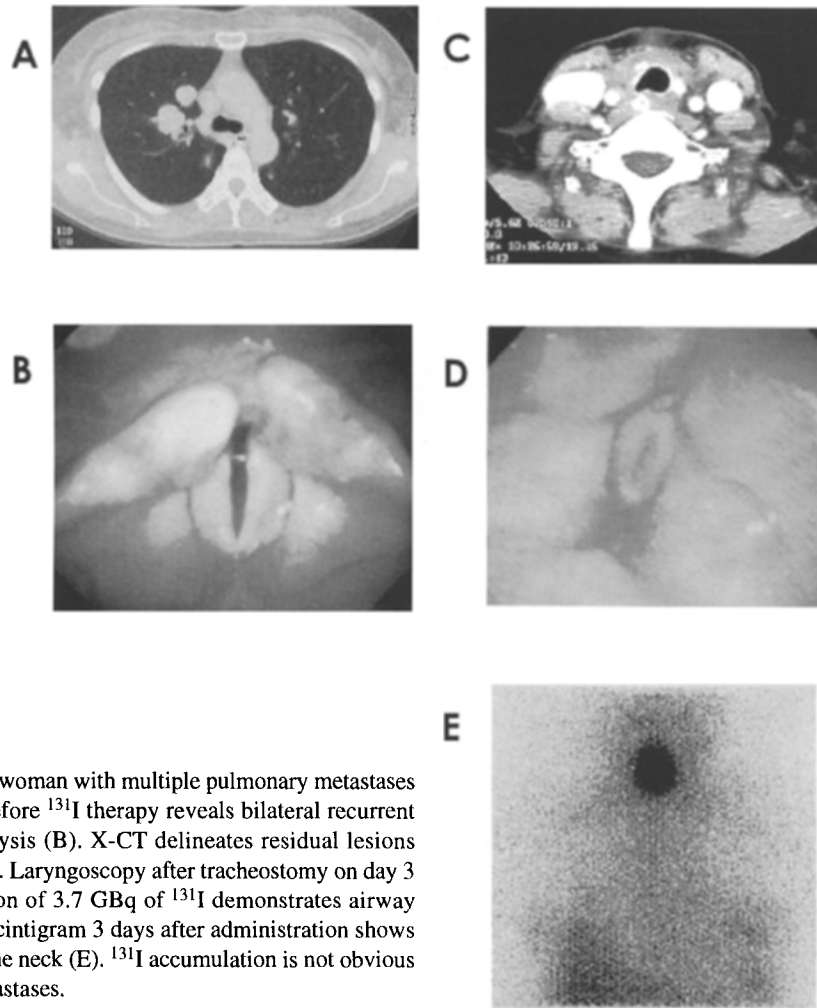


## Erratum

In the five photographs of Figure 1 in the paper of Seigo Kinuya et al. entitled 'Respiratory distress caused by radioiodine therapy in patients with differentiated thyroid cancer' in *Ann Nucl Med* Vol. 20, No. 7, the letters A–E were inadvertently omitted. We sincerely apologize for this error. The correct version of Figure 1 is published below.



**Fig. 1** A 55-year-old woman with multiple pulmonary metastases (A). Laryngoscopy before <sup>131</sup>I therapy reveals bilateral recurrent laryngeal nerve paralysis (B). X-CT delineates residual lesions around the trachea (C). Laryngoscopy after tracheostomy on day 3 after the administration of 3.7 GBq of <sup>131</sup>I demonstrates airway obstruction (D). <sup>131</sup>I scintigram 3 days after administration shows <sup>131</sup>I accumulation in the neck (E). <sup>131</sup>I accumulation is not obvious in the pulmonary metastases.