

## Correspondence

### *Fatal anaphylactic reaction to oral diclofenac sodium*

To the Editor:

Diclofenac sodium is commonly used in pain clinic and peri-operatively. We report a fatal anaphylactic reaction to oral diclofenac in a nine-year-old girl hospitalised for "transient synovitis". She had no history of atopy or cardio-respiratory illness and her clinical investigations were unremarkable. After symptomatic improvement on oral nimsulide and limb traction, oral diclofenac 25 mg twice daily was prescribed at discharge. At home, after a first dose of diclofenac, she complained of body aches, itching, showed cutaneous flushing and became febrile (38.9°C). Attributing her symptoms to fever, a second dose was given within two hours. Soon, the girl became restless, developed a generalised body rash and choking sensation. Within 35 min, she was brought to the ICU gasping, cyanosed, pulseless, with mid-dilated weakly reactive pupils and was intubated. Aggressive hemodynamic and respiratory support was provided but failed to resuscitate the child.

The second dose of diclofenac probably led to a fulminant allergic reaction while delayed hospitalisation likely proved fatal. Should routine sensitivity tests be performed with diclofenac sodium? This drug is considered safe with a worldwide experience of 7.6 million patients per year.<sup>1</sup> Van der Klauw *et al.* found 30 cases<sup>2</sup> of probable anaphylaxis to diclofenac in 992 reports on drug reaction. A fatal drug reaction following *im* diclofenac has been reported,<sup>3</sup> but sodium metabisulphite preservative as a cause was not ruled out. In a singular report of reaction to oral diclofenac, the patient survived due to prompt resuscitation.<sup>4</sup> It is therefore essential to remain aware of the toxic profile of all drugs. Prompt recognition and treatment of serious complications can help avert such untoward outcomes.

Indu Sen MD  
Sukanya Mitra MD  
Kanti K. Gombhar MD  
Chandigarh, India

#### References

- 1 O'Brien WM. Adverse reactions to nonsteroidal anti-inflammatory drugs. Diclofenac compared with other nonsteroidal anti-inflammatory drugs. *Am J Med* 1986; 80: 70–80.
- 2 Van der Klauw MM, Wilson JHP, Stricker BHCH. Drug-associated anaphylaxis: 20 years of reporting in the Netherland (1974–1994) and review of literature. *Clin Exp Allergy* 1996; 26: 1355–63.
- 3 Alkawajah AM, Eifawal M, Mahmoud SF. Fatal anaphylactic reaction to diclofenac. *Forensic Sci Int* 1993; 60: 107–10.
- 4 Milman U, Hermani D. Anaphylactic reaction to oral diclofenac sodium sustained release tablet. *Isr J Med Sci* 1994; 30: 909–10.

### *Effects of pirenzepine, omeprazole, lansoprazole, and rabeprazole on human neutrophil functions*

To the Editor:

Anesthesia and surgery inhibit several neutrophil functions<sup>1</sup> involved in antibacterial host defence mechanisms. Pirenzepine (a muscarinic receptor antagonist) and omeprazole, lansoprazole, and rabeprazole (proton pump inhibitors) are administered peri-operatively for prophylaxis against aspiration pneumonitis or stress ulceration.<sup>2–4</sup> Critically ill patients, potentially immunocompromised, often receive these gastric protective agents for the same purpose. This is why, after institutional approval and informed consent, we assessed chemotaxis, phagocytosis, and superoxide (O<sub>2</sub><sup>-</sup>) and hydrogen peroxide (H<sub>2</sub>O<sub>2</sub>) production of neutrophils isolated from 12 healthy adult volunteers in the presence of pirenzepine, omeprazole, lansoprazole, or rabeprazole at clinically relevant concentrations, four times, and ten times these concentrations, according to methods described previously.<sup>5</sup> We also measured intracellular calcium ion ([Ca<sup>++</sup>]<sub>i</sub>) concentrations and O<sub>2</sub><sup>-</sup> and H<sub>2</sub>O<sub>2</sub> production by the xanthine- xanthine oxidase system. Although pirenzepine, omeprazole, and lansoprazole had no effect on neutrophil chemotaxis, phagocytosis, O<sub>2</sub><sup>-</sup> and H<sub>2</sub>O<sub>2</sub> production, and the stimulant-induced elevation of [Ca<sup>++</sup>]<sub>i</sub>, rabeprazole inhibited these functions/responses in a dose-dependent manner (Figure). Rabeprazole impaired chemotaxis at clinically relevant concentrations. All drugs failed to scavenge O<sub>2</sub><sup>-</sup> and H<sub>2</sub>O<sub>2</sub> generated by an acellular system. Inhibition of calcium mobilization may have contributed, in part, to

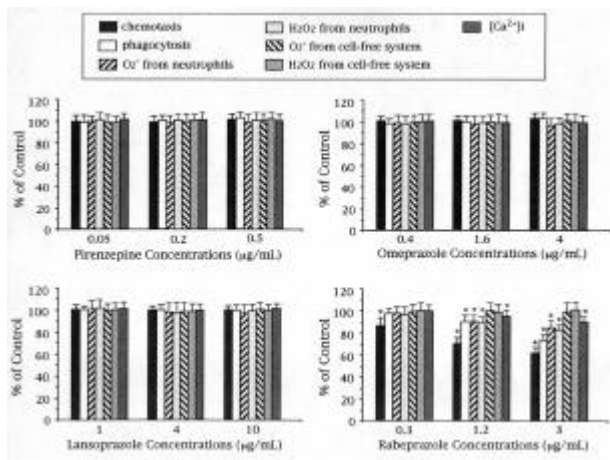


FIGURE 4 Data (mean  $\pm$  SD) are expressed as percentage of the control (in the absence of the drugs). \*  $P < 0.05$  vs control.

reduction of neutrophil function by rabeprazole. Thus, rabeprazole could be beneficial in non-septic patients with systemic inflammation or multiple organ failure. On the other hand, pirenzepine, omeprazole, and lansoprazole may not interfere with neutrophil function in infectious or septic patients. Further *in vivo* studies are required to assess the clinical effects of these gastric protectors on neutrophil function.

Katsuya Mikawa MD  
Hirohiko Akamatsu MD  
Kahoru Nishina MD  
Yukie Niwa MD  
Kobe, Japan

#### References

- 1 Khan FA, Kamal RS, Mithani CH, Khurshid M. Effect of general anaesthesia and surgery on neutrophil function. *Anaesthesia* 1995; 50: 769–75.
- 2 Maekawa N, Nishina K, Mikawa K, Shiga M, Obara H. Comparison of pirenzepine, ranitidine, and pirenzepine-ranitidine combination for reducing preoperative gastric fluid acidity and volume in children. *Br J Anaesth* 1998; 80: 53–7.
- 3 Nishina K, Mikawa K, Maekawa N, Takao Y, Shiga M, Obara H. A comparison of lansoprazole, omeprazole, and ranitidine for reducing preoperative gastric secretion in adult patients undergoing elective surgery. *Anesth Analg* 1996; 82: 832–6.
- 4 Nishina K, Mikawa K, Takao Y, Shiga M, Maekawa N, Obara H. A comparison of rabeprazole, lansoprazole, and ranitidine for improving gastric fluid property in

adults undergoing elective surgery. *Anesth Analg* 2000; 90: 717–21.

- 5 Nishina K, Akamatsu H, Mikawa K, et al. The inhibitory effects of thiopental, midazolam, and ketamine on human neutrophil functions. *Anesth Analg* 1998; 86: 159–65.

### *Retropharyngeal neurofibroma presenting with severe kypho-scoliosis: respiratory obstruction in postoperative period*

To the Editor:

Space occupying lesions in the retropharyngeal space are rare. Various masses have been described including angiofibroma,<sup>1</sup> ganglioneuroma,<sup>2</sup> malignant mesenchymoma,<sup>3</sup> neuroblastoma<sup>4</sup>; the commonest are hematomas.<sup>5</sup> The clinical presentation is varied but most had presenting symptoms of dyspnea and dysphagia. In this 27-yr-old patient the retropharyngeal neurofibroma presented with severe cervical kypho-scoliosis (Figures 1,2) and neurological symptoms of tingling and numbness in both arms but there were no

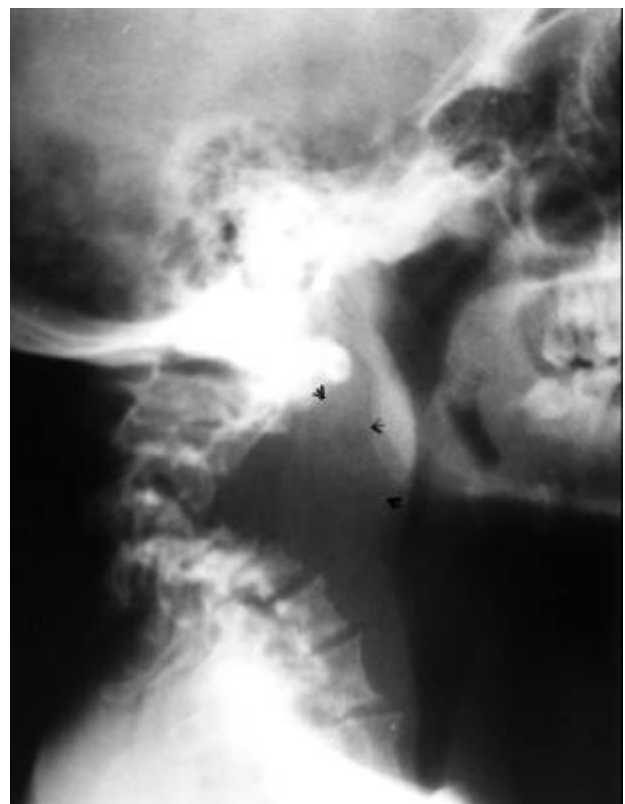


FIGURE 1 Plain radiograph of neck in lateral view showing extreme kyphosis.