

ephedrine and atropine. She developed severe headache, agitation, dyspnoea, diaphoresis, and thoracic and head blushing. Blood pressure was 245/125 mm Hg and HR 135 - 140 bpm. This changed to bradycardia and multiple, multifocal ventricular extrasystoles persisting for seconds. Midazolam, thiopentone and nitroglycerine boluses were administered: BP decreased to 185/105 mm Hg, and ECG showed sinus tachycardia. Ten minutes later BP was 130/75 mm Hg, and HR was 110 bpm. The patient had been treated with phenelzine, 15 mg daily for six months, which was inadvertently omitted from the history.

A 72 yr old woman with Parkinson's disease (treated with selegiline 10 mg daily) had fixation of a neck femoral fracture, under spinal anaesthesia. She developed bradycardia and hypotension and received atropine and ephedrine. Blood pressure increased to 240/120 mmHg and supraventricular tachycardia treated with urapidil and amiodarone. After 15 min, BP and HR were normal.

Recently, reversible MAO-A inhibitors (RIMA's) and selective MAO-B inhibitors have been synthesized<sup>1</sup> and, although indirect or mixed agents sympathomimetic (e.g. ephedrine) are contraindicated direct agents are said to be safe.

The first patient had a typical MAOI interaction with indirect sympathomimetics and the second showed a typical non-selective MAOI interaction, although the selegiline (MAOI-B) dose was in the selective range (< 20 mg·day<sup>-1</sup>)<sup>3</sup>. Anaesthetic-related adverse reactions have been not described with this drug<sup>3</sup> and concern about MAOI interactions continues.<sup>4,5</sup>

Carlos L. Errando MD PhD  
Eva Mateo MD  
Dolores López-Alarcón MD  
Susana Moliner MD  
Hospital General Universitario de Valencia  
Valencia, Spain.

#### REFERENCES

- 1 Wells DG, Bjorksten AR. Monoamine oxidase inhibitors revisited. *Can J Anaesth* 1989; 36: 64-74.
- 2 el-Ganzouri AR, Ivankovich AD, Braverman B, McCarthy R. Monoamine oxidase inhibitors: should they be discontinued preoperatively? *Anesth Analg* 1985; 64: 592-6.
- 3 Kando JC, Kalunian DA. Focus on selegiline: a selective monoamide oxidase type B inhibitor. *Hosp Formul* 1990; 25: 849-58.
- 4 Clark AG. MAOIs and anaesthesia (Letter). *Can J Anaesth* 1996; 43: 641.

- 5 Roizen MF. Monoamine oxidase inhibitors: are we condemned to relive history, or is history no longer relevant? (Editorial) *J Clin Anesth* 1990; 2: 293-5.

### *Propofol administered via the carotid artery to achieve a Wada test*

To the Editor:

The unilateral injection of a short-acting barbiturate into an internal carotid artery (Wada-test) is used pre-operatively to identify the dominant hemisphere in ambidextrous patients.<sup>1-3</sup> However, amytal, amobarbitone and methohexitone are no longer available in France, hence we have tested propofol, which is not vascularly toxic,<sup>4</sup> in this situation.

A 43-yr-old ambidextrous consenting man presented with a tumour situated in the left temporal occipital area. Lateralization of cerebral speech dominance before temporal lobectomy was desired. Trans-femoral left carotid arterial catheterization was carded out under local anaesthesia. The patient was asked to keep his right upper limb elevated and to count loudly without interruption. Twenty milligrams of propofol were then injected into the left carotid artery which was followed, 13 sec later, by complete paresis of the right upper limb and total arrest of speech for 18 sec. The EEG recordings showed slow polymorphic activity over the left fronto-temporal area of the brain. The latter decreased in intensity six minutes later. At the *same* time, motor and speech functions recovered. A total amnesia of the entire previous period was recorded. The patient described only the perception of an intense blue light. The fact that the patient totally broke off his speech, proved left localization of the speech site and injection into the right carotid was unnecessary.

To our knowledge, this observation is the first to describe the use of propofol to carry out a Wada-type test. The rapid psychomotor recovery and the absence of adverse events are undoubtedly an asset.

Jean E. Bazin MD, Pascale Picard MD,  
Jean Gabrillargues MD, Monique Dordain MD  
Departments of Anaesthesia and Radiology  
University Hospital  
Clermont-Ferrand, France.

#### REFERENCES

- 1 Wada J, Rasmussen T. Intracarotid injection of sodium amytal for lateralization of cerebral speech dominance. *J Neurosurg* 1960; 17: 226-32.
- 2 Trenerry MR, Loving DW. Intracarotid amobarbital procedure. The Wada test. *Neuroimaging Clin North Am* 1995; 5: 721-8.

- 3 Isnard J, Garde P, Fischer C, Duquesnel J, Manguiere F. Manifestations cliniques et electro-encephalographiques lors du test de Wada par injection intracarotidienne de methohexital. *Rev Neurol* 1994; 150: 266-73.
- 4 MacPherson RD, Rasiah RL, McLeod LJ. Intraarterial propofol is not directly toxic to vascular endothelium. *Anesthesiology* 1992; 76: 967-71.

### *A tip for the Trachlight™*

To the Editor:

I would like to report a modification of the technique for tracheal intubation using the Trachlight™ lightwand. It is not uncommon to have some difficulty passing the tube into the trachea after the larynx has been transilluminated and the stylet has been partially withdrawn. I have attributed this to the mechanical disadvantage that is created when the inner stylet is withdrawn, leaving a flexible tube oriented parallel to the

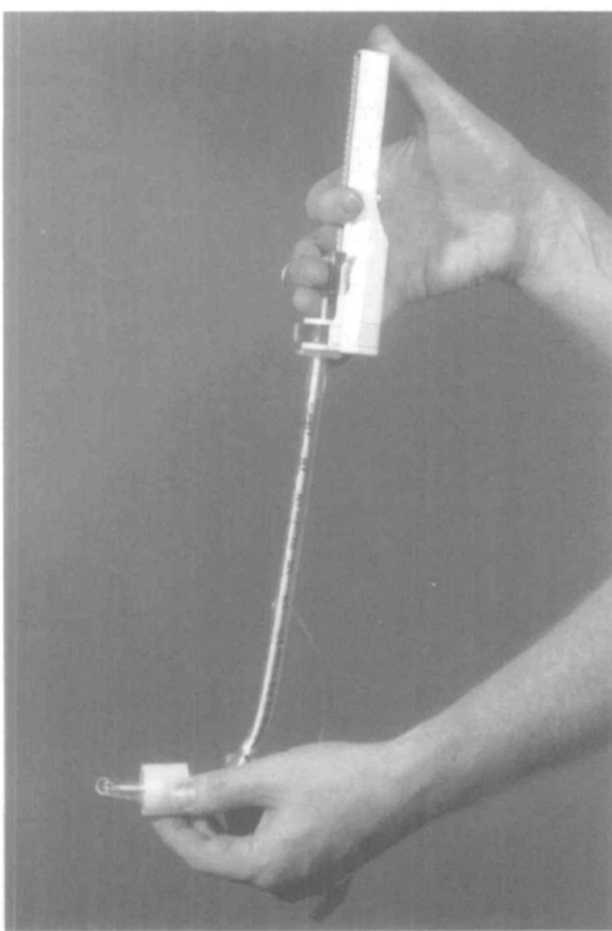


FIGURE 1

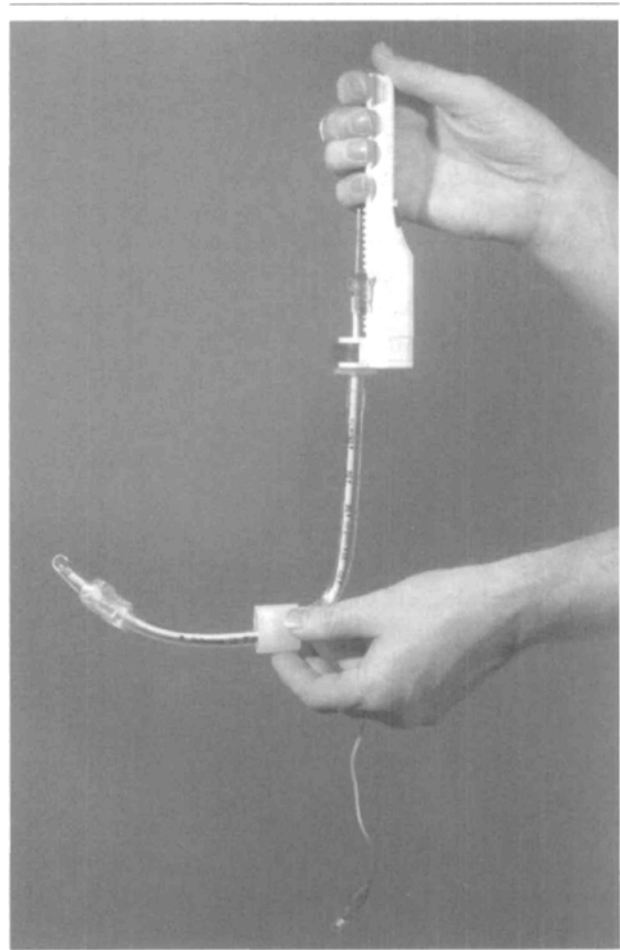


FIGURE 2

trachea at the end of a rigid stylet oriented perpendicular to the trachea. Manipulations are sometimes required to place the tracheal tube and occasionally the tube is displaced posteriorly. I have made the following modification to simplify tube passage.

To get the longest stylet length, I do not cut size #7 or #7.5 tubes and trim larger tubes to 29 cm. The Trachlight™ is held in the dominant hand with the thumb gently opposing. The larynx is transilluminated and, rather than retracting the stylet, the thumb is slid to the top of the Trachlight™ handle and used to push the handle vertically down while the finger holding the stylet maintains its position. (Figure 1) This retracts the stylet distally, while converting some of the vertical height of the stylet into horizontal distance. (Figure 2) The tube moves down the trachea a distance equivalent to the distance that the handle is displaced relative to the hook of the stylet. Tracheal passage of the tube is usually successful and quick.