

## Erratum

**G. P. Cantore, R. Delfini, A. Mariottini, A. Santoro, and P. Cascone**, “Anterior Displacement of the Mandible for Better Exposure of the Distal Segment of the Extracranial Carotid Artery”. *Acta Neurochirurgica* (1987) 86: 56–60.

The complete Fig. 5 on page 60 should look:

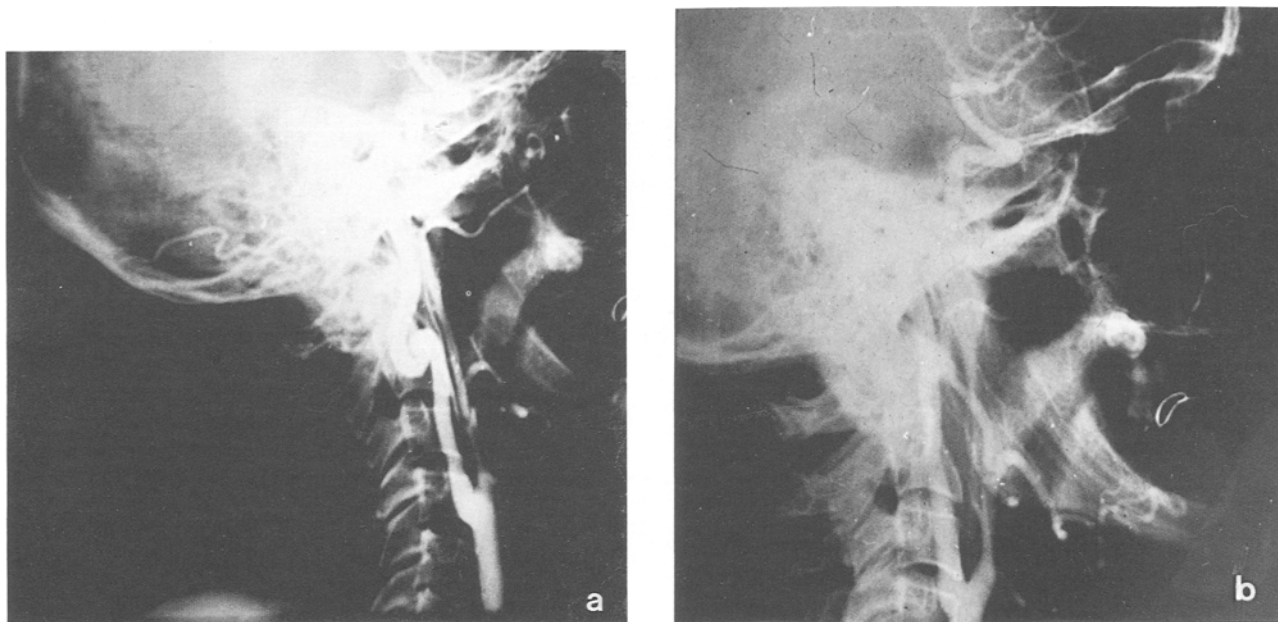


Fig. 5. Pre- (a) and post-operative (b) angiography of a coil of the ICA at C1–C2. Resection with termino-terminal suture between the 2 stumps of the ICA