

## The Virology and Pathogenesis of Feline Infectious Peritonitis

### Brief Review

By

M. C. HORZINEK and A. D. M. E. OSTERHAUS

Institute of Virology, Veterinary Faculty, State University Utrecht,  
Utrecht, The Netherlands

With 2 Figures

Accepted July 13, 1978

### Introduction

Feline infectious peritonitis (FIP) is a collective term for conditions occurring in wild and domestic cats which are caused or triggered by a virus infection. Morphological and serological evidence suggests that the agent should be classified as a new member of the Coronaviridae family. In the light of present knowledge the term FIP has a limited descriptive value since peritonitis is only one amongst several pathological pictures by which the infection may present itself. Inapparent in most cases, it is fatal once classical symptoms have appeared. During the last years several relevant papers have been published on virological and serological aspects of FIP; in this article a review of these and older data is given and a hypothesis on the pathogenesis of FIP is presented. For more clinical and pathological information the reader is referred to recent survey articles by PEDERSEN (64), JONES (37), HORZINEK and OSTERHAUS (32) and OTT (60).

### The Virus

#### *Morphology*

The infectious nature of FIP was demonstrated in 1966 when the disease was transmitted by inoculating ascitic fluid from field cases into susceptible cats (72). Unfiltered abdominal exudate and 450-, 220- and 100-nm filtrates of various organ suspensions from cats with natural and experimental FIP have been shown to reproduce the disease in cats (25, 80, 81, 84, 90). In ultrathin sections through mesothelial cells, virus-like particles with an average diameter of 73 nm (70 to 94 nm) were observed; they appear spherical or elliptical with a ring-shaped nucleoid 50—73 nm in diameter and show indistinct surface projections. The nucleoid contains a central electron lucent area of about 30 nm and is surrounded by a trilaminar membrane structure. Particles are located intracellularly in the

Golgi vesicles and have been observed to bud from smooth surfaced cisternae of the endoplasmic reticulum. Budding from the plasma membrane, as described for the feline leukemia and sarcoma viruses, has not been found with the 73 nm-particles (80, 81, 84, 90).

The assumption that the observed particles are the causative agent in FIP had to be verified. Their resemblance with members of the Coronaviridae family (79) was already noted by WARD (81). Employing two physical parameters of coronaviruses (sedimentation coefficient 400 S, buoyant density 1.17 g/ml), OSTERHAUS *et al.* (56) were able to purify a class of homogenous particles from ascitic fluid and FIP liver suspensions and to demonstrate pleomorphic 100 nm virions by negative staining electron microscopy. Regularly spaced club- or petal-shaped projections 12–15 nm in length qualified them as coronavirus-like. Using gradient purified material the disease could be reproduced in experimental kittens; particles of identical morphology were detected in the animals which succumbed whereas they were not found in the surviving cats (33).

#### *Taxonomy*

On the basis of these results, HORZINEK *et al.* (33) have proposed that FIP virus should be classified as a new member of the family Coronaviridae, which is in accordance with Ward's earlier observations (81) and is supported by the antigenic relationship of FIP virus with transmissible gastroenteritis (TGE) virus, a porcine coronavirus (57, 71, 87). Coronaviridae family members are defined as pleomorphic enveloped particles, averaging 100 nm in diameter, containing RNA and essential lipid. They bear morphologically unique projections, which have been described as bulbous, club- or petal-shaped. Coronavirus polypeptide patterns so far published may have three common features. There is generally a high molecular weight glycosylated polypeptide associated with the surface projection and lower molecular weight polypeptides which are membrane associated. A non-glycosylated 50–60,000 molecular weight polypeptide is found in most cases (19, 29, 76).

An infectious RNA of about  $8 \times 10^6$  with covalently attached polyadenylic acid sequences has been extracted from an avian coronavirus (45); this implies that the nucleic acid is plus-stranded and functions as a messenger molecule. Ribonucleoprotein strands 14 to 16 nm in diameter and up to 320 nm in length were released from human and murine coronaviruses (47) indicating a helical symmetry of the nucleocapsid. No information on molecular parameters is presently available for FIP virus which is the first feline coronavirus; other members of the family have been identified as pathogens in man, the mouse, rat, calf, pig, chicken, turkey (79) and the dog (3). A virus of similar morphology has been isolated from ticks (77).

#### *Serology*

High titres of neutralizing antibody against TGE virus were reported to be present in the sera and peritoneal fluids of domestic cats suffering from FIP (71, 87). Using a FITC-conjugated gamma globulin preparation from ascitic fluid of a FIP-affected leopard, antigen was demonstrated in porcine thyroid cells after infection with TGE virus. However, FIP viral antigen could not be detected in cat organ material using labelled porcine anti-TGE immunoglobulin (87). The hetero-

logous reaction was adapted for seroepidemiological screening by using suspensions of TGE virus infected pig thyroid cells, dried and fixed onto microscope slides, as an antigen source for an indirect immunofluorescence test; antibody in feline serum specimens was detected by reacting them with a labelled anti-cat IgG serum (Fig. 1a). When the cells had been treated with an unlabelled porcine anti-TGE serum prior to incubation with a known-positive cat serum, significant quenching of fluorescence occurred (57). Recent studies by PEDERSEN *et al.* (67) confirmed the FIP-TGE virus antigenic relationship and in addition disclosed serologic cross reactions with the human coronavirus 229E and a canine coronavirus (3). The four viruses form a distinct antigenic cluster and do not cross-react with mouse hepatitis virus type 3, calf diarrhea coronavirus, hemagglutinating encephalomyelitis virus of swine and the human coronavirus OC43, which, on their part, are antigenically interrelated.

Some apparent contradictions remain unresolved. In their immunofluorescence tests, WITTE *et al.* (87) found no reaction between FIP virus antigen and TGE antiserum and considered there was a "one-way" antigenic cross reaction. PEDERSEN *et al.*, on the other hand, obtained cross reactions in both directions (67). Variable results have also been reported using neutralization tests. In the first publications (71, 87) neutralizing activity against TGE virus was demonstrated in the body fluids of FIP cases, but two different laboratories<sup>1</sup> were unable to detect significant neutralizing TGE antibodies in sera which were positive in the heterologous immunofluorescence test in our laboratory (57).

After cats were inoculated with TGE virus by the intranasal, conjunctival and oral routes, they developed an inapparent infection which was accompanied by the formation of TGE virus neutralizing antibody; titres could be considerably increased by an intraabdominal booster injection. However, these animals were not protected against a challenge infection with FIP virus (87).

Table 1. *Results of homologous and heterologous tests showing the antigenic relationship between FIP and TGE virus (References in parenthesis)*

IFT (direct or indirect)	FIP viral antigen	TGE viral antigen
Anti-FIP virus serum/conjugate	positive (63)	positive (57, 67, 87)
Anti-TGE virus conjugate	positive (67) negative (86, 87)	positive
Neutralization test	FIP virus	TGE virus
Anti-FIP virus serum	positive (34)	positive (71, 87) negative (57)
Anti-TGE virus serum	negative (34)	positive

<sup>1</sup> The cooperation of Dr. P. A. Bachmann, Munich, and Mrs. D. J. Reynolds, Compton, is gratefully acknowledged.

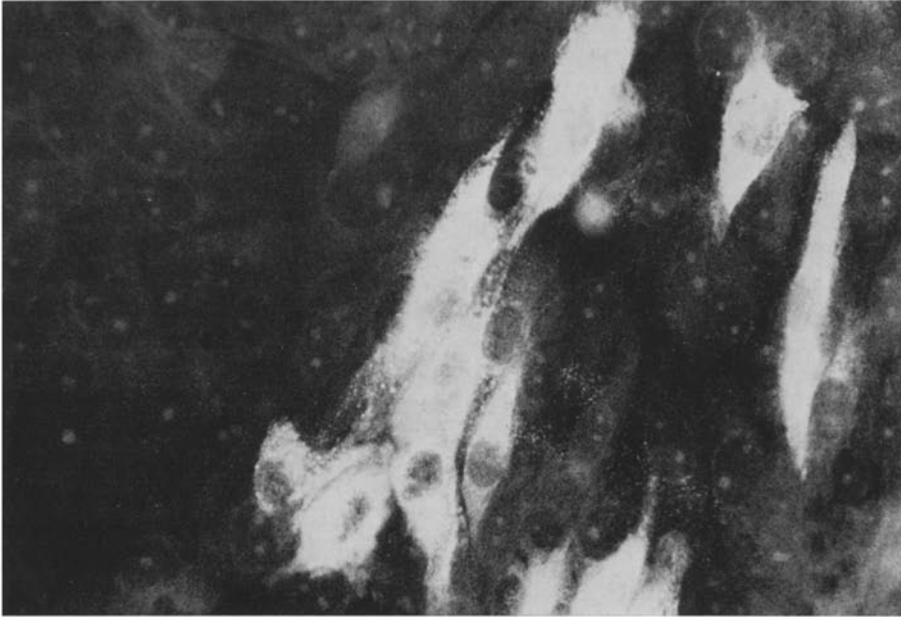


Fig. 1a

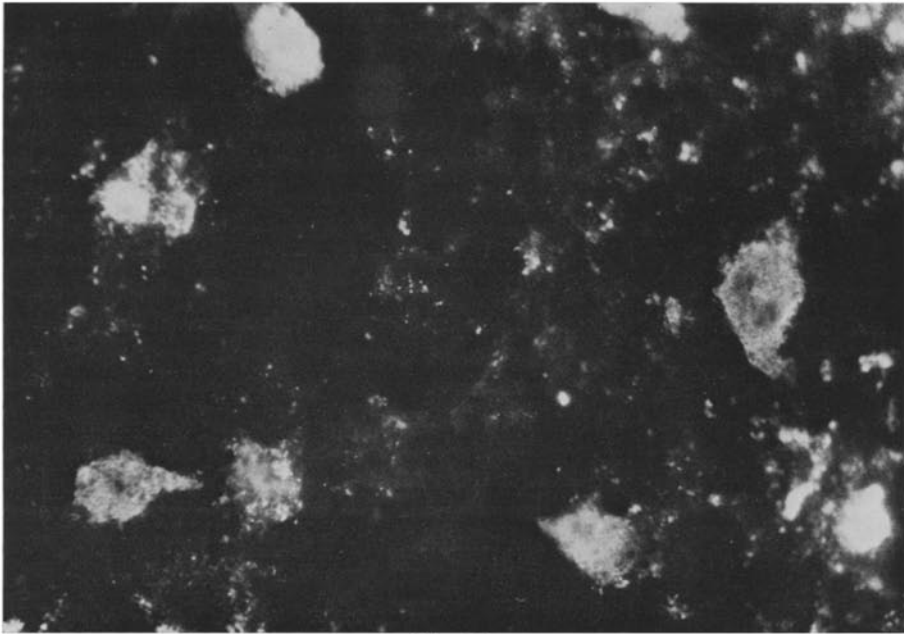


Fig. 1b

Fig. 1. Immunofluorescence reaction for the detection of antibodies to FIP virus (a) and of antigen in FIP virus infected mouse brain (b). For serology, the indirect heterologous reaction was employed, using TGE virus (strain Purdue) infected porcine kidney cells, the feline serum to be tested and conjugated rabbit anti-cat IgG (a). Multiplication of FIP virus in the suckling mouse was demonstrated by reacting brain smears with a FITC conjugated ascites fluid from a field case of FIP (b)

Using mouse brain adapted FIP virus (58) we were able to show that homologous neutralizing antibodies (titres exceeding 40,000 against about 20 ID<sub>50</sub> units of FIP virus) are present in diseased cats. High titered porcine anti-TGE sera, however, did not neutralize FIP virus (34). The results of serological cross-testing are summarized in Table 1. A practical consequence of the above findings is the application of heterologous immunofluorescence for the laboratory diagnosis of TGE infection in pigs (86) using conjugated FIP ascitic fluid, which has the advantage of high antibody contents and can be produced in commercially available SPF cats.

In conclusion, the causative agents of FIP and TGE are definitely distinct viruses which share antigenic determinants. It remains to be shown whether the inconsistent results reported are due to the existence of FIP viral serotypes.

### *Propagation*

Coronaviruses are often fastidious viruses to propagate in cell culture; this is also true for FIP virus which so far has not been adapted to growth in primary feline cells or continuous lines (46, 61, 62). *In vitro* growth has been demonstrated in cultures derived from peritoneal exudate cells of kittens after experimental infection with FIP virus (62). Since this system is not suitable for quantitative routine work, we focused our attention on laboratory animals. The mouse was selected since coronaviruses of man, mouse, rat, chicken (49) and pig (39) have been successfully adapted to growth in mouse tissue, and this species — being the cat's predominant prey animal — might be a reservoir host in the epidemiology of FIP. It has been established that FIP virus multiplies in brain tissue of SPF suckling mice (58). Virus replication is not accompanied by overt clinical signs and therefore must be recognized by immunofluorescence (Fig. 1b). In one-day-old mice titres approaching 10<sup>6</sup> ID<sub>50</sub> units have been found. Older suckling mice appear less susceptible to infection and at the age of 14 days virus multiplication could no longer be detected. The growth curve in neonatal mice shows a steep slope from the first day on and reaches a maximum at 3 days after infection (p. i.); subsequently, a rapid decline in infectivity is noted until at day 8 the brains contain no more detectable virus. All attempts by serial blind passages to recover infectivity from mice > 14 days p. i. were without success. — The maximum of infectivity does not coincide with optimal cerebral fluorescence, which has been found at 5 days p. i. (34).

Mouse brain-adapted FIP virus also multiplies after intracerebral inoculation of the suckling rat and hamster. In rats, growth retardation has been noted in the infected animals as compared with the fluorescence — negative controls; although significant, it is no consistent symptom in the mouse (58) and hamster (59).

## **The Disease**

### *Host Range*

Although FIP originally was believed to affect predominantly young cats (31, 35, 82, 88), later observations showed that it may occur at about the same rate in animals of all age groups (72). Also a predilection for certain breeds (88) and a higher incidence in male cats (10, 72, 88) could not be confirmed (26, 36, 62, 82).

In addition to the domestic cat (family Felidae, subfamily Felinae) FIP has been reported in members of the subfamilies Pantherinae (lion, jaguar, leopard) and Lyncinae (caracal) (9, 68, 72, 78); no FIP cases have been published for members of the subfamily Acinonychinae (cheetahs), for Mustelids, Procyonids and Viverrids, which are notoriously affected by other feline viral pathogens, e.g. panleukopenia virus and caliciviruses.

#### *Incubation Period*

The incubation period in naturally occurring FIP cases obviously cannot be determined exactly; epizootiologic observations indicate that periods of at least four months are likely to occur (24, 25, 72). In experimentally induced cases it tends to be shorter and sometimes first febrile reactions are observed within one week after infection (4, 24, 82). The route of infection, the origin and passage history of the material and the age of the infected animals may all influence the incubation period (62). In our hands, experimental intraperitoneal infection once caused death within five days.




Fig. 2. A pronounced case of FIP (Photograph by courtesy of Feline Advisory Bureau, England)

#### *Clinical Symptoms*

The initial clinical symptoms of naturally acquired FIP are not very characteristic. The affected animal shows anorexia, a usually biphasic temperature curve and general depression, which may persist over a long period. In classical cases these symptoms are accompanied by gradual abdominal distension which — in

combination with a progressive emaciation — often results in a dehydrated animal with an enlarged undulating abdomen (Fig. 2). Despite the presence of peritonitis, abdominal palpation is not painful. In cases with pleuritis, dyspnoea may be seen. Once these symptoms have become evident, cats die within a period of one to eight weeks (9, 31, 35, 62, 72, 75, 78, 82, 88). Neurological signs and ocular lesions have been reported by various authors (5, 6, 7, 13, 18, 20, 30, 52, 65, 74, 89). Organ material from cats with ocular lesions and no ascitic fluid was shown to reproduce the peritoneal form of FIP, indicating that the same virus can produce the different clinical pictures (73). Haematological examination may show a normochromic normocytic anaemia, low haematocrit values and a leucocytosis mainly caused by neutrophilia with a mild left shift accompanied by lymphopenia, eosinopenia and monocytosis (4, 12, 25, 50, 62, 78, 82, 89). In terminal or fulminating cases, however, leucopenia may occur. Elevation of blood urea nitrogen and bilirubin, of the enzymes glutamic-pyruvic transaminase, lactate dehydrogenase and alkaline phosphatase on one hand and proteinuria with increased levels of bilirubin and urobilinogen on the other hand, may be found as a reflection of liver damage and renal disease (4, 12, 75). Total serum proteins are elevated in most cases (4, 22, 62). This elevation is due mainly to an increase of the gamma globulins, which has been considered as a manifestation of immune response (22, 62, 70). The peritoneal fluid is clear, straw-coloured, viscid and ropy, tends to clot on exposure to air, may contain fibrin flakes and is encountered in volumes of some milliliters to more than one liter in domestic cats. It is an exudate (specific gravity 1.017 to 1.047) and contains high concentrations of protein (3.4—11.8 g/per cent).

#### *Pathology*

The most important macroscopic feature in classical cases is a visceral and parietal fibrinous peritonitis and/or pleuritis in the presence of fluid in the body cavities. The visceral peritoneum, in most cases showing more pronounced alterations than the parietal layer, is covered by a fibrinous exudate which is associated with disseminate white necrotic plaques, varying in size from pinpoint to 3 millimeters in diameter and extending into the organ parenchyma. The exudate is thickest and most noticeable on the liver and spleen. In cases where pleuritis is present, a hydrothorax may occur and atelectasis may follow. Fibrinous adhesions between the liver and the diaphragm, but also involving other abdominal organs are frequently found and are most marked in protracted cases (4, 78, 82, 89). With and without serositis and fluid accumulations in the body cavities, there may be focal necrosis and inflammation scattered through the parenchyma of various organs, particularly liver, kidneys, lungs and spleen. In many cases the mesenteric and caecal lymph nodes are enlarged and may show the typical lesions. Especially in the kidneys the necrotic areas tend to coalesce, involving large areas of the renal cortex. The lesions found in the eyes and in the central nervous system are comparable with these processes. Some authors proposed a subdivision into a “wet” form of FIP in which the fibronecrotic, exudative inflammation of the serosae prevails and a non-effusive or “dry” form, in which the small organ lesions are most prominent and peritoneal and/or pleural effusions are absent (52, 62). However, no strict distinction can be made: in the “wet” form lesions are often seen in some organs and in “dry” forms, some exudate may be found in the body cavities.

Histologically, the layer of exudate adherent to the peritoneum is composed mainly of fibrin with little cellular infiltration; merely some nuclear debris, necrobiotic neutrophils, histiocytes, lymphocytes, neocapillaries and fibroblasts can be observed in the exudate layer. Between these foci, mesothelial hyperplasia namely the formation of cuboidal or columnar cells, is always found. Subcapsular infiltrations of plasma cells and lymphocytes and multiple subserosal foci of coagulative necrosis are also observed which extend into the parenchyma of the organs. The focal areas of necrosis in the liver in many cases are the result of direct extension from the surface, although similar foci occur deep within the parenchyma, suggesting a haematogenous spread (4, 78, 82, 89). The lesions are often located around the smaller vessels (venules, arterioles and lymph vessels) where they are the expression of a vasculitis and thrombovasculitis.

#### *FIP Immune Complex Pathogenesis: A Hypothesis*

As has been pointed out, FIP is characterized by an extended incubation period, a lengthy, progressively debilitating, lethal course, and pathologic manifestations unlike those customarily associated with viral infections. By experimental infection of cats it has been demonstrated that FIP virus can be recovered from abdominal fluid, organ homogenates and blood of natural cases throughout the clinical course and after death. Since the natural incubation period may extend up to 4 months and survival has been reported for up to 6 months after clinical diagnosis (60) virus certainly persists. Hyperproteinemia is a consistent feature in natural FIP; from the data presented by 13 authors, a value of  $8.55 \pm 1.79$  g/per cent ( $n=45$ ; figures are given as mean values  $\pm$  standard deviation) was computed which is significantly higher than the normal values for animals over 9 months, namely  $6.65 \pm 0.75$  g/per cent (23). For ascitic fluids a protein concentration of  $6.01 \pm 1.38$  g/per cent ( $n=30$ ) was calculated. The hyperproteinemia is due mainly to an elevation of the  $\gamma$ -globulins (22) which average  $3.59 \pm 2.2$  g/per cent ( $n=32$ ) as compared with  $1.41 \pm 0.52$  g/per cent for normal cats of the 9 months age group (23). In ascitic fluids about the same values were found ( $3.57 \pm 1.76$  g/per cent;  $n=8$ ).

It has been demonstrated recently that low titered antibodies to FIP virus occur in apparently healthy cats (44, 57, 63); in diseased animals, however, inordinately high titres were found i.e. 25,600, by homologous indirect immunofluorescence (63). Using mouse-adapted FIP virus we were able to show, that virus neutralizing antibodies are present in the sera of field cases of FIP (34); although of very high titer ( $>40,000$ ) they obviously have no protective value in the disease. It remains to be shown whether the polyclonal IgG (22) is directed solely or predominantly against FIP virus.

Conceivably, it is the persistence of virus in the presence of specific, high titering antibody which gives rise to an immune pathology of FIP. The situation is resembling that in Aleutian disease, a debilitating disease in ranch-bred mink (21) in which proliferation of plasma cells and a heterogenous hypergammaglobulinemia (IgG levels 3—5 g/per cent) with elevated antibody concentrations (48, 69) are observed. The gammaglobulin fails to control viral replication, and helps to produce glomerular and vascular lesions such as fibrinoid necrosis of the media of small and medium sized arteries. In most chronic viral infections persistent viremia



stimulates a continuous low-level immune response with resultant complex formation and with antigen in excess (54). However, animals which have high antibody responses may also develop immune complex disease with antibody in excess, as exemplified by Aleutian disease (69). Hyperglobulinemia is also consistently observed in equine infectious anemia (28), in the presence of persistent viremia; some animals have been known to carry infective virus in their blood for as long as eighteen years. The condition is usually chronic with periods of exacerbation (c. f. 42); possibly large antigenic loads occur from time to time and account for the manifestation of immune complex disease.

Although immune complexes have not yet been demonstrated in FIP virus infections, there are indications that antigen-antibody-complement (Ag-Ab-C) interactions do occur *in vivo*. During attempts to purify FIP virus for electron microscopy from liver homogenates of animals which had succumbed we observed characteristic 6-nm pits on the viral envelope (33). "Virolysis" by Ag-Ab-C interactions has been described for different viruses (1, 55), also for Coronaviridae (2). Virus-Ab-complexes are potent pathogenic agents which after depositions in tissue induce inflammatory responses. Immune adherence has been described for macrophages, monocytes, polymorphonuclear leukocytes and certain lymphocytes. These cells carry receptors for C3 and can bind complexes bearing C3 on their surfaces (53). Neutrophils are the predominant cells in FIP effusions and in the circulating white cells. It has been demonstrated that neutrophils may be attracted to sites of immune complex deposition in many parts of the body (vessels, brain, kidney, etc.) by complement dependent processes; they are essential mediators of tissue damage due to the release of injurious constituents (proteases, collagenase, elastase, permeability factors; 27). Neutrophils which had been removed from immune complex lesions contain granules of antigen-antibody aggregates (8); it remains to be shown whether the intracytoplasmic inclusion bodies sometimes found in neutrophils of FIP cats (14, 85) consist of phagocytosed immune complexes. — On the other hand, binding of the virus-Ab-C-complex may be followed by phagocytosis, whereby the virus gains access to cells in which it persists. In the case of FIP the target cell is the macrophage — the only cell type which has been unequivocally shown to support virus replication (62).

It has been demonstrated that a disproportionately large number of cats suffering from FIP are seropositive for the feline leukemia virus (FeLV) group antigen; furthermore mortality rates due to FIP are higher in catteries where FeLV had been diagnosed than in those which are free from FeLV (11, 15, 24, 62, 66). Although FIP can be a serious problem also in FeLV-negative colonies (62) the oncornavirus infection seems to exert a promoting effect on the clinical manifestation of FIP. The degenerative disease resulting from FeLV infection of the lymphoreticular tissues is manifested by thymic atrophy and a marked depression of the cats' cell-mediated immunologic response. It is not clear at present whether this results in a higher susceptibility to primary infection by FIP virus or in manifestation of the disease in carrier cats.

It is not surprising that most therapeutic measures have no effect on a virus disease. However, administration of steroids (flumethasone, prednisolone) in connection with supportive therapy has been reported to result in temporary remissions and prolongation of the disease course of FIP (60). This has not been con-

firmed in controlled trials but may be significant in view of the hypothesis that the disease may be due in part to immune processes.

### *Epizootiology*

Although apparently increasing in frequency (64), FIP is only occasionally diagnosed in the low-density feline field population. In multiple cat households, catteries, colonies or zoos (11, 31, 68, 72, 78) clustering of cases has been observed, but the overall morbidity is usually low. However, in one closed breeding colony in the U.S.A., about half of the annual mortality could be attributed to FIP (70). The natural route of infection is not known. The virus is present in the blood and in peritoneal and pleural exudates of infected cats and can be transmitted to susceptible cats via the subcutaneous, intravenous and intraperitoneal routes (9, 24, 38, 40, 62, 82, 83, 84, 88). Obviously, transmission by blood sucking insects cannot be excluded (62, 70). Material containing FIP virus was instilled into the conjunctival sac but no symptoms followed (62), although cats could be infected with TGE virus by this route (87); urine from a large number of FIP field cases was inoculated intraperitoneally into susceptible kittens but no disease occurred.

Cats were fed virus containing material and the condition was not reproduced (62). Nevertheless, an earlier report states that the virus is shed in the urine and is infectious by the oral route (24); it is quite likely that FIP virus enters via mucosal surfaces like the related TGE virus and canine coronavirus, both of which cause intestinal infections.

The distribution of lesions in experimentally infected cats seems to be influenced by the route of inoculation. Intrapleural inoculation resulted in severe granulomatous pleuritis, intracerebral inoculation produced similar brain lesions, intravenous inoculation induced lesions of a systemic distribution and intranasal instillation caused diffuse granulomatous pneumonia. The distribution of lesions in natural FIP cases may therefore depend on the mode of exposure, the dose and possibly the strain of the infecting virus (83). Negative results in earlier infection experiments using randomly selected cats may not be conclusive since (possibly protective) antibody could not be detected by these workers. In random cat populations between 4 per cent and 41 per cent of the serum samples were shown to contain antibodies, when tested against FIP virus (44, 63) or TGE virus (57, 63, 87).

Epidemiological studies have demonstrated that of clinically normal cats from catteries in which FIP is a problem, 87 to 94 per cent were seropositive by indirect immunofluorescence; virtually all naturally infected animals with disease symptoms possess antibodies to high titre (44, 57, 63). It is reported that no antibody may be detected after experimental infection (57, 87), possibly due to the unnatural intraperitoneal route of infection or to the high dose of virus given and the more rapid course of the disease. — Amongst 109 sera from a barrier-contained SPF cat colony none was found positive (57).

### *Implications*

FIP and its virus are interesting for several reasons. From the veterinary point of view FIP is a "new" feline condition for which no prophylaxis is available at present. For the laboratory animal worker it is a disease of considerable impor-

tance in catteries, and its causative agent should be entered in the list of specific feline pathogens; serologic methods for monitoring SPF colonies are now available. If the immune pathogenesis of FIP can be confirmed, the reasons for its unique manifestation should be investigated. Classification of FIP virus in a separate genus of the Coronaviridae may become possible when the molecular and antigenic basis for the heterologous reactions has been established. The biology of the virus requires further study, particularly the restricted cell spectrum in the natural host and in experimentally infected rodents and also the abortive infection in the mouse.

### References

1. ALMEIDA, J. D., WATERSON, A. P.: The morphology of virus antibody interaction. *Adv. Virus Res.* **15**, 307—338 (1969).
2. BERRY, D. M., ALMEIDA, J. D.: The morphological and biological effects of various antisera on avian infectious bronchitis virus. *J. gen. Virol.* **3**, 97—102 (1968).
3. BINN, L. N., LAZAR, E. C., KEENAN, K. P., HUXSALL, D. L., MARCHWICKI, R. H., STRANO, A. J.: Recovery and characterization of a coronavirus from military dogs with diarrhea. *Proc. U.S. Anim. Hlth. Ass.* **78**, 359—366 (1974).
4. BLAND VAN DEN BERG, P., BOTHA, W. S.: Feline infectious peritonitis in South Africa. *J. South Afr. Vet. Ass.* **48**, 109—116 (1977).
5. BULLMORE, C. C., TWITCHELL, M. J.: A case of parenchymatous feline infectious peritonitis. *Fel. Pract.* **7**, 46—49 (1977).
6. CAMPBELL, L. H., REED, C.: Ocular signs associated with feline infectious peritonitis in two cats. *Fel. Pract.* **5**, 32—35 (1975).
7. CARLTON, W. W., LAVIGNETTE, A. M., SZECH, G. M.: A case of feline infectious peritonitis with ocular lesions. *J. Anim. Hosp. Ass.* **9**, 256—261 (1973).
8. COCHRANE, CH. G., WEIGLE, W. O., DIXON, F. J.: The role of polymorphonuclear leukocytes in the initiation and cessation of the Arthus vasculitis. *J. Exp. Med.* **110**, 481—494 (1959).
9. COLBY, E. D., LOW, R. J.: Feline infectious peritonitis. *Vet. Med. Small Anim. Clin.* **65**, 783—786 (1970).
10. COLGROVE, D. J., PARKER, A. J.: Feline infectious peritonitis. *J. Small Anim. Pract.* **12**, 225—232 (1971).
11. COTTER, S. M., GILMORE, C. E., ROLLINS, C.: Multiple cases of feline leukemia and feline infectious peritonitis in a household. *J. Amer. Vet. Med. Ass.* **162**, 1054—1058 (1973).
12. DISQUE, D. F., CASE, M. T., YOUNGREN, J. A.: Feline infectious peritonitis. *J. Amer. Vet. Med. Ass.* **152**, 372—375 (1968).
13. DOHERTY, M. J.: Ocular manifestations of feline infectious peritonitis. *J. Amer. Vet. Med. Ass.* **159**, 417—424 (1971).
14. EMPSON, R. M., JR.: Feline infectious peritonitis. In: *Current Vet. Therapy*. Philadelphia: V.W.B. Saunders Co.
15. EAGLE, G. C., BRODEY, R. S.: A retrospective study of 395 feline neoplasms. *Anim. Hosp.* **5**, 21—31 (1969).
16. EVANS, R., SALAMAN, M. H.: Studies on the mechanism of action of Riley virus. III. Replication of Riley's plasma enzyme elevating virus *in vitro*. *J. exp. Med.* **122**, 993—1002 (1965).
17. FANKHAUSER, R., FATZER, R.: Meningitis und Chorioependymitis granulomatosa der Katze; mögliche Beziehungen zur feline infektiösen Peritonitis (FIP). *Kleintier-Praxis* **22**, 1—44 (1977).
18. FELDMAN, B. F.: Feline infectious peritonitis: a case report of a variant form. *Fel. Pract.* **4**, 32—37 (1974).
19. GARWES, D. J., POCOCK, D. H.: The polypeptide structure of transmissible gastroenteritis virus. *J. gen. Virol.* **29**, 25—34 (1975).

20. GELATT, K. N.: Iridocyclitis and panophthalmitis associated with feline infectious peritonitis. *Vet. Med. Small Anim. Clin.* **68**, 56—57 (1973).
21. GORHAM, J. R., LEADER, R. W., PADGETT, G. A., BURGER, D., HENSON, J. B.: In: GAJDUSEK, D. C., GIBBS, C. J. (eds.), *Slow, latent, and temperate virus infections*. (NINDB, monograph 2), 279—285. Washington D. C.: U.S. Dept. Health, Educ. and Welfare 1965.
22. GOUFFAUX, M., PASTORET, P. P., HENROTEAUX, M., MASSIP, A.: Feline infectious peritonitis. Proteins of plasma and ascitic fluid. *Vet. Pathol.* **12**, 335—348 (1975).
23. GROULADE, P., GROULADE, J., GROSLAMBERT, P.: Age variation in the serum glycoproteins and lipoproteins of the normal cat. *J. Small Anim. Pract.* **6**, 333—361 (1965).
24. HARDY, W. D., HURVITZ, A. J.: Feline infectious peritonitis: experimental studies. *J. Amer. vet. Med. Ass.* **158**, 994—1002 (1971).
25. HARDY, W. D., O'REILLY, W. J.: Clinico-pathologic conference. *J. Amer. Vet. Med. Ass.* **155**, 1728—1733 (1969).
26. HAYASHI, T., GOTO, N., TAKAHASHI, R., FUJIWARA, K.: Systemic vascular lesions in feline infectious peritonitis. *Jap. J. Vet. Sci.* **39**, 365—377 (1977).
27. HENSON, P. M.: Interaction of cells with immune complexes: adherence, release of constituents, and tissue injuring. *J. exp. Med.* **134**, 114—135 (1971).
28. HENSON, J. B., MCGUIRE, T. C., KOBAYASHI, K., GORHAM, J. R.: The diagnosis of equine infectious anemia using the complement fixation test, siderocyte counts, hepatic biopsies and serum protein alteration. *J. Amer. Vet. Med. Ass.* **151**, 1830 to 1839 (1967).
29. HIERHOLZER, J. C., PALMER, E. L., WHITFIELD, S. G., KAYE, H. S., DOWDLE, W. R.: Protein composition of human coronavirus OC43. *Virology* **48**, 516—527 (1972).
30. HOLMBERG, C. A., GRIBBLE, D. H.: FIP: Diagnostic gross and microscopic lesions. *Fel. Pract.* **3**, 11—14 (1973).
31. HOLZWORTH, J.: Some important disorders of cats. *Cornell Vet.* **53**, 157—160 (1963).
32. HORZINEK, M. C., OSTERHAUS, A. D. M. E.: Feline infectious peritonitis: a coronavirus disease of cats. *J. Small Anim. Pract.* **19**, 561—568 (1978).
33. HORZINEK, M. C., OSTERHAUS, A. D. M. E., ELLENS, D. J.: Feline infectious peritonitis virus. *Zbl. Vet. Med. B* **24**, 398—405 (1977).
34. HORZINEK, M. C., OSTERHAUS, A. D. M. E., WIRAHADIREDJA, R. M. S., ELLENS, D. J.: Feline infectious peritonitis (FIP) virus. III. Studies on the multiplication of FIP virus in the suckling mouse. *Zbl. Vet. Med. B* (in press, 1978).
35. INGRAM, P. L.: The occurrence of feline infectious peritonitis in England. *Vet. Rec.* **86**, 632 (1970).
36. INGRAM, P. L.: Feline infectious peritonitis and its differential diagnosis. *J. Small Anim. Pract.* **12**, 301—306 (1971).
- 36a. JONES, B. R., HOOG, G. G.: Feline infectious peritonitis. *Austr. Vet. J.* **50**, 398 to 402 (1974).
37. JONES, B. R.: Feline infectious peritonitis: a review. *New Zeal. vet. J.* **23**, 221 to 225 (1975).
38. JONES, B. R., HOOG, G. G.: Feline infectious peritonitis. *Austral. Vet. J.* **50**, 398—402 (1974).
39. KAYE, H. S.: Antigenic relationship between human coronavirus strain OC43 and hemagglutinating encephalomyelitis virus strain 67N of swine: antibody responses in human and animal sera. *J. inf. Dis.* **35**, 201—209 (1977).
40. KONISHI, S., TAKAHASHI, E., OGATA, M., ISHIDA, K.: Studies on feline infectious peritonitis (FIP). I. Occurrence and experimental transmissions of the disease in Japan. *J. Vet. Sci.* **33**, 327—333 (1971).
41. KRUM, S., JOHNSON, K., WILSON, J.: Hydrocephalus associated with the non-effusive form of FIP. *J. Amer. Vet. Med. Ass.* **167**, 746—748 (1975).
42. LEADER, R. W., HURVITZ, A. J.: Interspecies patterns of slow virus diseases. *Amer. Rev. Med.* **23**, 191—200 (1972).
43. LEGENDRE, A. M., WHITENACK, D. L.: FIP with spinal cord involvement in two cats. *J. Amer. Vet. Med. Ass.* **167**, 931—932 (1975).

44. LOEFFLER, D. G., OTT, R. L., EVERMANN, J. F., ALEXANDER, J. E.: The incidence of naturally occurring antibodies against feline infectious peritonitis in selected cat populations. *Fel. Pract.* **8**, 43—45 (1978).
45. LOMNICZI, B.: Biological properties of avian coronavirus RNA. *J. gen. Virol.* **36**, 531—533 (1977).
46. LOW, R. J., COLBY, E. D., COVINGTON, H. J., BENIRSCHKE, K.: Report of the isolation of an agent from cell cultures of kidneys from domestic cats. *Vet. Rec.* **88**, 557—558 (1971).
47. MACNAUGHTON, M. R., DAVIES, H. A., NERMUT, M. V.: Ribonucleoprotein-like structures from coronavirus particles. *J. gen. Virol.* **39**, 545—549 (1978).
48. MCGUIRE, T. C., CRAWFORD, T. B., HENSON, J. B., GORHAM, J. R.: Aleutian disease of mink: detection of large quantities of complement-fixing antibody to viral antigen. *J. Immunol.* **107**, 1481—1482 (1971).
49. MCINTOSH, K.: Coronaviruses: a comparative review. *Curr. Top. Microbiol. Immunol.* **63**, 85—129 (1974).
50. MIEOG, W. H. W., RICHTER, J. H. M.: Feline infectious peritonitis. *Tijdschr. Diergeneesk.* **96**, 585—598 (1971).
51. MIMS, C. A.: Factors in the mechanism of persistence of viral infections. *Progr. med. Virol.* **18**, 1—14 (1974).
52. MONTALI, R. J., STRANDBERG, J. D.: Extraperitoneal lesions in feline infectious peritonitis. *Vet. Pathol.* **9**, 109—121 (1972).
53. OLDSTONE, M. B. A.: Virus neutralization and virus-induced immune complex disease. *Progr. med. Virol.* **19**, 84—119 (1975).
54. OLDSTONE, M. B. A., DIXON, F. J.: Immune complex disease in chronic viral infections. *J. exp. Med.* **134**, 32—40 (1971).
55. OROSZLAN, S., GILDEN, R. V.: Immune virolysis: effect of antibody and complement on C-type RNA virus. *Science* **168**, 1478—1480 (1970).
56. OSTERHAUS, A. D. M. E., HORZINEK, M. C., ELLENS, D. J.: Untersuchungen zur Ätiologie der Felines infektiösen Peritonitis (Vorläufige Mitteilung). *Berl. Münch. Tierärztl. Wschr.* **89**, 135—137 (1976).
57. OSTERHAUS, A. D. M. E., HORZINEK, M. C., REYNOLDS, D. J.: Seroepidemiology of feline infectious peritonitis virus infections using transmissible gastroenteritis virus as antigen. *Zbl. Vet. Med. B* **24**, 835—841 (1977).
58. OSTERHAUS, A. D. M. E., HORZINEK, M. C., WIRAHADIREDJA, R. M. S.: Feline infectious peritonitis (FIP) virus. II. Propagation in suckling mouse brain. *Zbl. Vet. Med. B* **25**, 301—307 (1978).
59. OSTERHAUS, A. D. M. E., HORZINEK, M. C., WIRAHADIREDJA, R. M. S.: Feline infectious peritonitis (FIP) virus. IV. Propagation of FIP virus in suckling rat and hamster brain. *Zbl. Vet. Med. B* (in press, 1978).
60. OTT, R. L., Feline infectious peritonitis. In: DRAWER, K. K., STA. BARBARA CAL., CATCOT, E. J. (eds.), *Feline Surgery and Medicine*, Second Ed., 47—54. Amer. Vet. Publ. Inc. 1975.
61. PARKER, J. C., COLLINS, M. J.: cited from WARD *et al.* (1974), ref. 78 (1971).
62. PEDERSEN, N. C.: Morphologic and physical characteristics of feline infectious peritonitis virus and its growth in autochthonous peritoneal cell cultures. *Amer. J. Vet. Res.* **37**, 567—572 (1976).
63. PEDERSEN, N. C.: Serologic studies of naturally occurring feline infectious peritonitis. *Amer. J. Vet. Res.* **37**, 1449—1453 (1976).
64. PEDERSEN, N. C.: Feline infectious peritonitis: something old, something new. *Fel. Pract.* **6**, 42—51 (1976).
65. PEDERSEN, N. C., HOLIDAY, T. A., CELLO, R. M.: Feline infectious peritonitis. *Proc. 41st. Ann. Meeting Am. Anim. Hosp. Assoc.* 147—153 (1974).
66. PEDERSEN, N. C., THEILEN, G., KEANNE, M. A., FAIRBANKS, L., MASON, T., ORSO, B., CHEN, C. H., ALLISON, C.: Studies on naturally transmitted feline leukemia virus infection. *Amer. J. Vet. Res.* **38**, 1523—1531 (1977).

67. PEDERSEN, N. C., WARD, J., MENGELING, W. L.: Antigenic relationship of the feline infectious peritonitis virus to coronaviruses of other species. *Arch. Virol.* **58**, 45—53 (1978).
68. POELMA, F. G., PETERS, J. C., MIEG, W. H. W., ZWART, P.: Infektiöse Peritonitis bei Karakal (*felis caracal*) und Nordluchs (*felis lynx lynx*). In: *Erkrankungen der Zootiere* (13. Int. Symp., Helsinki), 245—283 (1971).
69. PORTER, D. D., LARSEN, A. E., PORTER, H. G.: The pathogenesis of Aleutian disease of mink. I. *In vivo* viral replication and the host antibody response to viral antigen. *J. exp. Med.* **130**, 575—595 (1969).
70. POTKAY, S., BACHER, J. D., PITTS, T. W.: Feline infectious peritonitis in a closed breeding colony. *Lab. Anim. Sci.* **24**, 279—289 (1974).
71. REYNOLDS, D. J., GARWES, D. J., GASKELL, C. J.: Detection of transmissible gastroenteritis virus neutralizing antibody in cats. *Arch. Virol.* **55**, 77—86 (1977).
72. ROBISON, R. L., HOLZWORTH, J., GILMORE, C. E.: Naturally occurring feline infectious peritonitis: signs and clinical diagnosis. *J. Amer. Vet. Med. Ass.* **158**, 981—986 (1971).
73. RUBIN, L. F., POTE, J. L., CIMPRIK, R.: Clinico-pathological conference. *J. Amer. Vet. Med. Ass.* **164**, 630—634 (1974).
74. SLAUSON, D. D., FINN, J. P.: Meningoencephalitis and panophthalmitis in feline infectious peritonitis. *J. Amer. Vet. Med. Ass.* **160**, 729—734 (1972).
75. STÜNZI, H., GREVEL, V.: Die ansteckende fibrinöse Peritonitis der Katze. Vorläufige Mitteilung über die ersten spontanen Fälle in der Schweiz. *Schweiz. Arch. Tierheilk.* **115**, 579—586 (1973).
76. STURMAN, L. S.: Characterization of a coronavirus. I. Structural proteins: effect of preparative conditions on the migration of protein in polyacrylamide gels. *Virology* **77**, 637—649 (1977).
77. TRAAVIK, T., MEHL, R., KJELDSBERG, E.: "Runde" virus, a coronavirus-like agent associated with seabirds and ticks. *Arch. Virol.* **55**, 25—38 (1977).
78. TUCH, K., WITTE, K. H., WÜLLER, H.: Feststellung der feline infektiösen Peritonitis (FIP) bei Hauskatzen und Leoparden in Deutschland. *Zbl. Vet. Med. B* **21**, 426—441 (1974).
79. TYRRELL, D. A. J., ALMEIDA, J. D., CUNNINGHAM, C. H., DOWDLE, W. R., HOFSTAD, M. S., MCINTOSH, K., TAJIMA, M., ZASTELSKAYA, L. Y., EASTERDAY, B. C., KAPIKIAN, A., BINGHAM, R. W.: Coronaviridae. *Intervirology* **5**, 76—82 (1975).
80. WARD, J. M.: A study of the etiology and pathogenesis of feline infectious peritonitis. Ph. D. Thesis, Univ. of California, Davis, Calif., June 1970.
81. WARD, J. M.: Morphogenesis of a virus in cats with experimental feline infectious peritonitis. *Virology* **41**, 191—194 (1970).
82. WARD, B. C., PEDERSEN, N.: Infectious peritonitis in cats. *J. Amer. Vet. Med. Ass.* **154**, 26—35 (1969).
83. WARD, J. M., GRIBBLE, D. H., DUNGWORTH, D. L.: Feline infectious peritonitis: Experimental evidence for its multiphasic nature. *J. Amer. Vet. Res.* **35**, 1271 to 1275 (1974).
84. WARD, J. M., MUNN, R. J., GRIBBLE, D. H., DUNGWORTH, D. L.: An observation of feline infectious peritonitis. *Vet. Rec.* **83**, 416—417 (1968).
85. WARD, J. M., SMITH, R., SCHALM, O. W.: Inclusions in neutrophils of cats with feline infectious peritonitis. *J. Amer. vet. Med. Ass.* **158**, 348 (1971).
86. WIRAHADIREDDA, R. M. S., ANAKOTTA, J., OSTERHAUS, A. D. M. E.: Detection by immunofluorescence of transmissible gastroenteritis (TGE) viral antigen in pigs using cat anti feline infectious peritonitis (FIP) virus conjugate. *Zbl. Vet. Med. B.* (in press.)
87. WITTE, K. H., TUCH, K., DUBENKROPP, H., WALTHER, C.: Untersuchungen über die Antigenverwandtschaft der Viren der Feline infektiösen Peritonitis (FIP) und der transmissiblen Gastroenteritis (TGE) des Schweines. *Berl. Münch. Tierärztl. Wschr.* **80**, 396—401 (1977).
88. WOLFE, L. G., GRIESEMER, R. A.: Feline infectious peritonitis. *Path. Vet.* **3**, 225—270 (1966).

89. WOLFE, L. G., GRIESEMER, R. A.: Feline infectious peritonitis: Review of gross and histopathologic lesions. *J. Amer. Vet. Med. Ass.* **158**, 987—993 (1971).
90. ZOOK, B. C., KING, N. W., ROBISON, R. L., MCCOMBS, H. L.: Ultrastructural evidence for the viral etiology of feline infectious peritonitis. *Path. Vet.* **5**, 91—95 (1968).

Authors' address: Prof. Dr. M. C. HORZINEK, Institut voor Virologie, Faculteit der Diergeneeskunde, Rijksuniversiteit, Yalelaan 1, 3584 CL Utrecht, The Netherlands.

Received April 26, 1978