

*Erratum*

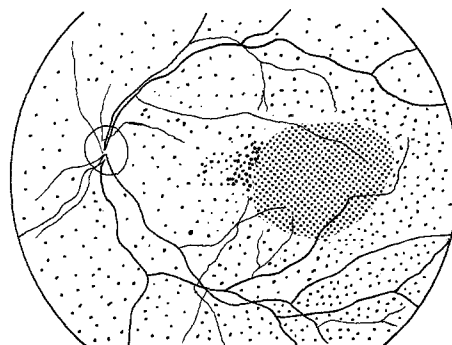
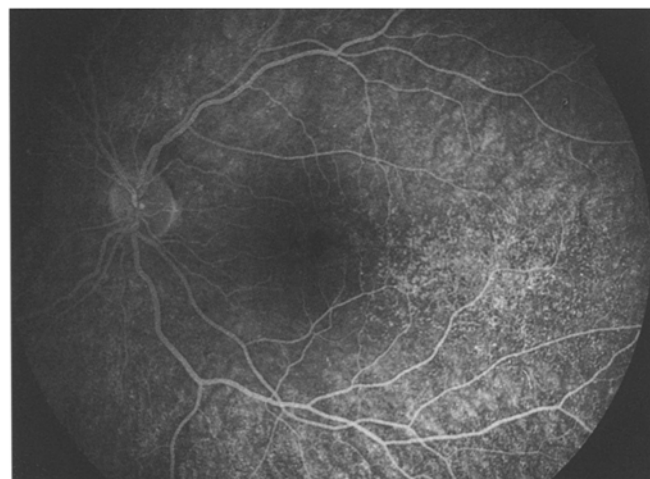
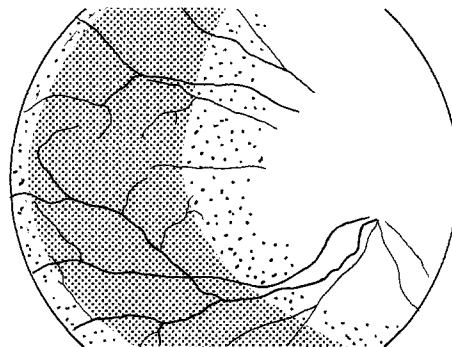
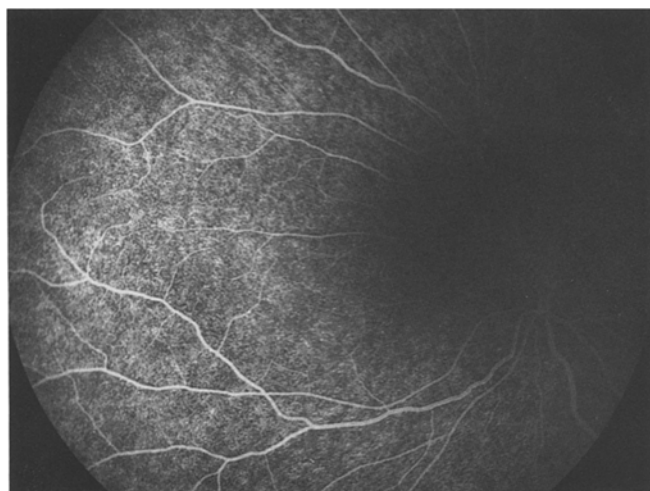
**Specific eye fundus lesions in type II  
membranoproliferative glomerulonephritis**

Anita Leys<sup>1</sup>, Willem Proesmans<sup>2</sup>, Rita Van Damme-Lombaerts<sup>2</sup>, and Boudewijn Van Damme<sup>3</sup>

Departments of <sup>1</sup> Ophthalmology, <sup>2</sup> Paediatrics, and <sup>3</sup> Pathology, University Hospital, Gasthuisberg, Herestraat, B-3000 Leuven, Belgium 1

Received June 15, 1990; received in revised form October 12, 1990; accepted November 16, 1990

Due to a technical error, the following line drawings were produced wrong-reading on page 190 of volume 5, issue 2, 1991. Please excuse this mistake.



**Fig. 1.** Patient 1. Fluorescein angiogram of the left eye, nasal (*top*) and macular view (*bottom*). Basal laminar drusen are randomly scattered, but are more closely arranged in the shaded parts