


Chapter 8

COVID-19: An Ophthalmological Update



Ankita, Apjit Kaur, and Shailendra K. Saxena 

Abstract Ever since the newscast of the novel coronavirus outbreak in Wuhan and its subsequent spread to several countries worldwide, the possible modes of spread are being anticipated by various health care professionals. Tear and other conjunctival secretions, being one of the body fluids, can potentially help transmit the disease inadvertently. Conjunctival secretions from patients and asymptomatic contacts of COVID-19 cases may also spread the disease further into the community. Direct inoculation of body fluids into the conjunctiva of healthy individual is also postulated to be another mode of spread. The risk to health care providers thus becomes strikingly high. A vigilant ophthalmologist can play a critical role in breaking the chain of transmission.

Keywords COVID-19 · Novel coronavirus · Conjunctivitis · SARS-CoV-2

Abbreviations

COVID-19	Coronavirus disease-19
SARS-CoV	Severe acute respiratory syndrome coronavirus
SARS-CoV-2	Severe acute respiratory syndrome coronavirus-2

Ankita and Shailendra K. Saxena contributed equally as first author.

Ankita · A. Kaur (✉)

Department of Ophthalmology, King George's Medical University (KGMU), Lucknow, India

S. K. Saxena

Centre for Advanced Research (CFAR)-Stem Cell/Cell Culture Unit, Faculty of Medicine, King George's Medical University (KGMU), Lucknow, India

e-mail: shailen@kgmcindia.edu

© The Editor(s) (if applicable) and The Author(s), under exclusive licence to Springer Nature Singapore Pte Ltd. 2020

S. K. Saxena (ed.), *Coronavirus Disease 2019 (COVID-19)*, Medical Virology: from Pathogenesis to Disease Control, https://doi.org/10.1007/978-981-15-4814-7_8

8.1 Introduction

The rapid increase in the reporting of patients suffering from COVID-19 has brought about a major health emergency worldwide. COVID-19 was declared a pandemic by the World Health Organization (WHO) on March 11, 2020 (WHO 2020a). According to the WHO pandemic phases, COVID-19 is currently in Phase 5, which signifies global human-to-human spread of the virus (WHO 2009).

Though the major symptoms are mainly respiratory in nature, ocular symptoms are generally overlooked by clinicians. The major routes of transmission are through respiratory droplets and direct contact (Lei et al. 2018; Minodier et al. 2015; Zumla et al. 2015; Otter et al. 2016). Gastrointestinal tract and body fluids, including tears, can have the SARS-CoV-2 and may participate in the active spread of COVID-19, though the exact role remains uncertain (WHO 2020b).

Li Wenliang, a Chinese ophthalmologist at Wuhan Central Hospital, Hubei, the whistleblower of the disease outbreak, allegedly contracted the disease while attending a glaucoma patient and later succumbed to the illness (Wenliang 2020). Thus, ophthalmologists, as health care professionals, are also exposed to the possible impacts of COVID-19.

8.2 Ophthalmological Manifestation of Viral Respiratory Diseases

8.2.1 *Spectrum of Presentation*

The conjunctival sac is anatomically connected to the nasal cavity through the nasolacrimal duct. Most of the upper respiratory tract infections harbor the organism in the nasal mucosa (Thomas 2020). Since most of the acute URTI have viral etiology, adenovirus being the commonest, the appearance of conjunctivitis in such cases is not uncommon (Epling 2010; Azari and Barney 2013). Conjunctivitis is speculated to be an allergic immune response to the virus (Solano and Czyn 2020).

Conjunctival congestion with watery discharge is more characteristic of a viral conjunctivitis (Rietveld et al. 2003). There is a wide spectrum of presentation of viral conjunctivitis ranging from pink eye to hemorrhagic conjunctivitis.

The disease readily spreads from person to person and has the possibility of becoming an epidemic. Although viral conjunctivitis is most often mild and goes away without treatment within 1–2 weeks, it may last 2 or more weeks if complications develop. Major complications associated are punctate keratitis with subepithelial infiltrates, bacterial superinfection, conjunctival scarring and symblepharon, severe dry eye, irregular astigmatism, corneal ulceration with persistent keratoconjunctivitis, corneal scarring, and chronic infection (Bialasiewicz 2007).

8.2.2 Previous Coronavirus Infections in the Eye

Severe acute respiratory syndrome (SARS), a global health crisis, in 2003, was a result of infection with coronavirus strain (SARS-CoV).

Middle East respiratory syndrome–related coronavirus (MERS-CoV), first identified in Saudi Arabia in 2012, was another coronavirus-borne disease (Centers for Disease Control and Prevention 2020a).

Most of the previously encountered coronavirus species (SARS-CoV and MERS-CoV infections) rarely cause ocular infections in humans (Li et al. 2006). However, few reports suggest the presence of conjunctivitis of varying severity in patients suffering with coronavirus infections in different parts of the world (Finger 2003).

The presence of coronavirus in tear and conjunctival scrapings was also reported in few studies.

8.2.3 Novel Coronavirus Infection (COVID-19) in the Eye

Following the recent novel coronavirus outbreak in China, the presence of novel coronavirus in tears and conjunctival secretions of patients with COVID-19 was evaluated. Though majority of patients who had been enrolled for the study did not present with conjunctivitis, one who did had the coronavirus in tear and conjunctival swab. Conjunctivitis reported was mild, with a watery discharge. The results concluded that tears and conjunctival secretions had coronavirus in patients with conjunctivitis, but was absent in those without conjunctivitis. This also raised an alarm among the treating ophthalmologists towards the possible spread of the virus through tears, along with other body fluids (Xia et al. 2020).

Another study in China reported conjunctivitis in 9 patients with COVID-19, out of 1099 (0.8%). Few reports also suggest that initial symptoms of COVID-19 was not conjunctivitis, but the possibility of virus spread through conjunctiva cannot be excluded (Wei-Jie et al. 2020; Wang et al. 2020; Huang et al. 2020). The replication of virus in conjunctival epithelium is also enigmatic.

In view of the presence of coronavirus in body fluids of patients, and SARS-CoV-2 being similar to SARS-CoV, the risk of transmission through conjunctival secretion and tear cannot be neglected.

8.3 Combating the Ocular Spread—Ophthalmologist’s Role Play

According to the recent American Academy of Ophthalmology (AAO) guidelines, there are multiple reports which suggest that the novel coronavirus can cause conjunctivitis and can also be transmitted by aerosol contact with conjunctiva.

Patients with conjunctivitis may initially report to an ophthalmologist, possibly making the eye care physician to first suspect a case of COVID-19 (Lu et al. 2020).

8.3.1 When to Suspect COVID-19 Conjunctivitis

- Ophthalmological intervention should depend upon the WHO pandemic phase in the concerned region (WHO 2009).
- In regions where community-level outbreak of COVID-19 is confirmed, every case of viral conjunctivitis with/without systemic symptoms should be considered as a probable case of COVID-19.
- In regions with impending community outbreak, every case of viral conjunctivitis with/without systemic symptoms should be suspected as a case of COVID-19.
- Confirmation of travel and contact history becomes less relevant in both the aforementioned scenarios.
- In regions with local spread, history of travel/contact/symptoms suggestive of COVID-19 should be enquired and cases belonging to group 2, 3, and 4 should be evaluated further.

8.3.2 Diagnosing and Managing COVID-19 Conjunctivitis

In regions with WHO pandemic phase >2 , ruling out common viral pathogens causing conjunctivitis becomes secondary. Excluding the novel pathogen in such scenarios is of primary importance as it can help in the detection of subclinical cases to limit further spread of the disease.

According to a recently published literature on COVID-19 conjunctivitis, tear sample and conjunctival swab are reported to be positive for the novel coronavirus. So tear sample and conjunctival secretions need to be evaluated for the presence of the virus. Collection should be done using disposable sampling swab from the conjunctival fornix, preferably lower. The sample should be stored in universal transport medium at 4 °C and sent for RT-PCR (real-time Polymerase Chain Reaction) assay. Two such samples should be taken within 2–3 days' interval and assay should be repeated.

The reported sensitivity and specificity of RT-PCR are 85–87% and 100%, respectively, for diagnosing previous SARS-CoV infection. Recent data on the sensitivity and specificity of RT-PCR for novel coronavirus infection is not available. The treatment of COVID-19 conjunctivitis is an ongoing research (National Institutes of Health 2020). It might have a benign course, as cases reported are mild, and may be treated as normal viral conjunctivitis treatment protocol as of now.

8.4 Risk to Ophthalmologists

The transmission of COVID-19 can occur through the mucous membranes, including the conjunctiva. Thus, the treating ophthalmologist may be equally or potentially exposed to the health hazard. Several case reports have documented the spread of COVID-19 to ophthalmologists during routine diagnosis and treatment (Wang et al. 2020; Dai 2020; South China Morning Post 2020). Also, transmission of the disease through asymptomatic contacts has also been documented (Rothe et al. 2020).

Most of the ophthalmological diagnostic procedures (slit lamp examination, direct and indirect fundus examinations, tonometry, etc.) require close proximity with patients, thereby increasing the risk of exposure (Xia et al. 2020). Suboptimal infection control strategies at the health care level may unintentionally spread the disease and risk the entire community (Chan et al. 2006).

8.5 Preventive Measures in Ophthalmic Practice

According to the WHO cases classification schemes, patients can be grouped on the basis of triage system into general, suspect, and probable categories (World Health Organization 2003; Gavidia 2020). All patients should not attend the outpatient clinic to avoid personal and community spread of the disease. Triage should be performed and patients should be screened on the basis of:

- Travel history in the last 2–3 weeks to any of the hot spots of COVID infections (China, South Korea, Italy, Iran, etc.)
- History of contact with known COVID-19 patient/suspect
- Symptoms of cough, cold, or fever

Patients are categorized into four groups according to the triage system (Fig. 8.1). Groups 1 and 2 can be categorized as general patients and can be seen on an outpatient basis, but with personal protective equipment (PPE). Groups 3 and 4 should be characterized as suspect/probable cases and only cases having ophthalmic urgency should be managed, in isolation ward with full protection. Rest non-urgent ophthalmic appointments should be rescheduled after 2 weeks (Fig. 8.2). Figure 8.2 highlights the protocol for attending patients visiting ophthalmology clinics during COVID-19 outbreak (Huang et al. 2020; Rohit and Santosh 2020).

8.5.1 Outpatient Care

As per recent AAO guidelines, as a response to the state of national emergency due to COVID-19, eye care practitioners should reduce the number of outpatient

Groups	Patient presentation
1	Otherwise healthy patients with no travel/contact history in the last 2-3 weeks.
2	Patients appearing healthy but with recent contact/travel history, quarantined and declared unaffected.
3	Patients appearing healthy but with recent contact/travel history, not quarantined.
4	Patients with obvious signs of respiratory illness (cough, fever)

Fig. 8.1 Triage of patients presenting to ophthalmology clinic

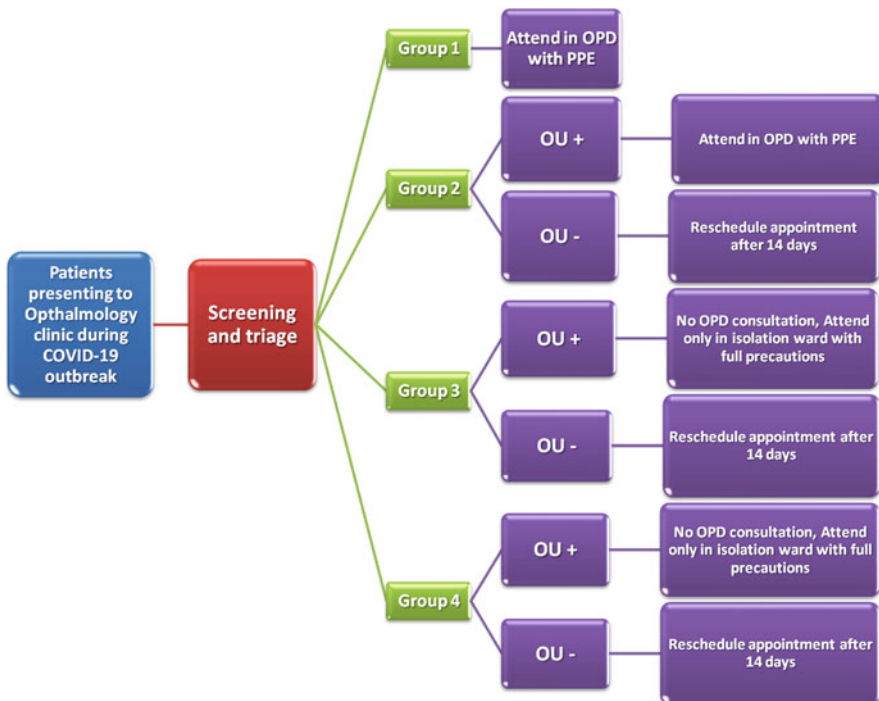


Fig. 8.2 Flow chart of attending patients visiting ophthalmology clinic. *OPD* outpatient department, *PPE* personal protective equipment, *OU* ophthalmic urgency

consultation days and elective surgical procedures, particularly in elderly patients and those with medical comorbidities (American Academy of Ophthalmology 2020).

The following preventive measures should be taken by the ophthalmologist in the outpatient clinic for general patients (Group 1 and 2) during such outbreaks:

8.5.1.1 Personal protection

Personal protective equipment (PPE) (Table 8.1) and general precautionary measures to be taken for outpatient procedures include

- Universal precaution:
 - Surgical/N95 respirator mask to cover the nose and mouth.
 - Gloves whenever body fluids (blood, secretions, urine, stool) are to be handled.
 - Water-repellant or water-resistant gowns.
 - Eye protective wear or goggles (visor).
- Hand sanitization:
 - Repeated hand washing, using hand rub (0.5–1.0% chlorhexidine in 80% ethyl alcohol).
- Gloves to be changed and hand hygiene practiced between each contact with different patients.
- Avoidance of touching of face shields, mask, eye protective wear, face, head, and neck area before thorough hand wash.

Table 8.1 Personal protective instrument to be used by health care practitioners for attending general and high-risk patients of COVID-19

Disposable wear/ protective measures	General patients (for outpatient care) (Group 1)	High-risk patients (for outpatient care and isolation wards) (Group 2, 3, and 4)
Cap	Standard	Standard
Eye protective wear	Visor or goggles	Face shield
Mask	Surgical mask	N95 respirator
Gown	Water repellent/water- resistant gowns	Water repellent/Barrier [®] surgical gown
Hand hygiene	Hand washing or alcohol-rub between patients	Glove
Shoe cover	Standard	Standard

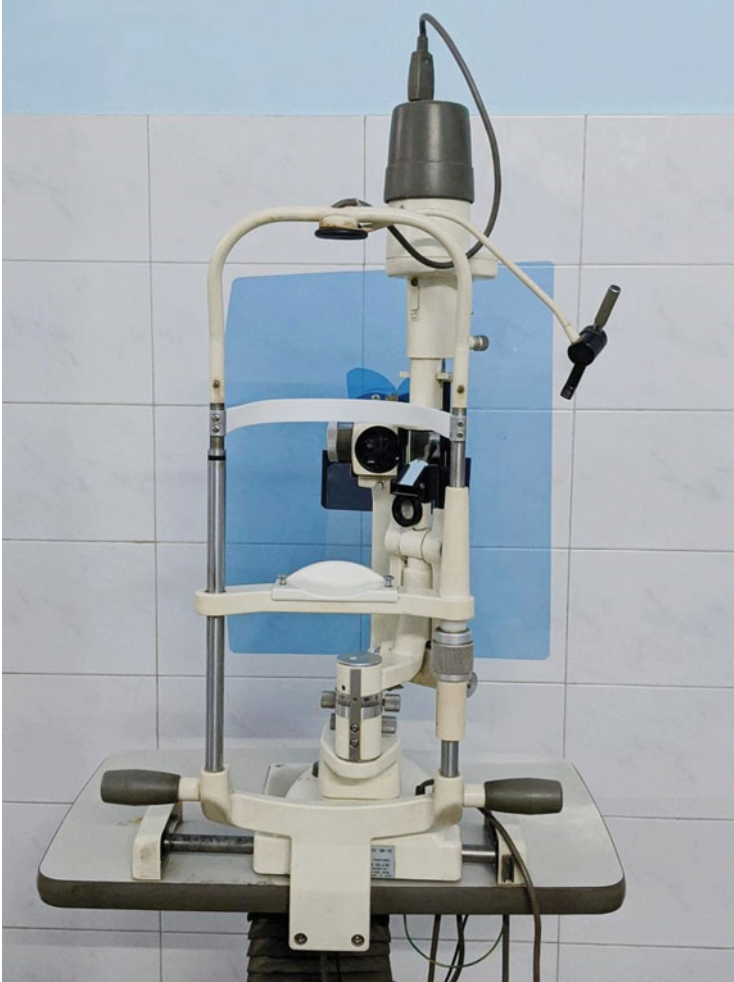

Fig. 8.3 Custom-made slit lamp breath shields

8.5.1.2 Examination Equipment Sterilization

- Slit lamps should accompany barriers or breath shields (Fig. 8.3).
- Applanation tonometry to be performed using Tonopen with a disposable sleeve. For Goldmann applanation tonometry, the prism tip must be sterilized between cases with alcohol swabs or bleach solution 1:10 as recommended. The prism tip should be immersed in bleach for at least 15 min.
- Ultrasonography probe to be sterilized with alcohol swab after every use.
- Scleral indentation for indirect ophthalmoscopy should be performed with disposable cotton swab stick.

- Direct ophthalmoscopy should be avoided, instead one should use slit lamp with breath shields and a non-contact lens for fundus evaluation.
- All ophthalmic instruments should be disinfected using diluted household bleach, alcohol solutions containing minimum of 70% alcohol, common EPA-registered household disinfectants including Clorox brand products, Lysol brand products, and Purell professional surface disinfectant wipes.

8.5.1.3 Consultation Room Hygiene and Ventilation

- Keep doors open in the clinic rooms to avoid handling of the door knobs and to maintain ventilation.
- Restriction of visitors in hospital premises unless under exceptional circumstances such as disabled patients or children.

For a patient who is suspected (or probable) to have COVID-19, the following measures should be taken in treatment by the ophthalmologist:

- For known cases of COVID-19, attending the patient on an outpatient basis is contraindicated due to high risk of cross infection. All consultations should be done inside quarantine or isolation wards.
- Any ophthalmic consultation should be deferred in a case suspected to have COVID-19, till the infective status of the patient is confirmed.

8.5.2 Inpatient Care

- For attending patients in isolation ward, personal protective equipment should be used as advised for high-risk cases.
- Disposable protective wear should be discarded separately, without touching any part of the skin/face.

8.5.3 Operation Theater (OT)

- Only urgent ophthalmic procedures like acute angle closure glaucoma, rhegmatogenous retinal detachment with macula on, traumatic rupture of the eye, and intraocular foreign body to be operated (South China Morning Post 2020).
- All other elective surgeries to be deferred till crisis subsides.
- Operating surgeon to be prepared with full precautions—SMS surgical gowns, shoe legging, face mask, surgeon cap, gloves, N95 mask.

- Removal of gown—special care to be taken in order to prevent outer surface from touching any part of the skin.
- Separate collection bag for waste generated and disposables used during surgery.
- High-level disinfection practice for cleaning of operating room (Rutala et al. 1993; Centers for Disease Control and Prevention 2020b).
 - Laminar air flow to be maintained in the room.
 - Operating microscope—disinfection with 2% glutaraldehyde.
 - Instrument sterilization—disinfection with 2% glutaraldehyde, sterilization using ethylene oxide (ETO) for moisture and heat-sensitive instruments, hydrogen peroxide plasma sterilization for all other surgical instruments.
 - Operation room fumigation with 5% formaldehyde.
- No noninfected cases to be operated in the same OT on the same day under any circumstances.

8.5.4 Management in Case of Accidental Exposure

In case of accidental exposure to any body fluid of the infected patient, eyes should be thoroughly washed with running water and the skin area should be properly cleaned with at least 70% ethyl alcohol-based cleaning solution for at least 20 s. The person should be kept under quarantine till 2 weeks (Centers for Disease Control and Prevention 2020c). Meanwhile, nasopharyngeal sampling should be done regardless of the symptoms because developing the disease is almost inevitable in such cases (Centers for Disease Control and Prevention 2020c; Lauer et al. 2020). Symptomatic and supportive treatment should be given in those developing COVID-19. Postexposure prophylaxis is not yet available.

8.5.5 Economically Weaker Countries

Aforementioned precautions should be practiced in such places also. But due to the paucity of resources, the demands are mostly unmet.

In such scenarios, OPD consultation of any ophthalmological complaint should be withheld till the status of infection turns out negative. Isolation ward, however, if urgent, should be attended with full precautions. Any alternative to the standard precautionary measures may not be helpful in preventing infections. Self-quarantine should be done by the suspect patient or health care provider for at least 2 weeks duration.

8.6 Conclusions

Ophthalmologists can play a key role in outbreak detection, surveillance, and early response to COVID-19. Unawareness at the eye care level may result in mass infections among health care providers and patients.

8.7 Future Perspectives

The outbreak of COVID-19 has brought out the stark inadequacies of the health care system at various levels, specially the primary and secondary care. It is high time the policy makers should take initiatives to strengthen primary and secondary health care and increase investment in health, including ophthalmic care sector.

Previous studies had warned about a possible severe coronavirus pandemic, similar to SARS and MERS in near future. In order to fight forthcoming similar illnesses, proper sanitization and disinfection practices should be incorporated on a daily basis, by both doctors and people in the community. Situational awareness and adequate training should be given to health care providers of all specialties to combat outbreak of new infectious diseases. Early preventive measures should be undertaken to prevent pandemics. Cooperation among both public and private hospital setups is crucial for management.

Highlights

- Early identification of COVID-19 can be done by a vigilant ophthalmologist, reducing risk of further human-to-human transmission.
- Conjunctivitis can be the first symptom of COVID-19 in patients with positive travel/contact history.
- SARS-CoV-2 is present in patients with COVID-19 conjunctivitis.
- High risk of transmission is present through direct inoculation into conjunctiva.
- Patients having no respiratory symptoms except COVID-19 conjunctivitis are also infectious.

Acknowledgments The authors are grateful to the Vice Chancellor, King George's Medical University (KGMU), Lucknow, India, for the encouragement of this work. The authors have no other relevant affiliations or financial involvement with any organization or entity with a financial interest in or financial conflict with the subject matter or materials discussed in the manuscript apart from those disclosed.

Conflicts of interest: None.

References

- American Academy of Ophthalmology (2020) Alert: important coronavirus updates for ophthalmologists. American Academy of Ophthalmology. [cited 2020 Mar 19]. <https://www.aaopt.org/headline/alert-important-coronavirus-context>
- Azari A, Barney N (2013) Conjunctivitis. *JAMA* 310(16):1721–1729
- Bialasiewicz A (2007) Adenoviral keratoconjunctivitis. *Sultan Qaboos Univ Med J* 7(1):15–23. [cited 2020Mar19]. <https://www.ncbi.nlm.nih.gov/pmc/articles/PMC3086413/>
- Centers for Disease Control and Prevention (2020a) About MERS. Centers for Disease Control and Prevention. [cited 11 March 2020]. <https://www.cdc.gov/coronavirus/mers/about/index.html>
- Centers for Disease Control and Prevention (2020b) Division of Healthcare Quality Promotion (DHQP). Centers for Disease Control and Prevention. [cited 2020 Mar 19]. <https://www.cdc.gov/nceizid/dhqp/index.html>
- Centers for Disease Control and Prevention (2020c) Clinical specimens: novel coronavirus (2019-nCoV). Centers for Disease Control and Prevention. 2020 [cited 2020 Mar 19]. <https://www.cdc.gov/coronavirus/2019-nCoV/lab/guidelines-clinical-specimens.html>
- Chan W-M, Liu DTL, Chan PKS, Chong KKL, Yuen KSC, Chiu TYH et al (2006) Precautions in ophthalmic practice in a hospital with a major acute SARS outbreak: an experience from Hong Kong. *Eye* 20:283–289. <https://doi.org/10.1038/sj.eye.6701885>
- Dai X (2020) Peking University Hospital Wang Guangfa disclosed treatment status on Weibo and suspected infection without wearing goggles. <http://www.bjnews.com.cn/news/2020/01/23/678189.html>. Accessed 23 Jan 2020
- Epling J (2010) Bacterial conjunctivitis. *BMJ Clin Evid*. 0704:21. <https://www.ncbi.nlm.nih.gov/pmc/articles/PMC2907624/#>
- Finger C (2003) Brazil faces worst outbreak of conjunctivitis in 20 years. *Lancet* 361(9370):1714. [cited 2020 Mar 19]. <https://www.ncbi.nlm.nih.gov/pubmed/12767749>
- Gavidia M (2020) American Academy of Ophthalmology issues coronavirus guidelines. *AJMC*. [cited 2020 Mar 11]. <https://www.ajmc.com/newsroom/american-academy-of-ophthalmology-issues-coronavirus-guidelines>
- Huang C, Wang Y, Li X, Ren L, Zhao J, Hu Y, Zhang L et al (2020) Clinical features of patients infected with 2019 novel coronavirus in Wuhan, China. *Lancet* 395(10223):497–506. [https://doi.org/10.1016/S0140-6736\(20\)30183-5](https://doi.org/10.1016/S0140-6736(20)30183-5)
- Lauer SA, Grantz KH, Bi Q, Jones FK, Zheng Q, Meredith HR, et al (2020) The incubation period of coronavirus disease 2019 (COVID-19) from publicly reported confirmed cases: estimation and application. *Ann Intern Med*. [cited 2020 Mar 19]. <https://annals.org/aim/fullarticle/2762808/incubation-period-coronavirus-disease-2019-covid-19-from-publicly-reported>
- Lei H, Li Y, Xiao S, Lin C, Norris S, Wei D et al (2018) Routes of transmission of influenza A H1N1, SARS CoV, and norovirus in air cabin: comparative analyses. *Indoor Air* 28(3):394–403
- Li W, Wong S, Li F, Kuhn J, Huang I, Choe H et al (2006) Animal origins of the severe acute respiratory syndrome coronavirus: insight from ACE2-S-protein interactions. *J Virol* 80(9):4211–4219. <https://doi.org/10.1128/JVI.80.9.4211-4219.2006>
- Lu C, Liu X, Jia Z (2020) 2019-nCoV transmission through the ocular surface must not be ignored. *Lancet* 395(10224):39. [https://doi.org/10.1016/S0140-6736\(20\)30313-5](https://doi.org/10.1016/S0140-6736(20)30313-5)
- Minodier L, Charrel R, Ceccaldi P, van der Werf S, Blanchon T, Hanslik T et al (2015) Prevalence of gastrointestinal symptoms in patients with influenza, clinical significance, and pathophysiology of human influenza viruses in faecal samples: what do we know? *Virol J* 12(1)
- National Institutes of Health (2020) Coronavirus disease 2019 (COVID-19). U.S. Department of Health and Human Services. [cited 2020 Mar 19]. <https://www.nih.gov/health-information/coronavirus>
- Otter J, Donskey C, Yezli S, Douthwaite S, Goldenberg S, Weber D (2016) Transmission of SARS and MERS coronaviruses and influenza virus in healthcare settings: the possible role of dry surface contamination. *J Hosp Infect* 92(3):235–250

- Rietveld R, Van Weert H, ter Riet G, Bindels P (2003) Diagnostic impact of signs and symptoms in acute infectious conjunctivitis. *BMJ* 327(7418):789
- Rohit CK, Santosh GH (2020) All eyes on coronavirus—what do we need to know as ophthalmologists. *Indian J Ophthalmol* 68:549–553
- Rothe C, Schunk M, Sothmann P, Bretzel G, Froeschl G, Wallrauch C et al (2020) Transmission of 2019-nCoV infection from an asymptomatic contact in Germany. *N Engl J Med* 382(10):970–971. <https://doi.org/10.1056/NEJMc2001468>. Epub 2020 Jan 30
- Rutala WA, Gergen MF, Weber DJ (1993) Evaluation of a rapid readout biological indicator for flash sterilization with three biological indicators and three chemical indicators. *Infect Control Hosp Epidemiol* 14(7):390–394. U.S. National Library of Medicine. [cited 2020 Mar 19]. <https://www.ncbi.nlm.nih.gov/pubmed/8354870>
- Solano D, Czyn CN (2020) Viral conjunctivitis. [Updated 2020 Feb 5]. In: StatPearls. StatPearls Publishing, Treasure Island, FL. <https://www.ncbi.nlm.nih.gov/books/NBK470271/#>
- South China Morning Post (2020) Chinese expert thinks he contracted coronavirus through his eyeballs. *South China Morning Post*. [cited 2020 Mar 19]. <https://www.scmp.com/news/china/article/3047394/chinese-expert-who-came-down-wuhan-coronavirus-after-saying-it-was>
- Thomas M (2020) Upper respiratory tract infection. StatPearls. U.S. National Library of Medicine. [cited 2020 Mar 19]. <https://www.ncbi.nlm.nih.gov/books/NBK532961/>
- Wang D, Hu B, Hu C, Fangfang Z, Xing L, Jing Z et al (2020) Clinical characteristics of 138 hospitalized patients with 2019 novel coronavirus–infected pneumonia in Wuhan, China. *JAMA* 323(11):1061–1069. <https://doi.org/10.1001/jama.2020.1585>
- Wei-Jie G, Zheng-Yi N, Yu H, Wen L, Chun-Quan O, Jian-Xing H et al (2020) Clinical characteristics of coronavirus disease 2019 in China. *N Engl J Med*. <https://doi.org/10.1056/NEJMoa2002032>
- Wenliang L (2020) *En.wikipedia.org*. [cited 19 March 2020]. https://en.wikipedia.org/wiki/Li_Wenliang
- WHO (2009) Pandemic influenza preparedness and response: a WHO guidance document. World Health Organization, Geneva. 4, The WHO pandemic phases. <https://www.ncbi.nlm.nih.gov/books/NBK143061/>
- WHO (2020a) Director-General’s opening remarks at the media briefing on COVID-19, 11 March 2020. *Who.int*. 2020 [cited 19 March 2020]. <https://www.who.int/dg/speeches/detail/who-director-general-s-opening-remarks-at-the-media-briefing-on-covid-19%2D%2D11-march-2020>
- WHO (2020b) Update 27—one month into the global SARS outbreak: status of the outbreak and lessons for the immediate future. *Who.int*. 2020 [cited 19 March 2020]. https://www.who.int/csr/sars/archive/2003_04_11/en/
- World Health Organization (2003) Case definitions for surveillance of severe acute respiratory syndrome (SARS) May 1, 2003. <http://www.who.int/csr/sars/casedefinition>
- Xia J, Tong J, Liu M, Shen Y, Guo D (2020) Evaluation of coronavirus in tears and conjunctival secretions of patients with SARS-CoV-2 infection. *J Med Virol*. <https://doi.org/10.1002/jmv.25725>
- Zumla A, Hui D, Perlman S (2015) Middle East respiratory syndrome. *Lancet* 386(9997):995–1007