

70.1 Introduction

Physical appearance is of much significance to the humans, as the human mind perceives the slightest form of deviation from normal form, function, and symmetry of the body and especially of the face as it is easily discernible [1]. Facial asymmetry could be defined as a clinically perceptible and significant difference between the two halves of the face. Every individual has some degree of asymmetry which may provide a uniqueness to the face. However, the magnitude and acceptability of the same depend on the location of the asymmetry and the patient's perception of disproportion. Facial asymmetry may also adversely affect the patient's nutritional and psychosocial development [2].

Any abnormality of the soft or hard tissues can lead to asymmetry. This could be a consequence of a congenital anomaly, a developmental, or an acquired defect. Asymmetry can be progressive in nature, while those acquired due to trauma or ablative surgeries are non-progressive [2, 3]. It is prudent for the clinician to consider the aetiology of the asymmetry, the extent, and its severity in all three dimensions in order to provide an optimal treatment plan. Besides, it is important to take into consideration factors such as growth, timing of treatment, and psychological aspirations of the patients when deciding the treatment plan [3, 4].

The present chapter will discuss the etiopathogenesis and classifications, clinical considerations, and diagnosis, evaluation, and treatment planning of facial asymmetries. Few interesting case scenarios will also be discussed for a better understanding of clinical presentations and their management.

70.2 Classification

Understanding the etiopathogenesis and classification of facial asymmetry allows for accurate diagnosis, optimal treatment planning, and improved surgical outcomes. Facial asymmetries are most commonly classified according to aetiology or morphology. Other classifications are based on time of onset, structures involved, and surgical planning outcomes and may even be restricted to the mandible alone. Table 70.1 is a summary of the various classification systems available to us today [5–19].

We have identified three classifications that are essential for the evaluation and treatment planning of facial asymmetries [Table 70.2 by Cheong et al. (2011) [13], Table 70.3 by Wolford et al. in (2009) [11], Table 70.4 by Wolford et al. (2014) [2, 19–21]].

70.3 Diagnostic Evaluation

Facial asymmetry is usually the least at the cranial base level and increases toward the lower levels of the face, with the mandible and chin commonly exhibiting the greatest asymmetry. Hence, the cranial base is used as a reference plane for assessing the type and severity of the asymmetry in the middle and lower thirds of the face. Conditions where the cranial base is also involved like syndromic or non-syndromic craniosynostosis, tumors of the cranium, and midface and Tessier's craniofacial clefts cannot be assessed in a routine manner. The presence of orbital dystopia, unequal pupillary heights, and/or unequal ear heights will make the assessment more challenging [2, 20, 22, 23].

Every clinical examination begins with identifying the chief complaint of the patient followed by a detailed physical and medical evaluation of the patient. In order to better understand the facial asymmetry, it is studied in the sagittal, coronal, and vertical dimensions with the cranial base as the reference plane. Common facial planes that represent the

N. N. Andrade (✉) · P. Mathai · N. Aggarwal
Department of OMFS, Nair Hospital Dental College, Mumbai
Central, Mumbai, India

Table 70.1 Summary of the various classification systems

Author	Based on	Classification subsets
Pirttiniemi, 1994 [5]	Time of onset	Pre-natal [further divided into embryonal and fetal] and post-natal
Bishara, 1994 [6]	Structures	Dental, skeletal, muscular, functional, and combination
Lundstrom, 1961 [7]	Etiology	Genetic, non-genetic, and combination
Plint, 1974 [8]	Etiology	Laterocclusion [apparent asymmetry due to occlusal disharmony] and laterognathism [true facial asymmetry]
Chia, 2008 [9]	Etiology	Pathological, functional, traumatic, and developmental
Haraguchi, 2008 [10]	Etiology	Hereditary factors of pre-natal origin and acquired factors of post-natal origin
Wolford, 2009 [11]	Etiology	Pseudo-asymmetry, normal facial asymmetry [non-pathologic], unilateral overdevelopment, and unilateral underdevelopment
Reyeneke, 2010 [12]	Etiology	Congenital, developmental, post-traumatic, and pathology-related
Cheong, 2011 [13]	Etiology	Congenital [pre-natal origin], acquired [injury or disease], and developmental [unknown origin]
Waite, 2012 [4]	Etiology	Congenital [malformation, deformities, and disruptions], developmental [primary and secondary growth deformities], acquired [trauma and pathology], and idiopathic
Obwegeser, 1986 [mandible only] [15]	Morphology	Hemi-mandibular elongation, Hemi-mandibular hyperplasia, combined/hybrid forms
Cohen, 1995 [16]	Morphology	Hemi-hyperplasia [hemifacial hypertrophy], Hemi-hypoplasia [hemifacial microsomia], Hemi-atrophy [Parry Romberg syndrome], and miscellaneous entities [hemi-maxillofacial dysplasia]
Kim, 2014 [mandible only] [17]	Morphology centric surgical outcome	TML system for optimal surgical planning in mandibular prognathism cases only: menton deviation with transverse asymmetry [T], maxillary cant [M], and lip cant [L]
Hwang, 2007 [mandible only] [8]	Morphology	Based on deviation of the chin and bilateral difference between mandibular rami length
Wolford, 2014 [mandible only] [19]	Morphology, imaging, etiology, histology	Restricted to condylar hyperplasia [CH] only: Type 1 CH [prolonged accelerated growth], Type 2 CH [osteochondroma], Type 3 CH [benign tumors other than osteochondroma], and Type 4 CH [malignant tumors]

Table 70.2 Major etiological factors of facial asymmetry, according to Cheong et al. (2011) [13]

Congenital factors	Acquired factors	Developmental factors
Cleft land cleft palate	TMJ ankylosis	Unknown cause
Tessier's clefts	Facial trauma	
Hemifacial Microsomia	Children's radiotherapy	
Neurofibromatosis	Fibrous dysplasia	
Congenital muscular torticollis	Facial tumors	
Craniosynostoses	Unilateral condylar hyperplasia	
Vascular disorders	Parry Romberg syndrome	
Others	Others	

cranial base are the pupillary plane, the ear plane, and the clinical Frankfort horizontal plane. It is also important to note that patients may hold the head in an abnormal position or use hairstyles and mannerisms to mask the extent of the asymmetry [e.g., a patient with a deficient mandible may tip his head upward in order to improve chin projection]. It is important to identify these compensatory mechanisms during the treatment planning process. Similarly, it can be beneficial to study the lower or middle third individually in comparison with the unaffected upper third [cranial base] by blocking out the part not being studied with an opaque sheet [e.g., card board] [20, 23].

70.3.1 Clinical Evaluation: Frontal, Axial, and Profile

Frontal View

The patient's head is positioned such that the interpupillary plane or ear plane [passing through the bottom of the ear lobes or tragi of the ears] is parallel to the floor. The pupillary plane can also be used for assessing bilateral vertical discrepancies by measuring height differences from the plane to the mandibular angles, chin, nose, and commissures (Fig. 70.1). The facial midline is represented by a vertical plane passing through the nasion or glabella, perpendicular to the pupillary plane and ear plane (Fig. 70.2). It allows to compare the degree of left-to-right asymmetry and transverse facial width discrepancies of various facial structures [e.g., orbits, pupils, malar eminences, nose, commissures, and mandibular angles]. In case of some imbalance in the frontonasal region [e.g., past naso-orbito-ethmoidal trauma], other landmarks can also be used as a reference to identify the facial midline, e.g., half the interpupillary or inter-canthal distance, the subnasal point, or the philtrum [20, 22].

Table 70.3 Wolford's classification of facial asymmetry 2009 [11]

Pseudo-asymmetry	Normal facial asymmetry	Unilateral	
		Overdevelopment	Underdevelopment
Occlusal interferences	Genetics	Condylar hyperplasia / Mandibular hyperplasia/Deviant prognathism	Acquired: trauma, infection, TMJ ankylosis, and iatrogenicities [due to tumor resection, radiation, unstable orthognathic procedures and adverse surgical events], failed TMJ alloplastic implants, and failed autogenous tissue grafts
Neuromuscular dysfunction	Intrauterine moulding	Osteochondroma/osteoma	
Habitual posturing	Natural growth variance	Unilateral muscle hyperplasia [masseteric muscle hypertrophy]	
Condylar dislocation		Other benign/malignant tumors	Congenital deformities [unilateral cleft lip and palate, hemifacial microsomia, and Treacher Collins syndrome]
Temporary unilateral facial swelling due to trauma/infection		Neuromuscular disorders [facial nerve trauma, Bell's palsy, Ramsey-Hunt syndrome, Mobius syndrome, mastoid infections, and cerebral vascular accidents affecting the facial nerve]	
			Adolescent idiopathic condylar resorption
			TMJ reactive [inflammatory] arthritis
			Connective tissue and autoimmune diseases

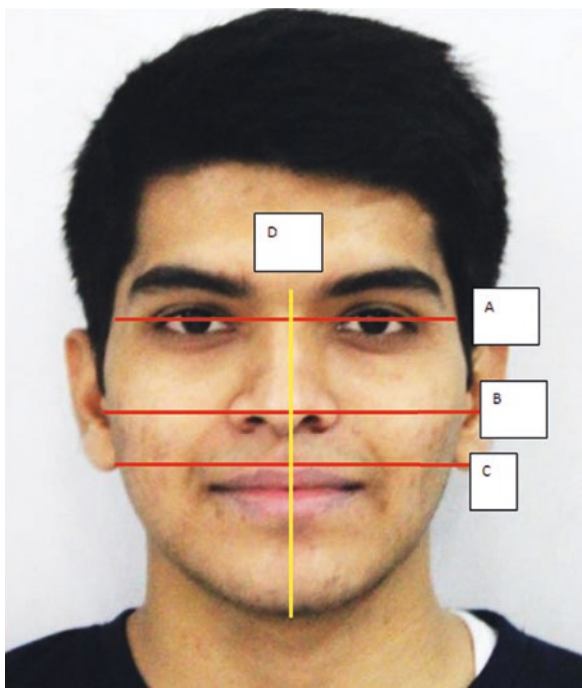
Table 70.4 Wolford's classification of condylar hyperplasia [CH] 2014 [2, 19–21]

CH type	Age at onset	Clinical findings	Imaging	Histology
CH Type 1 [similar to hemi-mandibular elongation]: Type 1A and Type 1B	Puberty	Type 1A Bilateral [BL] or Type 1B Unilateral [UL] accelerated growth; self-limiting; Class 3 occlusion; prognathic mandible	UL/BL elongated condylar head, neck and body; normal condylar head shape	Normally growing condyle; may show chondrocyte proliferation during initial and active phases, with normal bone after growth ceases
CH Type 2 [similar to hemi-mandibular hyperplasia]: Type 2A and Type 2B	Two-thirds of cases begin in 2nd decade	UL vertical elongation of face and jaws; non-self-limiting; ipsilateral posterior open bite; occlusal cant occasionally	Unilateral vertical enlarged condylar head, neck, ramus and body; Type 2A: Enlargement without horizontal exophytic growth of the condyle; Type 2B: enlargement with exophytic growth of the condyle	Osteochondroma; cartilaginous cap similar to that seen in a normal growth cartilage; endochondral ossification; cartilaginous islands in the sub-cortical bone; thickened irregular bony trabeculae
CH Type 3	No specific age	UL facial enlargement	Varies from normal anatomy of condyle; usually presenting as condylar enlargement	Benign tumors, e.g., osteoma, neurofibroma, giant cell tumor, fibrous dysplasia, chondroma, chondroblastoma, and arterio-venous malformation
CH Type 4	No specific age	UL facial enlargement	Varies from normal anatomy of condyle; usually presenting as condylar enlargement with lytic lesions	Malignant tumors, e.g., chondrosarcoma, multiple myeloma, osteosarcoma, metastatic lesion, and Ewing's sarcoma

The patient should be reminded to relax the peri-oral musculature for assessing the tooth to upper lip relation at rest [e.g., patients with vertical maxillary excess will constantly purse their lips to reduce excessive gum and teeth show]. The smile needs to be assessed for the amount of gingival show on either side, tooth to upper lip relation, comparison of dental midline with facial midline and symmetry by comparing parallelism of commissural and pupillary lines. Finally, a tongue blade or thin ruler can be placed between the maxillary and mandibular canines and premo-

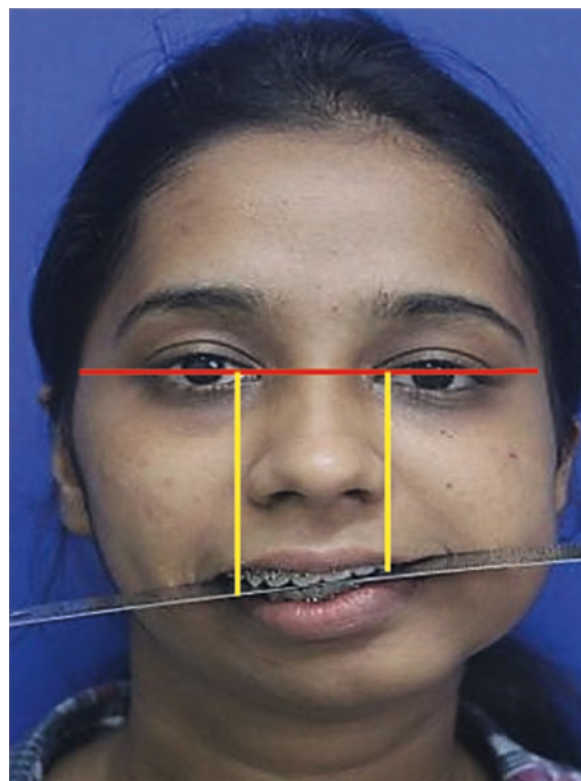
lars to assess the presence of a cant in relation to the pupillary plane (Fig. 70.2). Comparing the vertical heights from the pupillary plane to the canine tips on either side can help quantify the cant. An occlusal plane inclination of greater than 4° is said to cause significant perceptible asymmetry.

Assessment of midline structures such as nasal bridge, nasal tip, philtrum, and the chin point should also be carried out. Submental [worm's-eye] (Fig. 70.3) and superior [bird's-eye] views (Fig. 70.4) are very useful in assessing deviation of the abovementioned structures. We can also assess symmetry



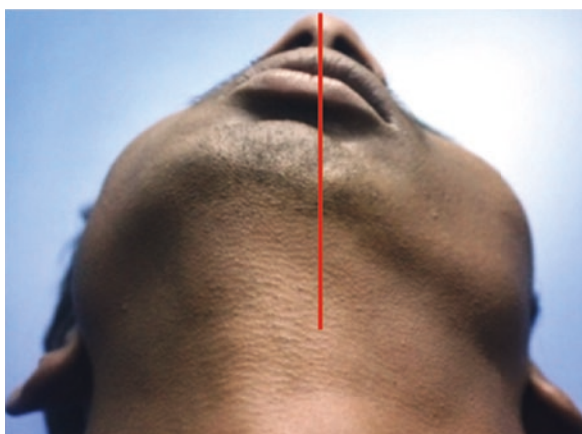©Association of Oral and Maxillofacial Surgeons of India

Fig. 70.1 Various facial planes **A** horizontal plane (interpupillary plane) **B** horizontal plane (inter tragal plane) **C** horizontal plane (plane marked through ear lobes) **D** vertical plane (mid-sagittal plane)



©Association of Oral and Maxillofacial Surgeons of India

Fig. 70.2 Occlusal cant in relation to the pupillary plane and asymmetry marked from medial canthi to the oral commissure



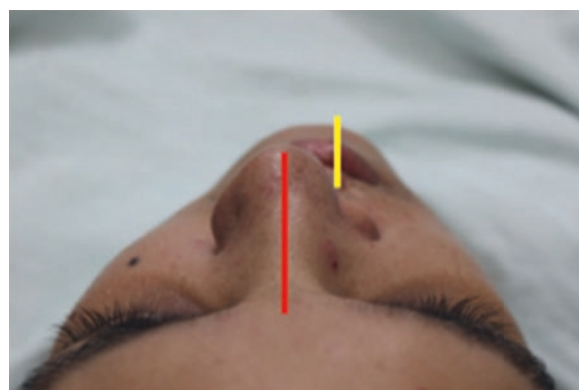
©Association of Oral and Maxillofacial Surgeons of India

Fig. 70.3 Submental (worm's-eye) view exhibiting asymmetry in the lower facial third and skeletal midline

and projection of the anterior cranial vault, orbital areas, nose, cheeks, malar eminences, and mandibular body contours.

Profile View

In order to avoid underestimating the severity of the facial asymmetry due to compensatory head postures, it is



©Association of Oral and Maxillofacial Surgeons of India

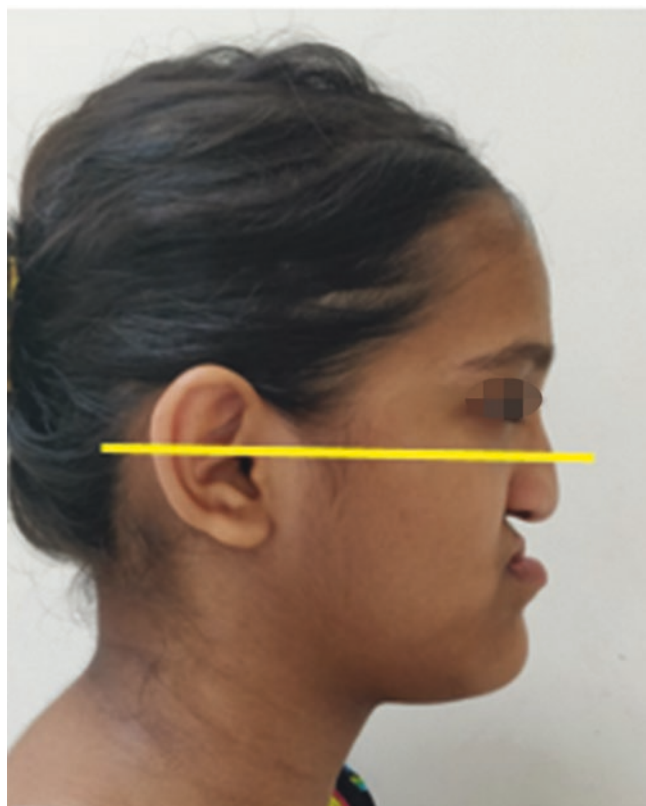Fig. 70.4 Superior (bird's-eye) view exhibiting midline discrepancy and rotation of the face

essential to position the head so that the clinical Frankfort horizontal plane (a line from the tragus of the ear through the palpable bony infraorbital rim) is parallel to the floor (Fig. 70.5). The patient should also be reminded to relax the peri-oral musculature to better assess the tooth to upper lip relation at rest. Evaluating the left and right

sides from the profile view will allow assessment of discrepancies in the antero-posterior and vertical dimensions [e.g., maxilla, mandible, and chin] rather than asymmetry evaluation.

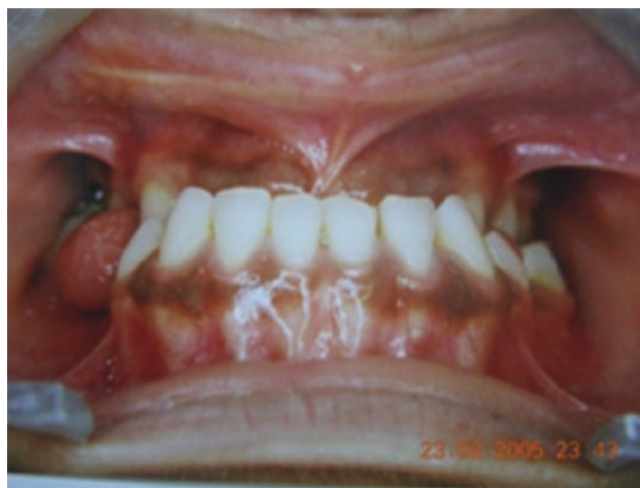70.3.2 Oral Examination

Orthodontic study models mounted in centric relation by face-bow transfer onto a semi-adjustable anatomic articulator help in dento-alveolar and occlusal assessment with a further advantage of studying the occlusion from the lingual aspect. The dental arches are evaluated for overdevelopment, underdevelopment, presence of yaw, and asymmetry in the antero-posterior, transverse, and vertical planes. The dental examination should include the presence or absence of missing, deformed, carious, impacted, or ankylosed teeth; dental midline shift; dental crowding or spacing; congenital deformity [e.g., cleft alveolus in a case of cleft lip and palate]; habitual pattern [e.g., tongue thrusting or thumb sucking]; pathology; and size of tongue and trauma (Figs. 70.6, 70.7, and 70.8). These findings can be incorporated into the treatment planning.



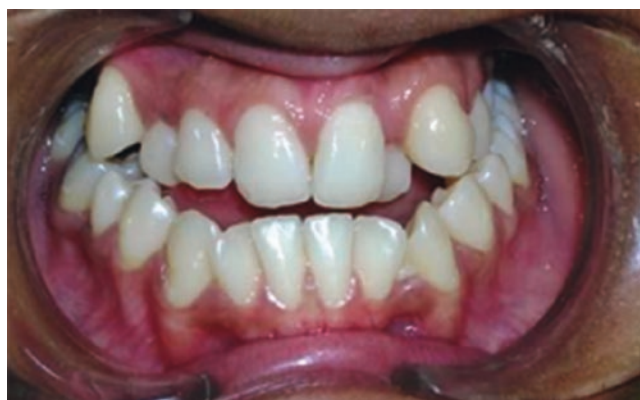©Association of Oral and Maxillofacial Surgeons of India

Fig. 70.5 Orientation of FH plane parallel to the floor



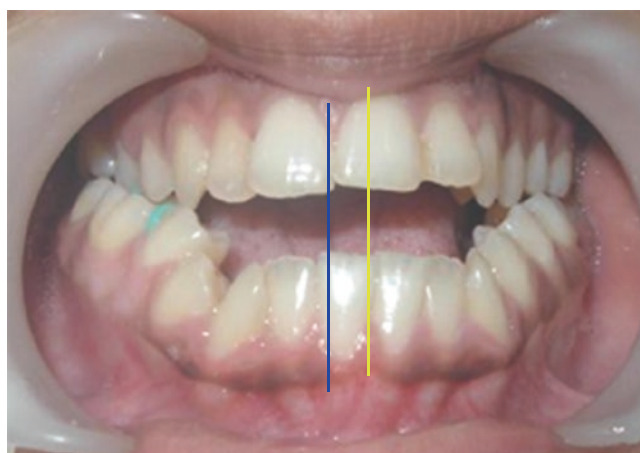©Association of Oral and Maxillofacial Surgeons of India

Fig. 70.6 Complete telescoping of the maxilla



©Association of Oral and Maxillofacial Surgeons of India

Fig. 70.7 Crowding in both arches along with a reverse overjet



©Association of Oral and Maxillofacial Surgeons of India

Fig. 70.8 Non co-incident dental midlines (blue-upper dental mid line, yellow-lower dental midline)

70.3.3 Photographic Examination

A dedicated photography room where extra-oral and intra-oral photographs are taken under standardized settings [e.g., lighting, background, focal length, and distance-to-subject] is ideal. Extra-oral photographs of the frontal [with and without smile, occlusal and mandibular inferior border cant], three-quarter, submental, and superior views are essential for the assessment of facial asymmetry. Intra-oral frontal, lateral, superior [45° to the occlusal plane from above], and inferior [45° to the occlusal plane from below] views with the teeth in occlusion are essential for dento-alveolar assessment [11, 23–26].

70.3.4 Radiographic Examination

The three primary radiographic examinations performed in the assessment of facial asymmetry are lateral cephalometry, postero-anterior cephalometry, and orthopantomography. They have been described briefly below. As a rule, serial cephalometric assessment every 6 months for a minimum duration of 1 year may be helpful in determining if the asymmetry is static and stable or if it is progressive [24, 25].

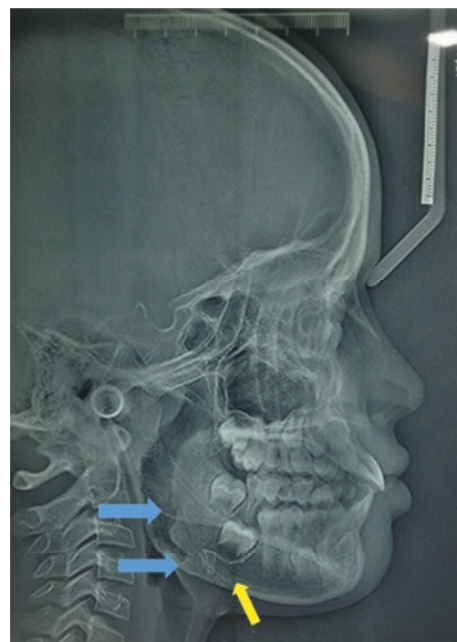
1. Lateral Cephalometry:

It is used to assess hard tissue and soft tissue relationships in 2D, i.e., antero-posterior and vertical dimensions. This tool is less commonly used to assess facial asymmetry. The head is placed into a reproducible position within the cephalostat with the help of the nasal bridge indicator and ear rods which closely approximates the clinical Frankfort horizontal plane. The patient keep should also be instructed to keep the jaws in centric relation with the teeth lightly touching and the lips slightly parted or relaxed. The ability of the cephalostat to reproduce the near about the same position every time allows for comparative cephalometric analysis and super-imposition of tracings. Bilateral vertical discrepancies [e.g., increased vertical dimension of the body and ramus-condyle unit of the mandible in unilateral condylar hyperplasia type 2] can usually be assessed in a lateral cephalogram. The right and left sides are presented as two separate non-super-imposing lines, and this can be measured as a discrepancy between the two images of the occlusal plane and inferior borders of the mandible (Fig. 70.9).

2. Orthopantomograph [OPG]:

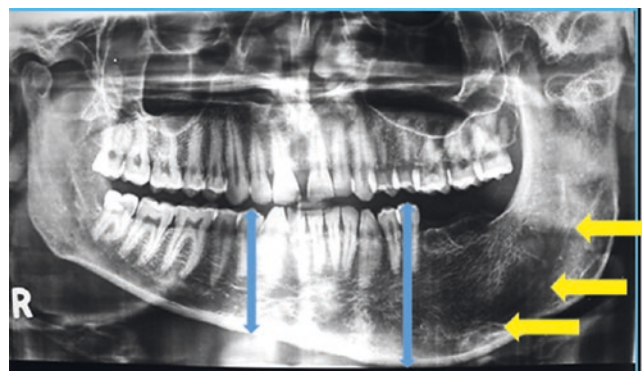
The OPG is an excellent tool to evaluate mandibular asymmetry and dental status. The anatomy of the condyle—ramus unit, body, and inferior border of the mandible is readily discernible. Increase or decrease in dimensions or changes in mandibular morphology can be studied. In cases of unilateral asymmetry, the affected side

can be compared to the normal side. The course of the inferior alveolar nerve can also be assessed and is of vital importance if an inferior border osteotomy is being performed [e.g., inferior border osteotomy in cases of unilateral condylar hyperplasia type 2 where the inferior alveolar nerve might be coursing near the lower border of the mandible] (Fig. 70.10). The OPG is also an excellent tool for the screening of maxillofacial pathology that may cause facial asymmetry, e.g., tumors and fibro-osseous lesions.



©Association of Oral and Maxillofacial Surgeons of India

Fig. 70.9 Lateral cephalogram showing double images of the inferior border of the mandible (blue arrows) along with displaced IAN canal (yellow arrow) in a case of type 2 condylar hyperplasia



©Association of Oral and Maxillofacial Surgeons of India

Fig. 70.10 OPG demonstrating the difference in height of the mandibular body (blue arrows), displacement of the IAN canal toward the inferior border (yellow arrows)

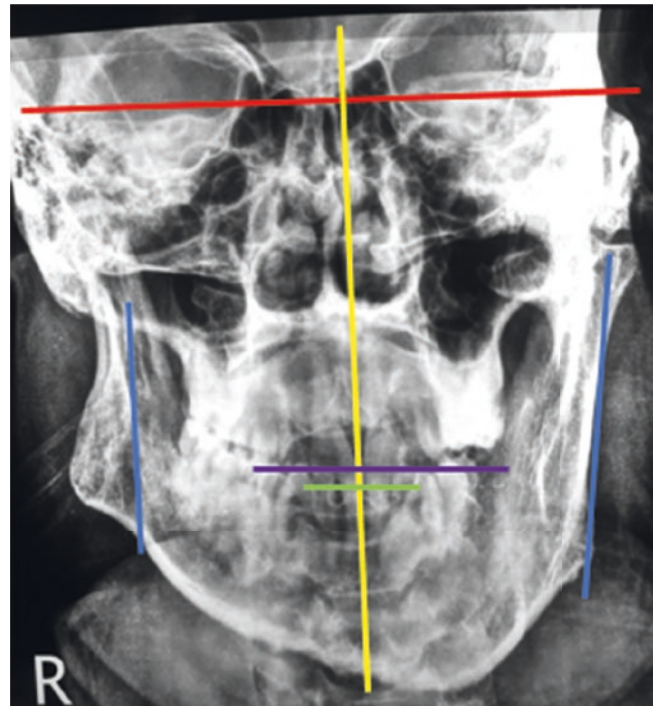
3. Postero-antero Cephalometry:

The PA cephalogram allows a comparative study of the symmetry between the structures of the right and left sides. Projections can be obtained in both open mouth position and centric occlusion with head oriented in natural head position to identify the full extent of static and dynamic [functional] asymmetry. The horizontal reference plane is represented by a line passing through the bilateral zygomatico-frontal sutures. The vertical reference plane is a line perpendicular to the horizontal plane passing through crista galli. Transverse and vertical distances of various facial structures are measured by drawing perpendicular lines drawn from the structures in question to the vertical and horizontal reference planes. By comparing the distances measured bilaterally, the type and extent of the underlying asymmetry can be assessed. Additionally, a shift in the dental midlines can be assessed by comparing them to the skeletal midline. The Grummons and Ricketts analyses are commonly used PA cephalometric analyses for the evaluation of facial asymmetry (Fig. 70.11).

4. Computed Tomography/Cone Beam CT with 3D Reconstruction:

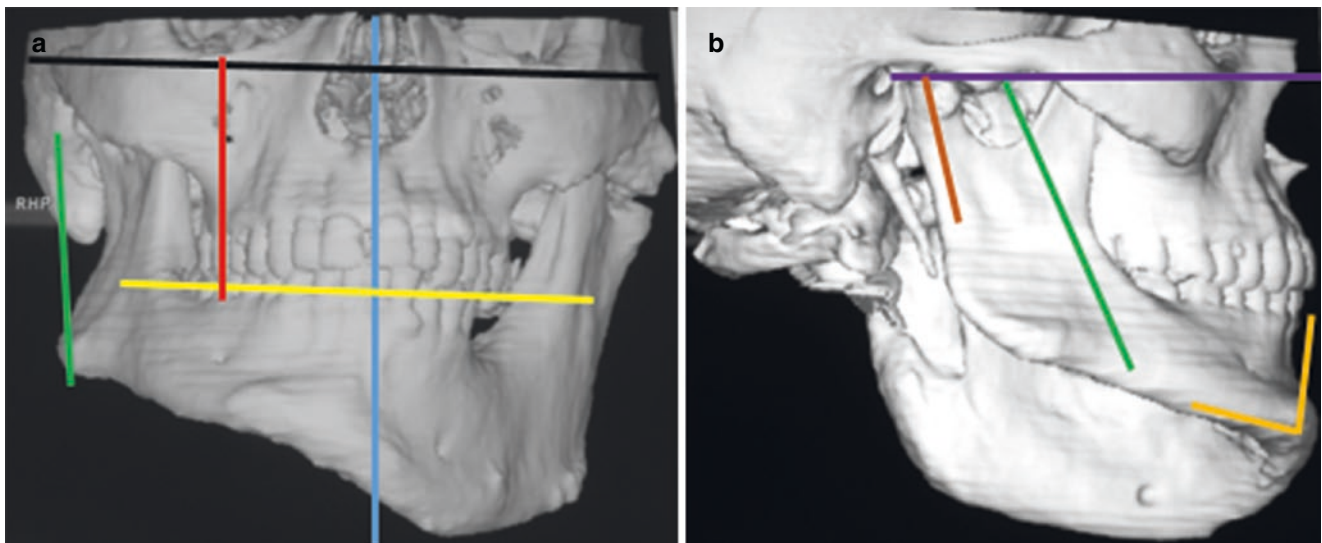
The main advantage of the 3D CT scan is that it helps in visualization and treatment planning of complex facial asymmetry in cases like craniosynostosis, Treacher Collins syndrome, hemifacial microsomia (Figs. 78.4, 78.5 and 78.6), TMJ ankylosis, and unilateral condylar hyperplasia (Fig. 70.12a, b). Unlike cephalometric and panoramic radiographs, there is no superimposition of structures, the absolute position of anatomical landmarks

can be defined, and viewing is possible from any angle. It is also an excellent tool for patient education. The CT scan data can be used for fabrication of stereolithographic



©Association of Oral and Maxillofacial Surgeons of India

Fig. 70.11 Grummons and Ricketts analysis using PA Cephalogram for evaluating the facial asymmetry. Horizontal reference plane (red); vertical reference plane (yellow); ramal height (blue); intercuspid width (green); intermolar width (purple). Refer to additional reading



©Association of Oral and Maxillofacial Surgeons of India

Fig. 70.12 (a, b) 3DCT face analysis for assessing the facial asymmetry. Various parameters include, Arbitrary horizontal reference plane assuming orbits are normal (black); FH plane (purple); mandibular height [canine to mandibular plane (orange)]; maxillary height (first

molar to FH) (red); ramal length (Co superior to Go inferior) (green); occlusal plane (yellow); lateral ramal inclination (Co superior to Go posterior to FH) (brown); midsagittal plane (light blue)

medical models which help make surgical planning even easier. The disadvantage of the CT scan is the exposure to a high radiation dose; with the introduction of the CBCT, the amount of radiation exposure has been greatly reduced. 3D reconstruction, stereolithographic model printing and integration with 3D stereo photogrammetry data allows for treatment planning, treatment simulation, and assessment customized according to the patient [e.g., Dolphin 3D, IPS by KLS Martin]. Lastly, both CT and CBCT provide valuable information regarding the hard tissue status of the TMJ and aid in the diagnosis of reactive [inflammatory] arthritis of the TMJ, osteoarthritis of the TMJ, idiopathic condylar resorption, avascular necrosis, and degenerative remodeling of hard tissues of the TMJ in dentofacial asymmetries [24, 25].

5. Magnetic Resonance Imaging:

MRI is primarily used to study the soft tissues of the TMJ [e.g., disc, capsule, ligaments] and combined with the CT/CBCT scan data is able to accurately diagnose reactive [inflammatory arthritis] of the TMJ, internal derangements, condylar resorption, and degenerative remodeling of soft tissue of the TMJ in dentofacial asymmetries (Fig. 70.13a, b) [e.g., thinning and displacement of the disc of the contralateral unaffected TMJ in cases of unilateral condylar hyperplasia] [24, 25].

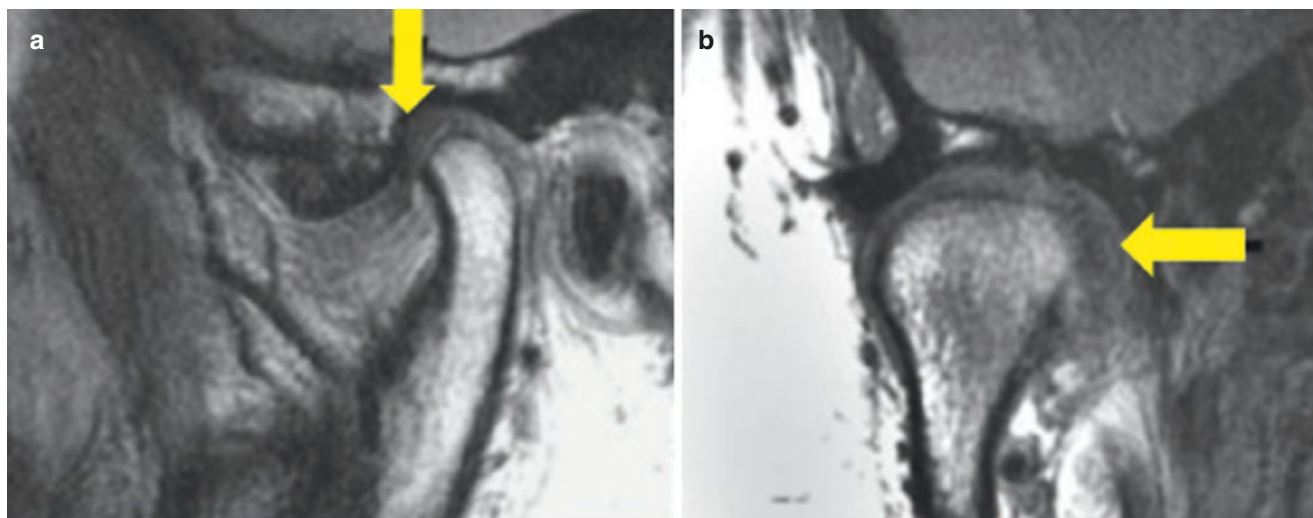
70.3.5 Stereophotogrammetry

It is the construction of a three-dimensional model based on the positions of recognizable points or landmarks in several different photographs. It utilizes two or more cam-

eras configured to capture a pair of stereo images of the surface of patient's face which are then used to generate a 3D image of the face by triangulation performed through sophisticated stereo algorithms. The technique is minimally invasive and has an expanded coverage of close to 360° of the structure being studied with quick capture speeds (often under 1 second). These advantages make it is particularly useful when working with young children [with craniofacial deformities] for whom quantification of facial features can be challenging [25, 26]. The ability to store images for subsequent use, accurate reproduction of the surface geometry of the face, and ability to map realistic color and texture data onto the recorded geometric shape make this technique the preferred facial surface imaging modality over older conventional imaging modalities like laser scanning [26].

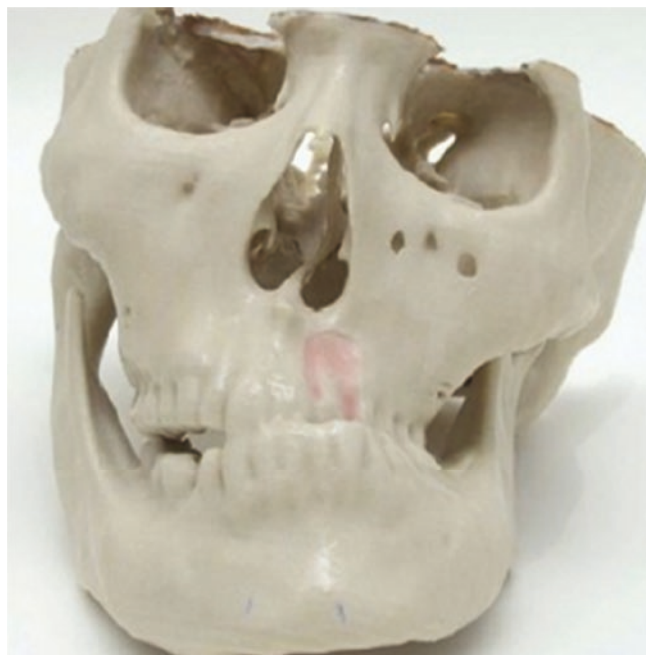70.3.6 Stereolithographic [SLA] Models

Medical modelling involves first acquiring a CT, CBCT, or MRI. This data consists of a series of cross-sectional images of the region being studied. The selected part is now created in a layer-by-layer fashion using photopolymerization ultimately forming a three-dimensional solid. The use of such models in maxillofacial surgery has significantly improved predictability of clinical outcomes in facial asymmetry cases when compared to similar treatments without its use. The models facilitate direct visualization of complex 3D facial asymmetry, decrease operating time due to better treatment planning, and can also be used as an educational tool for patients (Fig. 70.14) [27].



©Association of Oral and Maxillofacial Surgeons of India

Fig. 70.13 (a, b) MRI of TMJ showing anteromedial disc displacement (yellow arrows)



©Association of Oral and Maxillofacial Surgeons of India

Fig. 70.14 Facial asymmetry demonstrated on STL model involving both the midface and mandible with hyperplasia involving the right side

70.3.7 Virtual Surgical Planning [VSP]/ Computer-Aided Surgical Simulation [CASS]

VSP/CASS involves four key stages demonstrated in Box 70.1.

Figure 70.15 shows the sequence involved in VSP/CASS. The advantages are an increased dental relationship accuracy, reduced OR time, increased patient satisfaction, and decreased costs. Simulating surgery preoperatively allows measurements to the 1/100th of a millimeter, and when combined with 3D-printed splints and customized pre-bent plates, the reconstructive and aesthetic outcome is supe-

Box 70.1 Four key stages in virtual surgical planning

- Data collection and pre-surgical workup
- Virtual treatment planning
- Splint fabrication
- Surgery and accuracy

Data collection and presurgical work-up

Clinical examination

Occlusal record (casts)

Centric relation record

CBCT or CT scan

Final occlusion established by surgeon

Data transfer to planning center

Planning specifics – order from (osteotomy design, order of osteotomy, and anticipated movements)

Virtual treatment planning – web meeting/video conferencing (for sequence of treatment planning)

Natural head position based on clinical examination

Frontal planning – midline/yaw or cant/roll correction

Profile planning – repositioning of central incisor/pitch changes (anteroposterior and vertical)

Occlusal plane changes (clockwise or counterclockwise)

Based on 2-D imaging programs

Yaw/ orientation of proximal and distal segments

Segment orientation/ interferences

Splint design

Surgery

Transfer of virtual planning to operating room

Occlusal splints

Cutting guides to aid in orientation of bony osteotomy

Occlusal borne guides to aid in repositioning of bony segment

Templates to aid in contouring of bone grafts

Predictive hole placement for custom plating of osteotomies

Accuracy

Merger of postoperative scans to virtual plan

CASS more accurate than traditional model surgery

Improved clinical outcomes with CASS

Fig. 70.15 Flow chart outlining the steps involved in virtual surgical planning has been reproduced after permission from the article “Farrell BB, Franco PB, Tucker MR. Virtual surgical planning in orthognathic surgery. Oral Maxillofac Surg Clin North Am. 2014; 26(4):459–73” [28]

rior to traditional 2-dimensional (2D) modelling and cephalometric tracing [28].

70.3.8 TMJ Examination

TMJs must be healthy for predictable orthognathic surgery outcomes. The TMJ must be assessed before and after orthognathic surgery for joint noises (clicking and popping), localized tenderness, radiating facial [e.g., headaches] and neck pain, and limitation of mouth opening and jaw locking. The literature reports a higher incidence of TMD in patients with retrognathic mandibles and in those with steep occlusal planes [29, 30].

There is no conclusive evidence regarding the effect of orthognathic surgery on TMD with opinions split between improvement, no change, or worsening of signs and symptoms. However, high-angle, class II patients with pre-existing TMD undergoing counterclockwise rotation or large mandibular advancement procedures are known to experience worsening of symptoms. Figure 70.16 is the Boston University Protocol for the management of facial asymmetry requiring orthognathic surgery with pre-existing TMD [29].

70.3.9 Nuclear Medicine Imaging Modalities (Scintigraphy)

A bone scan is a nuclear imaging test that involves injecting a small amount radiotracer that into the bloodstream. The radiotracer travels through the area being examined and gives off radiation in the form of gamma rays which are detected by a special gamma camera and a computer to create images of your bones. Thus, skeletal scintigraphy offers the potential to identify disease in its earliest stages as it is able to identify any abnormal increases in metabolic activity [31].

Cisneros first used bone scintigraphy to study mandibular asymmetry in patients [31]. There are two types of bone scan techniques commonly used: skeletal scintigraphy [subtypes: planar bone scanning and single-photon emission-computed tomography] using technetium-99m methylene diphosphate and positron emission tomography [subtypes: with and without CT, full ring and half ring] using radiolabeled 18F-2-fluoro-2-deoxyglucose [glucose analog].

Planar [regular] scintigraphy is not very accurate as it is only a two-dimensional assessment of three-dimensional anatomy. On the other hand, SPECT [single-photon emission computed tomography] allows three-dimensional assessment as the isotope is dispersed in the subject's body thus allowing spatial localization of the pathology in the mapped body organ.

Dedicated/full-ring PET [as compared to half-ring PET] provides better spatial resolution than a planar bone scanning and SPECT (Refer Fig. 78.13) because of its narrower electronic collimation [full width half maximum (FWHM) central resolution for PET being 6 mm compared with 11 mm for SPECT] [21, 32, 33]. As the condylar growth plate is thin, PET gives an advantage to identify pathologies like condylar hyperplasia.

Important factors to be taken into account when assessing a bone scan:

- The efficacy of bone scan is reduced during the growing phase as condyles are growth centers and both will show increased metabolic activity.
- The efficacy of bone scan is increased after the growth phase is completed as only the affected condyles will show increased metabolic activity.
- The efficacy of bone scan is increased in unilateral cases and reduced in bilateral cases.
- *Condylar Hyperplasia Type 1*
 - The growth in type 1 condylar hyperplasia is only slightly faster than the normal condylar growth rate. Therefore, the difference in intensity of radiotracer uptake between a normal and affected condyle is negligible.
 - The cellular growth activity is confined to a narrow band at the normal growth center resulting in low uptake of the radiotracer.
 - Condylar hyperplasia type 1A cases: It is difficult to differentiate CH type 1A from normal growth as it a bilateral condition with both joints involved.
 - Condylar hyperplasia type 1B cases: As this is a unilateral condition, it is easy to identify clinically. There has to be a difference in activity of at least 10% between the affected side and the normal side for a diagnosis of asymmetric growth activity/unilateral condylar involvement to be made.
- *Condylar Hyperplasia Type 2*
 - It is easy to diagnose on the bone scan as it is usually a unilateral condition with a tumorous rate.
 - There is diffuse cellular activity throughout the tumor in the condylar head which makes it easier to diagnose on the bone scan.

70.4 Clinical Considerations

70.4.1 Occlusal and Orthodontic Considerations

Asymmetries with congenital and developmental etiology are commonly associated with dental compensations in all three dimensions as growth ensues. Rotations and crowding are

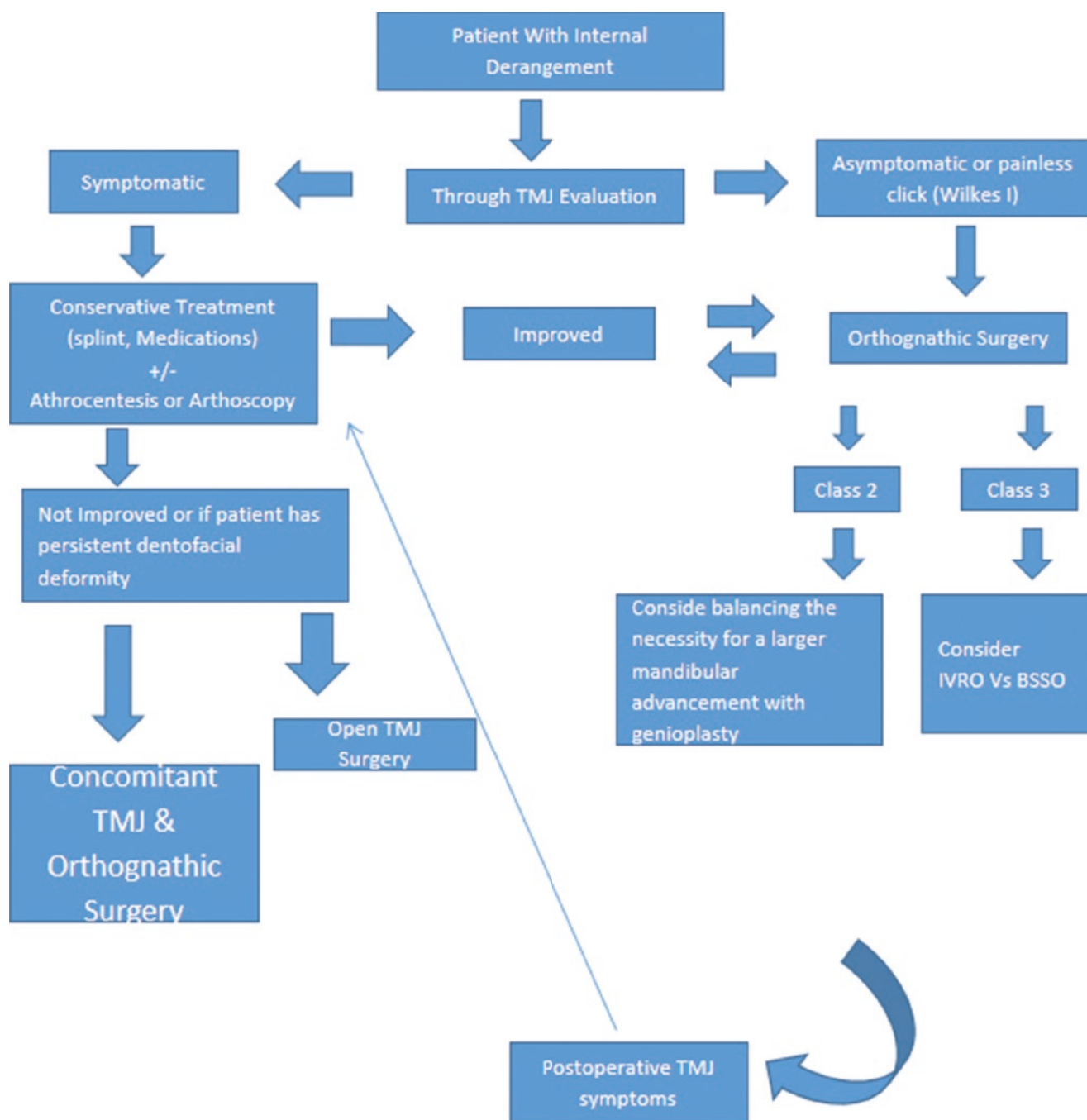


Fig. 70.16 The flow chart outlines the Boston University Protocol for the management of temporomandibular disorders in patients who present for orthognathic surgery and has been reproduced from the article

“Nadershah M, Mehra P. Orthognathic Surgery in the Presence of Temporomandibular Dysfunction. What Happens Next? Oral Maxillofac Surg Clin North Am. 2015; 27(1):11–26” [29]

seen in hypoplasia cases such as hemifacial microsomia, and spacing and cross bites can be encountered in case of overdevelopment such as condylar hyperplasia. Transverse growth discrepancies also result in different arch shapes and Bolton discrepancy. Also, the extent of maxillary asymmetry should be accounted for, as maxilla tends to be ignored in obvious mandibular asymmetry. Thus, pitch, yaw, and roll need to be

adjusted or decompensated keeping the surgical movement in mind [34]. Pre-surgical orthodontic treatment in patients with facial asymmetry must include the following:

- (a) The presence of a dental and facial midline mismatch indicates a discrepancy in the yaw of the affected jaw[s]. Midline correction at the time of orthognathic surgery provides the best results.

- (b) Any occlusal cant correction should not be attempted orthodontically. Cant is evidently skeletal in nature and should be corrected surgically.
- (c) Levelling and alignment of the dental arches should be done.
- (d) Post-operative position of the upper incisor and the upper lip-maxillary incisor relationship is the most important factor determining surgical result. This should be checked intra-operatively before fixation of the maxilla.
- (e) Position of the symphysis similarly is another important determinant of a satisfactory postsurgical correction in cases of asymmetry; thus the anatomical position and surgical limits of symphysis correction should be determined pre-surgically.
- (f) The facial midline reference should be taken from the unaffected jaw.
- (g) In cases of hemifacial microsomia and temporomandibular joint ankylosis, a unilateral open bite is created after increasing the ramus height. This is done to correct the skeletal cant by allowing the vertical alveolar growth of maxilla.
- (h) Cephalometric analyses are essential but seldom definitive in determining the amount of advancement in antero-posterior and vertical movements. Prediction tracings are helpful but not mandatory in planning post-surgical outcome. Specific norms available are not always applicable especially in asymmetry cases as the etiology is variable. The etiology and duration of asymmetry influence the extent and severity of the case.
- (i) Based on the severity of crowding, the amount of retraction and uprighting needed; upper second bicuspid extraction [minimal decompensation] or upper first bicuspid extraction [greater decompensation] is indicated.

70.4.2 Growth and Development of the Craniofacial Skeleton

Importance of understanding growth of the maxillofacial skeleton in an individual presenting with asymmetry cannot be emphasized enough. Almost half of the asymmetries are either due to an underdevelopment or an overdevelopment of the TMJ resulting in a deviated mandible in the vertical or antero-posterior direction or both of the involved side or the contralateral side. If this development takes place in the growing period, the maxilla follows the deviation of the mandible. Interceptive orthodontics can be applied in growing areas to arrest or limit the extent of asymmetry of the maxilla and mandible [35]. However, surgical intervention is

generally needed after completion of growth period for the final skeletal and dental correction. Surgical treatment performed before growth completion is unpredictable on account of the continual growth that the patient experiences till skeletal maturity and as such is reserved only for those cases suffering from extreme functional, aesthetic, and psychological problems. Additional surgery may be needed to correct the recurrent asymmetry. Thus, timing of surgery relies very much on the growth completion.

Serial cephalometric radiographs, scintigraphy, and SPECT scans are useful to assess growth potential. The absence of activity in the TMJ and other areas helps the surgeon to proceed for corrective orthognathic surgery. The second factor for determining the timing of treatment is the progression of the asymmetry. If the asymmetry is progressive like condylar hyperplasia, it is better to wait or perform high condylectomy to check any further asymmetric growth. On the contrary, non-progressive asymmetries such as hemifacial microsomia, treatment can be initiated in early years [36]. Comparably, early surgery has usually been performed for individuals with marked malformations such as plagiocephaly, cleft lip and palate, and/or severe functional burden (e.g., increased intracranial pressure, severe obstructive sleep apnea, etc.). Lastly, in few cases of acquired asymmetry such as tumor resection, “wait-and-watch” policy needs to be adopted to eliminate chances of recurrence before a definitive reconstruction can be planned.

70.4.3 Role of Functional Orthopedics and Interceptive Orthodontics

Functional orthopedics play a substantial role in congenital asymmetries, the greatest example being nasolabial molding in cleft lip and palate cases to bring the maxillary segments into a more desirable position prior to surgery. Growth modification with the use of functional appliances is directed toward eruption of the dentition in a more favorable position and prevents worsening of the skeletal asymmetry exacerbated during growth period. Functional therapy is also aimed at maintaining the condyle in a more anatomical position to allow further growth in a symmetrical pattern. Studies have shown that an asymmetric lateral force during the growth period results in growth modification by influencing the morphology of the mandibular bone and the overlying masseter muscle. Occlusal splints can be fabricated to allow for mandibular shifts toward midline, and open bite can be created to eliminate canting. This is especially helpful in hemifacial microsomia and TMJ ankylosis cases. Patient compliance is a prerequisite in functional therapy cases. Also, keeping in view the growth potential, long-term follow-up is always warranted.

70.4.4 Role of TMJ and Considerations for Treatment

TMJ is the driving force in the development of an asymmetry. Although the role of condylar cartilage has been proved to be secondary in mandibular growth and development, any pathological change leading to under- or overdevelopment can cause severe progressive asymmetry. As mentioned, TMJ-related asymmetries can be categorized as underdevelopment or overdevelopment of the condyle and in some cases both. Pseudo-asymmetry occurs due to lateral shifts on account of dental pre-maturities. Kaban and Pruzansky have also graded hemifacial microsomia (Refer Chap. 78) based on the anatomy of the ramus condyle unit [RCU] and the glenoid fossa which make up the TMJ [36, 37]. Management of the TMJ pathology should be performed initially following which any skeletal correction should be attempted. Failure to do so has led to relapse due to the unpredictability of TMJ behavior and growth. Clinical and diagnostic imaging should be performed prior to any asymmetry correction to assess the status of TMJ. CT scans are a must for assessment in all three axes, as TMJ tumors like osteochondroma may not be discernible on 2D imaging. High or low condylectomy, ankylosis release, and RCU reconstruction should be done prior or simultaneously with orthognathic surgery. Distraction osteogenesis has also been used for neo-condyle formation. Alloplastic reconstruction of the TMJ is the most recent advancement with stable long-term results. The rationale for TMJ reconstruction is to provide a functional stable and reproducible movement which is harmonious with the stomatognathic system. Asymmetrical patients have also been found to have a higher incidence of condylar morphological changes and temporomandibular disorders on the affected side. Over time, due to the imbalance of masticatory loads and poor jaw function, the TMJ of the unaffected side also displays similar pathological changes [38].

70.5 Treatment Planning

Following issues need to be considered before planning orthognathic surgery (Box 70.2):

Box 70.2 Issues that need to be considered before planning orthognathic surgery

1. Single jaw versus bi-jaw surgery
2. Mandible first versus maxilla first approach
3. Surgery first approach
4. Traditional planning versus virtual planning
5. Modifications in surgical technique for asymmetry cases

70.5.1 Single Jaw Versus Bi-Jaw Surgery

Facial asymmetries are rarely corrected by single jaw surgery. When the amount of discrepancy is excessive, it is best treated by dividing the overjet as well as the cant between the two jaws to achieve optimal results. During growth in congenital and developmental cases, maxilla follows and is equally involved as the mandible. Thus, it is prudent to do a bi-jaw surgery. Also, in cleft maxillary hypoplasia cases, differential maxillary advancement with simultaneous setback is the treatment of choice. We have presented a case where simultaneous maxillary distraction was done with mandibular setback. Owing to the presence of a cleft, maxilla has severely deviated midline with an extreme reverse overjet. In such cases, maxillary distraction allows slowly advancing the maxilla and simultaneously correcting the midline by distracting more on the deficient side [39] (Fig. 70.17a–c). Segmental osteotomies or differential surgically assisted rapid palatal expansion (SARPE) might also be needed in some cases to correct transverse asymmetry (Fig. 70.18a–c). Additionally, bone contouring of the mandible and zygoma may be needed to reduce the hyperostotic bone to achieve a harmonious facial contour. This is true in case of hemifacial hypertrophy and hemi mandibular hyperplasia. Similarly, additional augmentation of paranasal areas, malar prominence, and angle of mandible augmentation are frequently indicated in hypoplasia cases.

70.5.2 Mandible First Versus Maxilla First Approach

Either of the surgical sequences can produce similar outcomes when properly planned and executed in the vast majority of bimaxillary cases. Mandible first approach is specially mentioned here as it is important in Class 3 asymmetries. Firstly, in cases where maxilla may be hypoplastic, especially in the syndromic cases of mandibular hyperplasia, rigid fixation of maxilla and down-grafting may not give stable results. Thus mandible should be fixed first, then maxilla. Secondly, because of differential load on the TMJ, CO-CR discrepancy exists, and it is difficult to achieve a stable centric. In such cases fixing the mandible first is beneficial [40]. Lastly, Class 3 asymmetries are associated with concomitant TMJ pathologies, hence TMJ surgeries such as high condylectomy may be needed to be performed simultaneously, in such cases, and mandible first approach is generally the preferred choice.

70.5.3 Surgery First Approach (Refer Chap. 67)

The surgery first approach [SFA] came about as there was a need for immediate aesthetic improvement with shortening

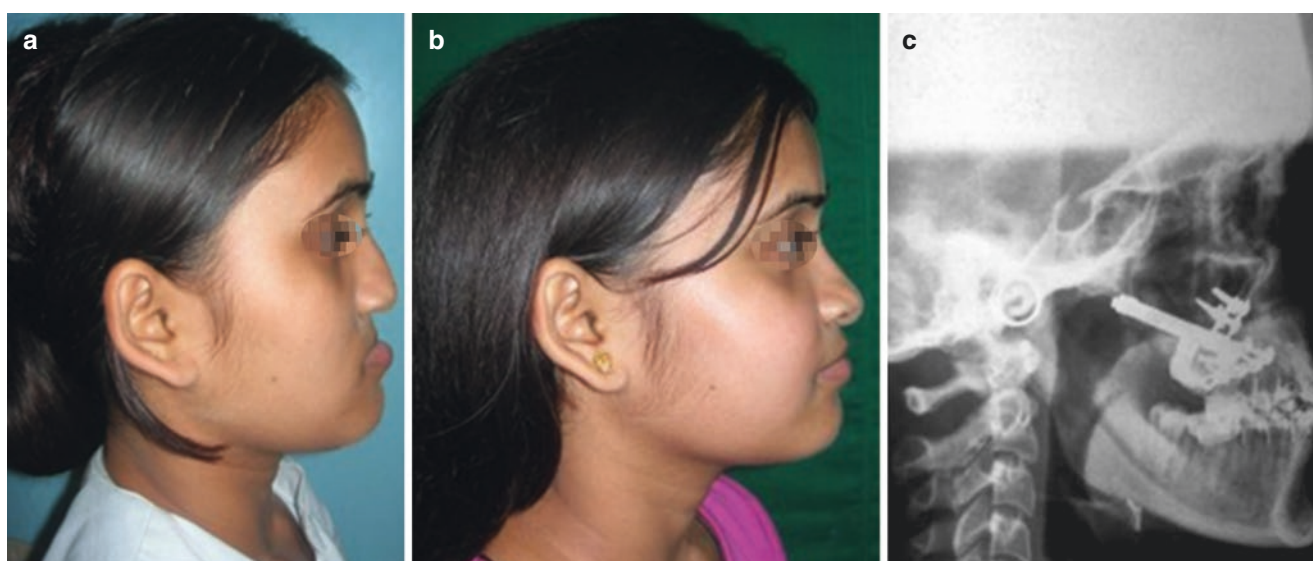
of the overall duration of treatment. However, it should be known that not all cases fulfil the criteria for SFA [e.g., flat curve of Spee and minimal crowding and rotations]. The total treatment duration can be shorter than the conventional three-staged surgical orthodontic treatment owing to the lack of need of pre-operative orthodontics and the subsequent post-surgical “regional acceleratory phenomenon.” However, reliability of SFA is still questionable, especially in more complex dentofacial deformities, like facial asymmetry.

Park et al. reported no significant differences in postoperative stability between SFA and OFA after bimaxillary surgery in skeletal class III malocclusion patients [41]. In SFA, vertical dimension in surgical occlusion can increase due to occlusal interference and lead to postoperative counter

clockwise rotation of the mandible as occlusal settling progresses during the postoperative orthodontic period. This may contribute toward greater postoperative mandibular forward movement.

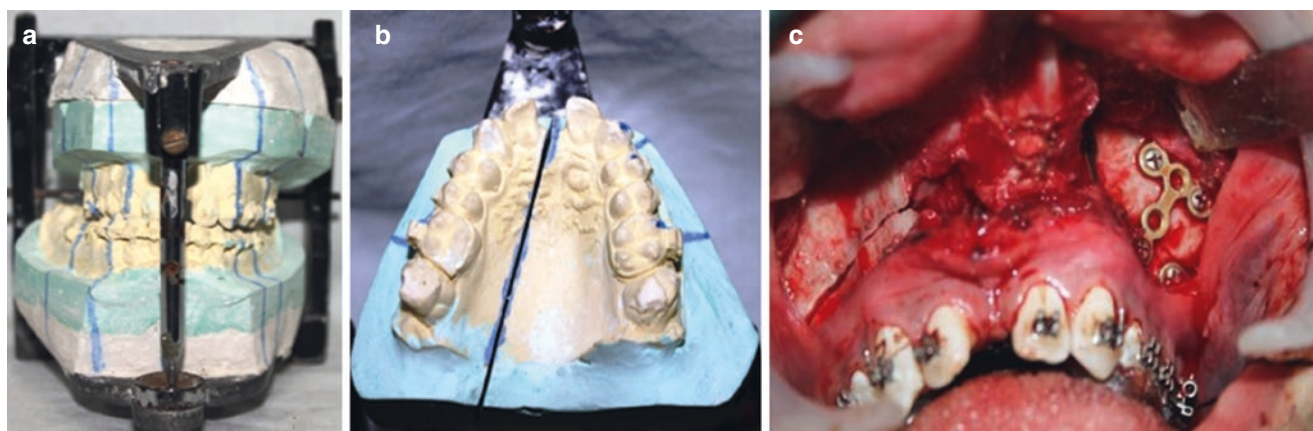
70.5.4 Modifications in Surgical Technique for Asymmetry Cases

The bilateral sagittal split osteotomy is the commonly used technique in asymmetry cases. It is highly flexible and adaptable in all movements. The three-dimensional anatomy of the mandible must be retained when planning a BSSO. According to Schwartz, three types of surgical move-



©Association of Oral and Maxillofacial Surgeons of India

Fig. 70.17 Case of cleft maxillary hypoplasia who underwent maxillary distraction using internal device. (a) Pre-operative profile photo showing retruded midface, (b) post-operative profile photo showing good midface fullness, (c) post-distraction lateral cephalogram showing distractor in-situ



©Association of Oral and Maxillofacial Surgeons of India

Fig. 70.18 (a) View of the maxillary study model. (b) Osteotomy cut marked for SARPE. (c) Fixation done using miniplate only on left side. This is done to ensure expansion of the only the right side on activation of appliance

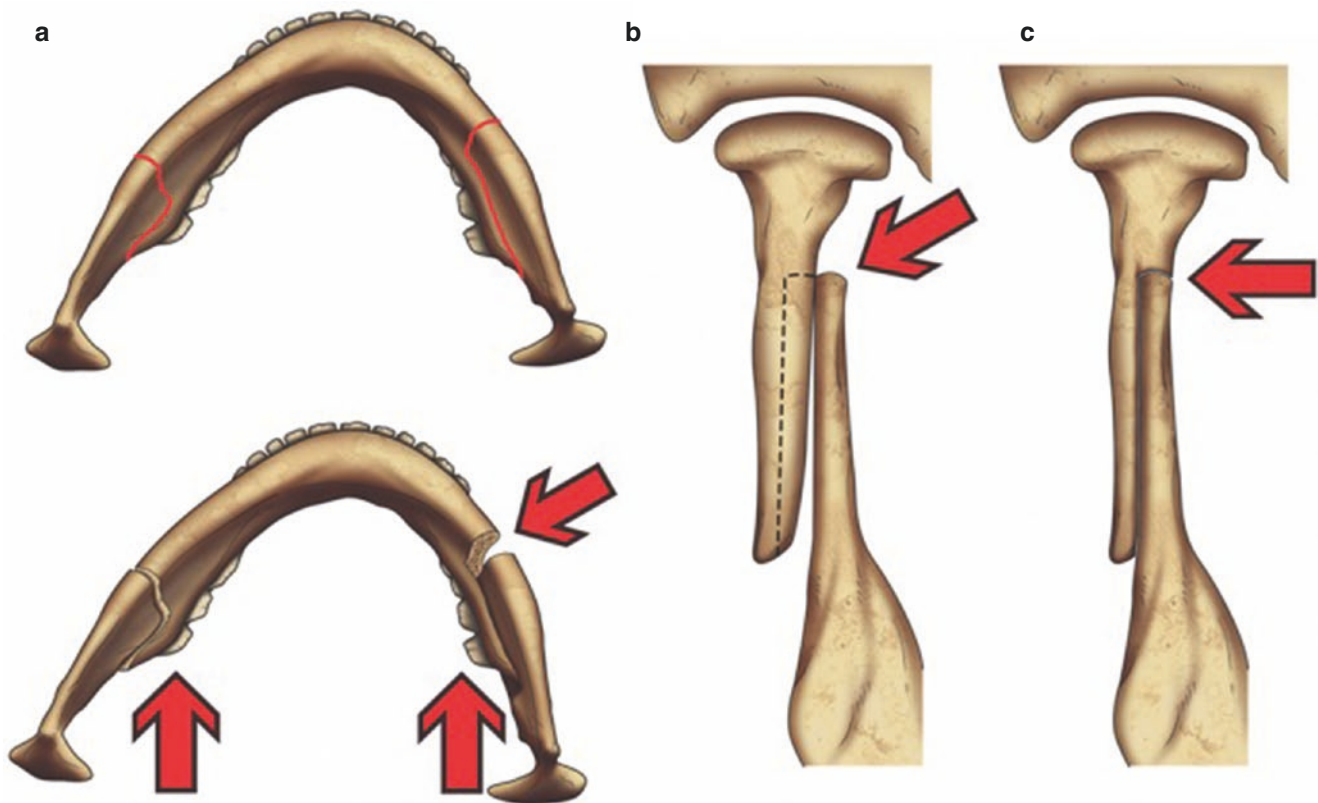


Fig. 70.19 (a) When an asymmetric case is viewed along the vertical axis, areas that require immediate bone removal become obvious. Heavy interferences will take place anteriorly on the long side and posteriorly on the short side; (b) After the condyle is seated, premature bone contact is noted posteriorly. The area proposed for additional bone

removal is indicated by the dotted line; (c) Good bone contact has been achieved. Image Source: Schwartz HC. Efficient surgical management of mandibular asymmetry. *J Oral Maxillofac Surg.* 2011 Mar;69(3):645–54. doi: 10.1016/j.joms.2009.03.009. Epub 2010 Oct 8. PubMed PMID: 20934795 [42]

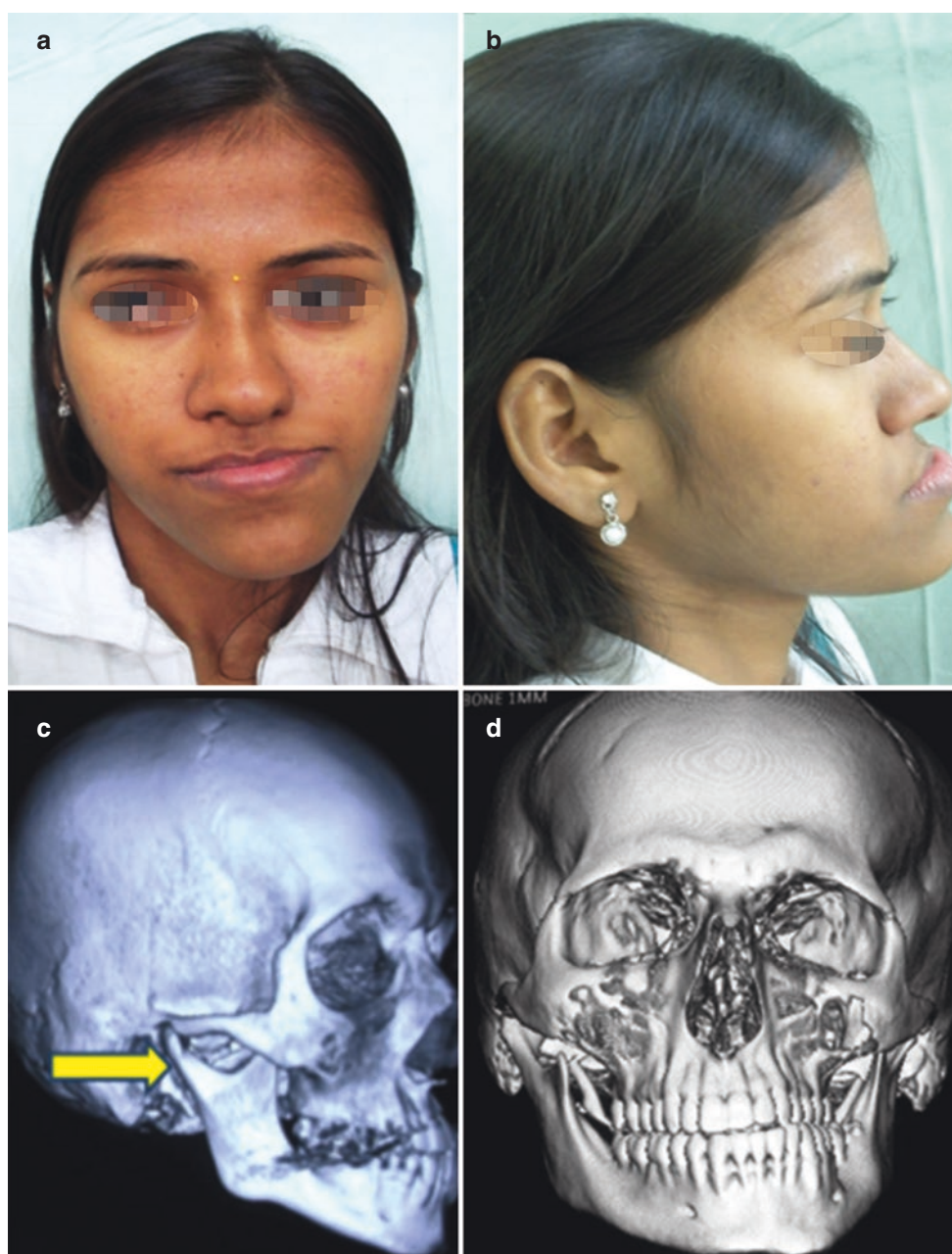
ments can be planned with BSSO in asymmetry cases: in case of a normal overjet and overbite, differential movements will be made that is setback on the long side and advancement on the short side. In Class II asymmetry, in order to achieve symmetrical advancement, there will be a longer advancement on the short side than on the long side and lastly in Class III cases, there will be a larger setback on the long side than on the short side. During surgery, the distal segment rotates from the short side to the long side as the midline is corrected (Fig. 70.19a). Selective bone removal from the area of interferences should be done before the distal segment has been passively repositioned. Bone is removed from the anterior and medial aspects of the proximal segment until there is broad contact along segments. On the short side, first contact will occur posteriorly [42]. Bone is removed from the medial aspect of the proximal segment posteriorly (Fig. 70.19b, c). This is done to reduce condylar torque during rigid internal fixation to ensure stability of the movement. Figures 70.20a–d and 70.21a, b show a case of unilateral condylar elongation treated with differential BSSO.

70.5.5 Soft Tissue Interventions

The asymmetrical growth of soft tissues may lead to residual soft tissue asymmetry even after correction of the underlying bony deformity. Furthermore, some asymmetrical craniofacial regions cannot be corrected by means of conventional surgical techniques. Adjunctive soft tissue procedures [e.g., dermis fat transplant, autologous fat transfer, microvascular adipose free flaps] might be indicated to achieve bulk in deficient soft tissue deformities such as Parry Romberg syndrome, TMJ ankylosis, etc. Alloplasts such as Medpore, silicone, nanogels, tissue expander, etc. have also been used with varying degrees of success (Sect. 70.7 “Case Scenarios”).

70.5.6 Distraction Osteogenesis (Also refer Chap. 87)

Distraction osteogenesis is the process of native bone formation via traction of osteotomized segments. On account of distraction histogenesis, simultaneous soft tissue and



©Association of Oral and Maxillofacial Surgeons of India

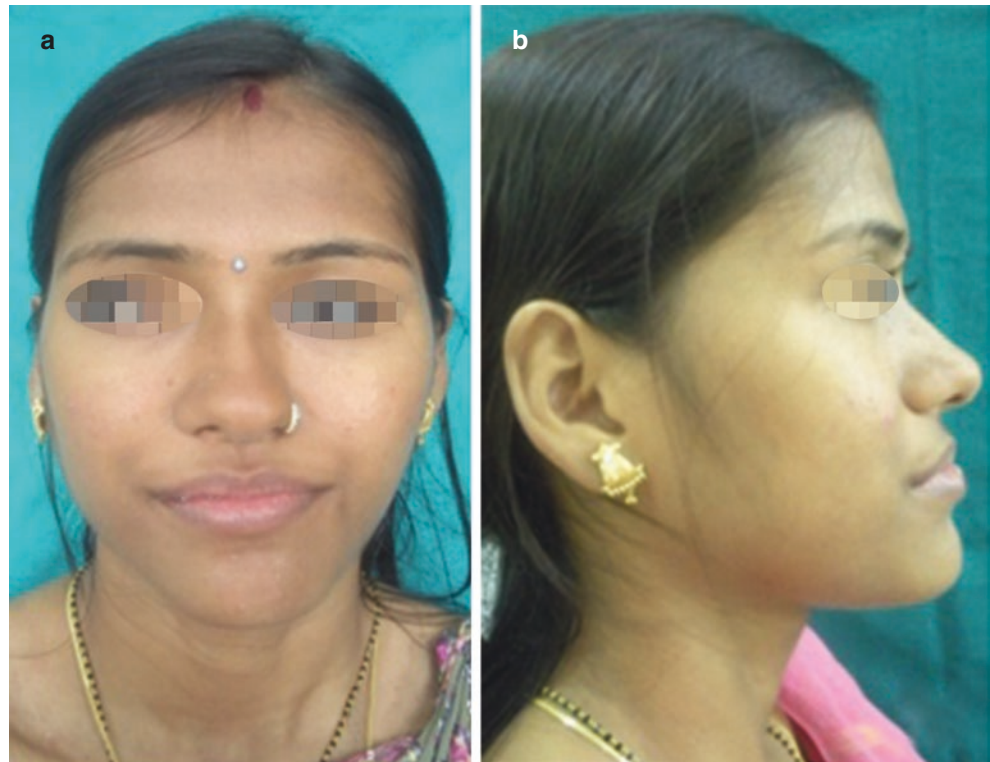Fig. 70.20 (a–d) Clinical and radiographic images showing a case of image showing severe facial asymmetry with unilateral condylar elongation on the right side. (a) frontal photo, (b) profile photo, (c, d) lateral and frontal views on volume rendered 3D CT scan

hard tissue augmentation can be achieved. Adequate amounts of advancements can be achieved without any soft tissue limitations. Various cases have been treated successfully with DO that are presented in this chapter. DO has various advantages over conventional osteotomies in complex facial asymmetries. Pre-arthroplastic distraction in ankylosis-related asymmetries has been reported to have excellent results [43]. This is because simultaneous distraction of skin, muscle, and tissue takes place with bone regeneration. Thus, better esthetics are achieved without any need for additional soft tissue procedures. Distraction

is often the only procedure of choice in large advancements, rate of relapse is significantly lower, and results are much stable. Figures 70.22a–e, 70.23a, b, 70.24a–d and 70.25a–g show a case of facial asymmetry secondary costochondral graft resorption in a case of TMJ ankylosis, treated with stage one distraction osteogenesis followed by definitive correction with BSSO.

(Also refer Figs. 78.43, 78.44, 78.45, 78.46, 78.47, 78.48, 78.49, 78.50, 78.51, 78.52, and 78.53 for management of facial asymmetry cases due to Hemifacial microsomia and Traeher Collins syndrome).

Fig. 70.21 Same patient as in Fig. 70.20 demonstrating corrected facial midline and mandibular prognathism postoperatively (a) frontal view, (b) profile view



©Association of Oral and Maxillofacial Surgeons of India

70.6 Conclusion

Facial asymmetry is a three-dimensional facial deformity having multiple etiologies. Complete and thorough knowledge of the etiological factors, the progressive nature of the asymmetry plays a crucial role in formulating a treatment plan. Growth and development of the individual and timing of intervention is the single most important factor affecting the stability of results in any form of asymmetry. Severe relapses could occur if the exact cause of asymmetry is overlooked and treatment is attempted before completion of growth [44, 45].

Acknowledgment Gratitude and acknowledgments to Dr. Harsh Desai and Dr. Shibani Nerurkar for their sincere efforts in collection of data and editing of the contents.

Disclosure Authors have no financial conflicts to disclose.

70.7 Case Scenarios

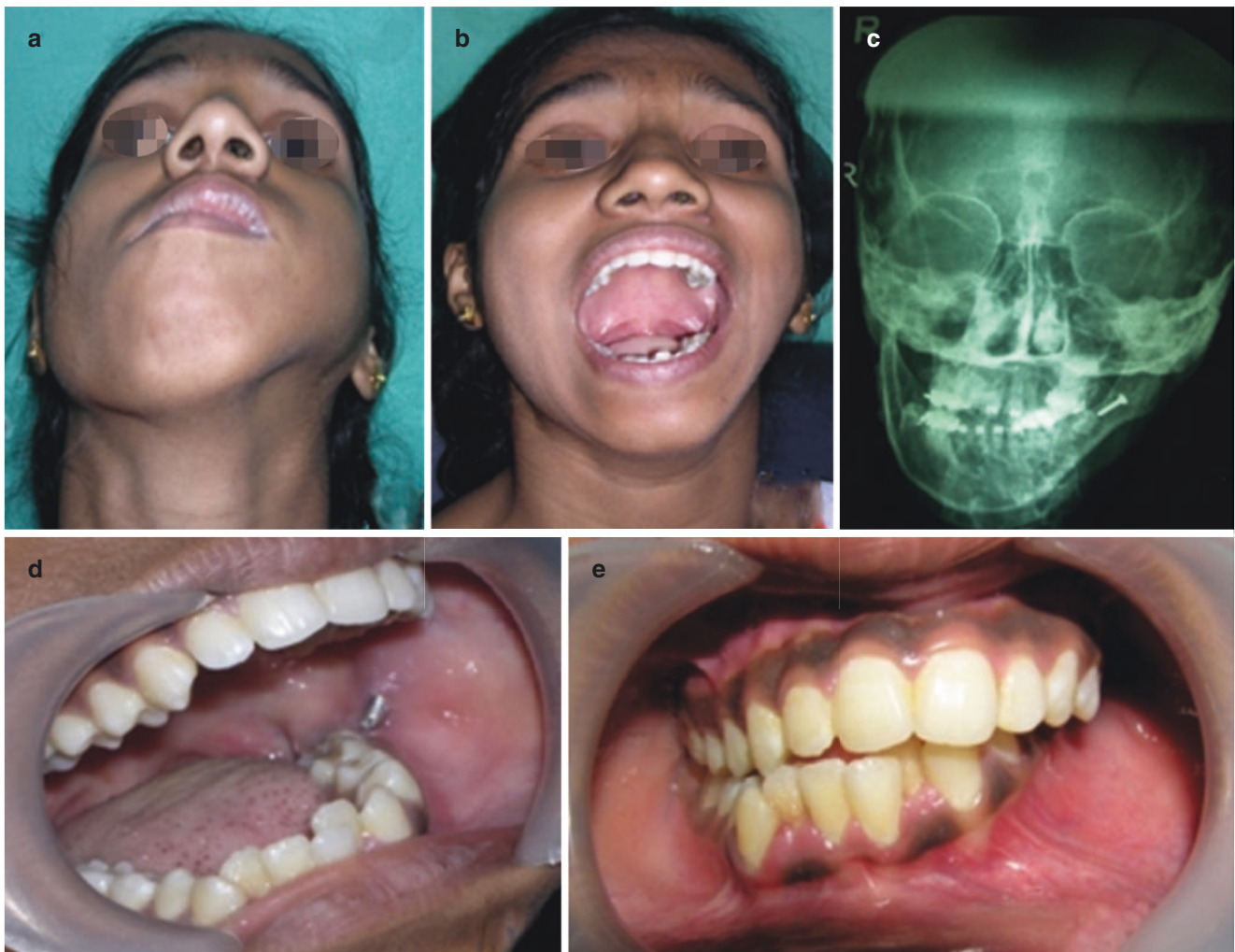Case 1: Condylar Hyperplasia with Concomitant Masseteric Hypertrophy (Figs. 70.26a, b, c, 70.27a, b, 70.28a, b and 70.29a, b)

A 27-year-old female patient reported with a complaint of a progressive facial asymmetry and an appearance of fullness over the left angle of the mandible.

On examination, the patient had a tapered, triangular shape of the face with an obvious facial asymmetry which was evident along with elongation of the right side of the face and fullness over the left angle region (Fig. 70.26a). The mandible revealed bowing on the right side with a mild symphysis kink. TMJ on palpation revealed mild clicking on the right side and otherwise equal movements along with unrestricted mouth opening was noted. On assessing the left angle region, an outward projection was noted due to the underlying hyper functioning of the masseter muscle. On clenching, significant enlargement of the involved muscle was seen as compared to the contralateral side (Fig. 70.26b).

Intraoral examination did not reveal any occlusal cant (Fig. 70.26c). There was an absence of cross bite/open bite, on either side, along with a stable occlusal relationship. The dental midlines were coincident with the skeletal midline and with each other too. No other dental abnormalities were evident on examination.

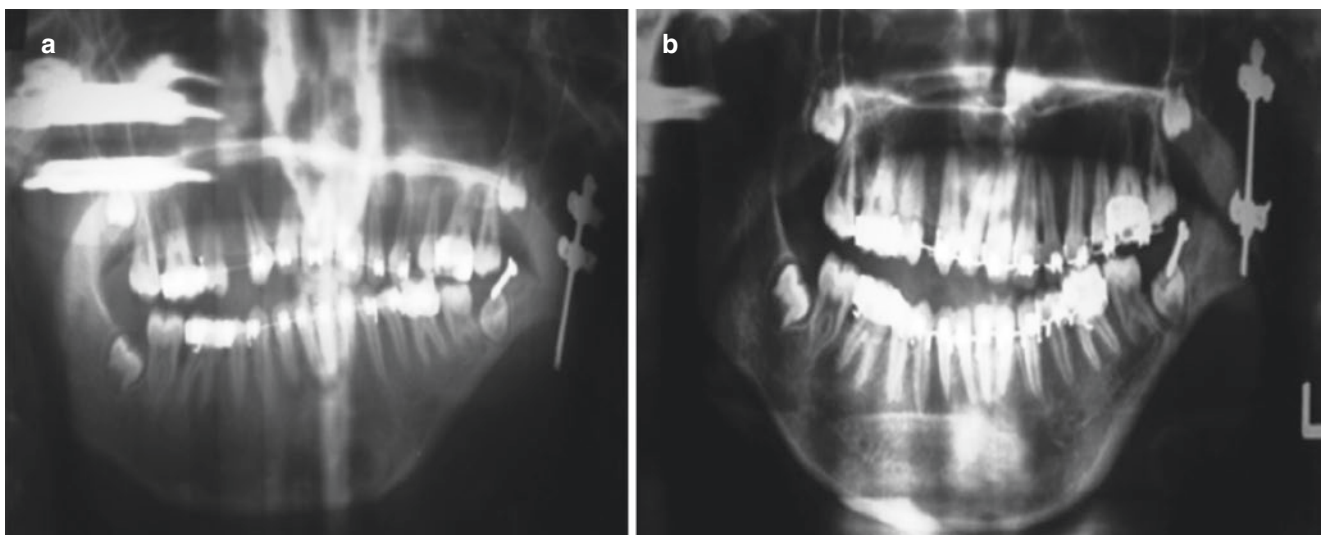
Imaging studies revealed mild degree of deflection of the chin and mandible toward the left side (Fig. 70.27a, b). Transverse mandibular asymmetry was reported. The condylar head appeared to be irregularly deformed, while the neck on the right side appeared broader as compared to the left side. The ascending ramus appeared elongated with a rounded gonial angle. The mandibular lower border was bowed downward and positioned lower on the right side as compared to the left side. The distance between the tooth



©Association of Oral and Maxillofacial Surgeons of India

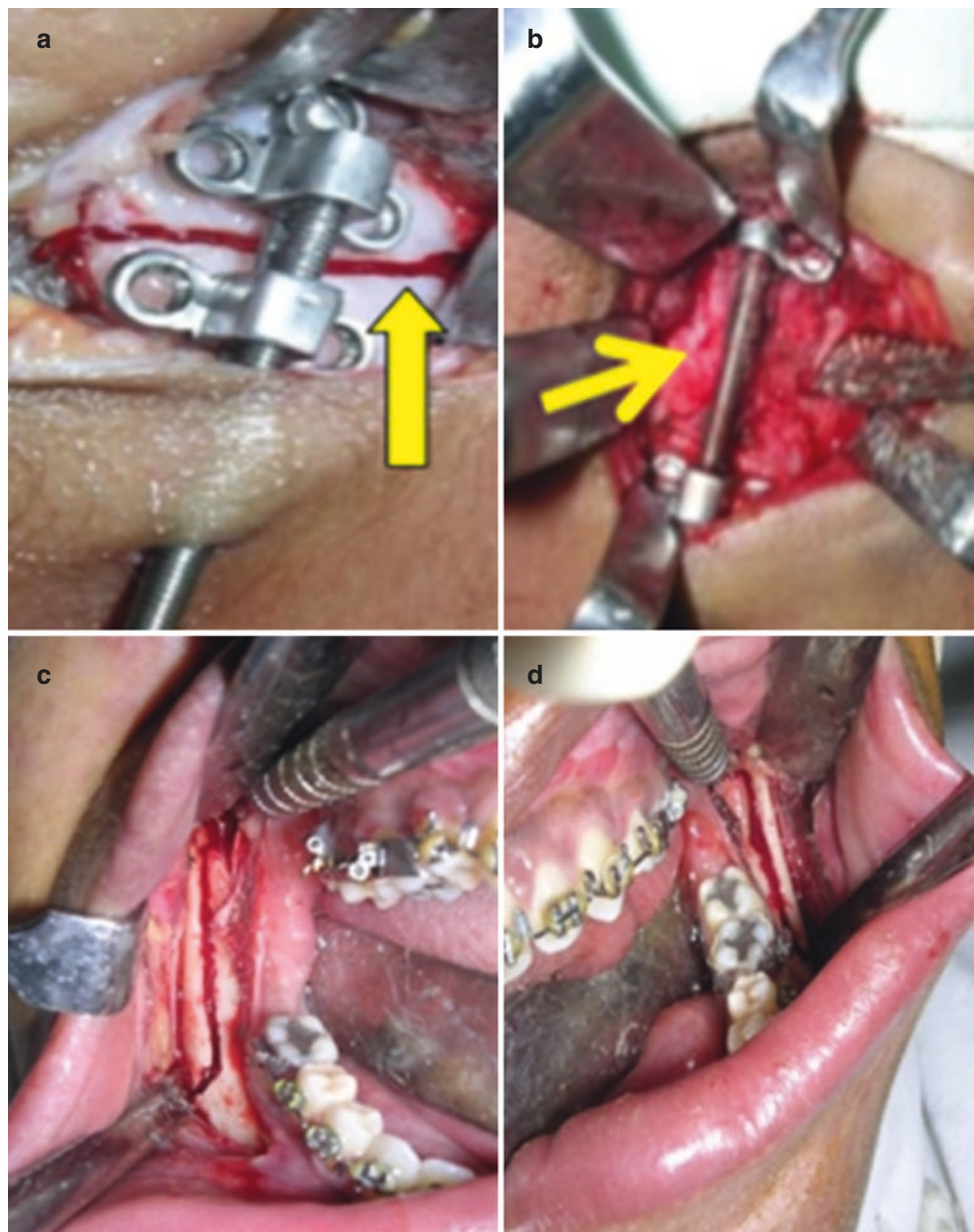
Fig. 70.22 (a–e) Case of facial asymmetry post-TMJ ankylosis treatment, due to resorption of costochondral graft. Note the exposed screw intraorally. Left side of mandibular arch fully telescoped inside the maxilla. (a) basal view showing gross asymmetry, (b) patient retaining good mouth opening after surgery for ankylosis, (c) Antero-posterior

skull view showing asymmetry on the left side with screw from earlier costo-chondral graft fixation, (d) photograph showing trans-oral exposure of screw and (e) malocclusion with midline shift to the right, dental crowding and left sided lingual cross-bite



©Association of Oral and Maxillofacial Surgeons of India

Fig. 70.23 (a, b) Stage 1 treatment in the same patient as in Fig. 70.22, left side vertical ramus distraction to establish equal ramal height. (a) Initial height of ramus prior to beginning distraction, (b) vertical lengthening of ramus after completion of distraction



©Association of Oral and Maxillofacial Surgeons of India

Fig. 70.24 (a–d) Second stage treatment in same patient as in Fig. 70.22: distractor removal with differential BSSO. (a) intra-operative photo from stage 1 surgery, showing osteotomy line for distraction (yel-

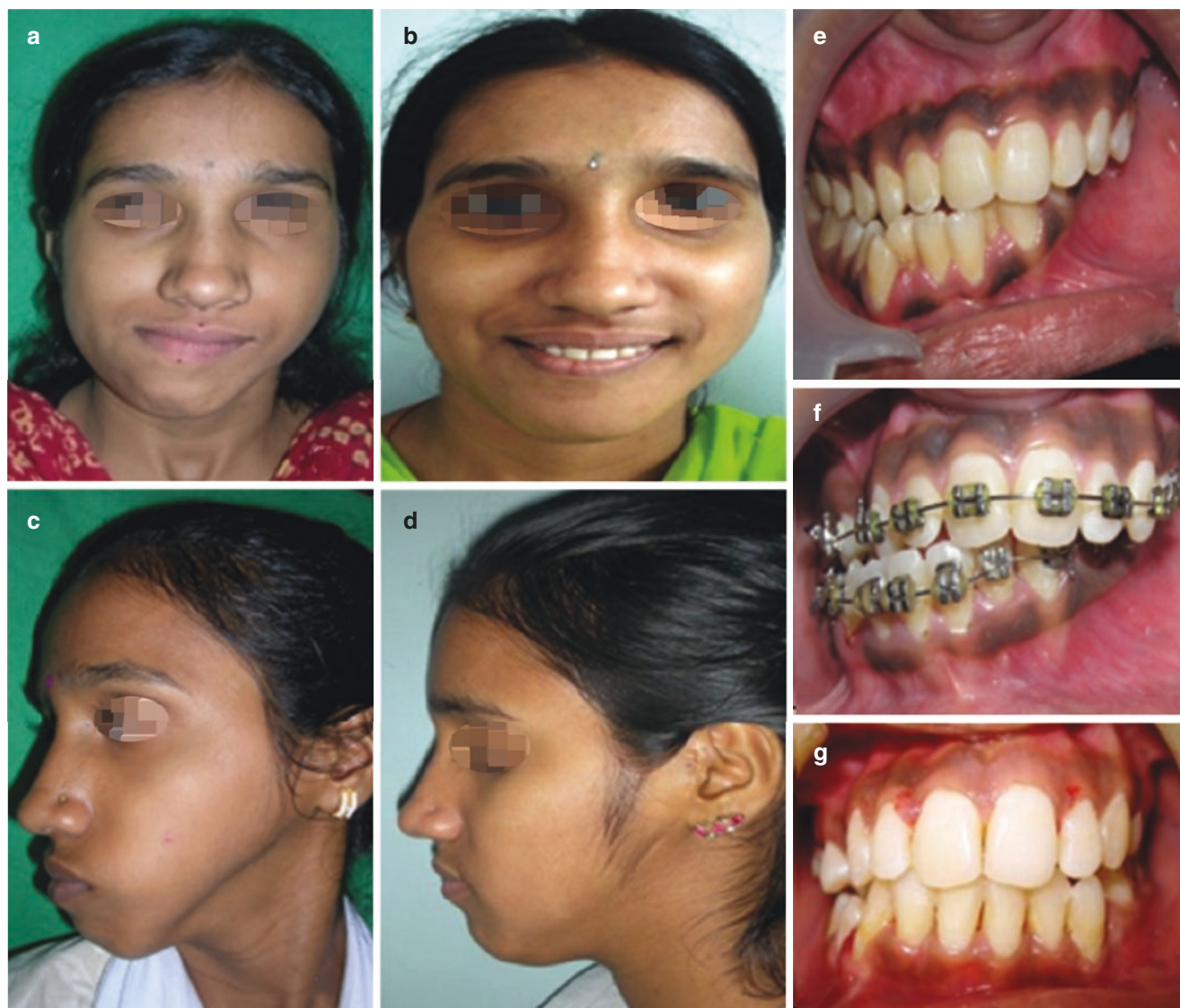low arrow), (b) intra-operative photo during distractor removal demonstrating new bone formation (yellow arrow), (c, d) intra-operative photos showing osteotomy cuts for BSSO

roots and mandibular canal was increased with displacement of the latter towards the lower border of the mandible on the right side. The right side vertical ramus appeared relatively increased height as compared to the left. Thickened trabecular pattern was also evident on the right side.

Management

Following preparation for the administration of GA and a scintigraphy report which did not reveal an active mandibular hyperplastic condyle on the right side, the patient was

prepared to be taken up for the procedure of an intraoral inferior border osteotomy. An intraoral vestibular incision was taken from 33 regions up to the external oblique ridge on the right side. Complete degloving was done to expose the inferior border in the anterior, body, and angle region of the mandible on the right side. Care was taken to identify the mental foramen and salvage the nerve. Methylene blue ink was used to mark the osteotomy line extending from the right central incisor posteriorly up to the angle region (Fig. 70.28a). It was correlated with the position of the neu-



©Association of Oral and Maxillofacial Surgeons of India

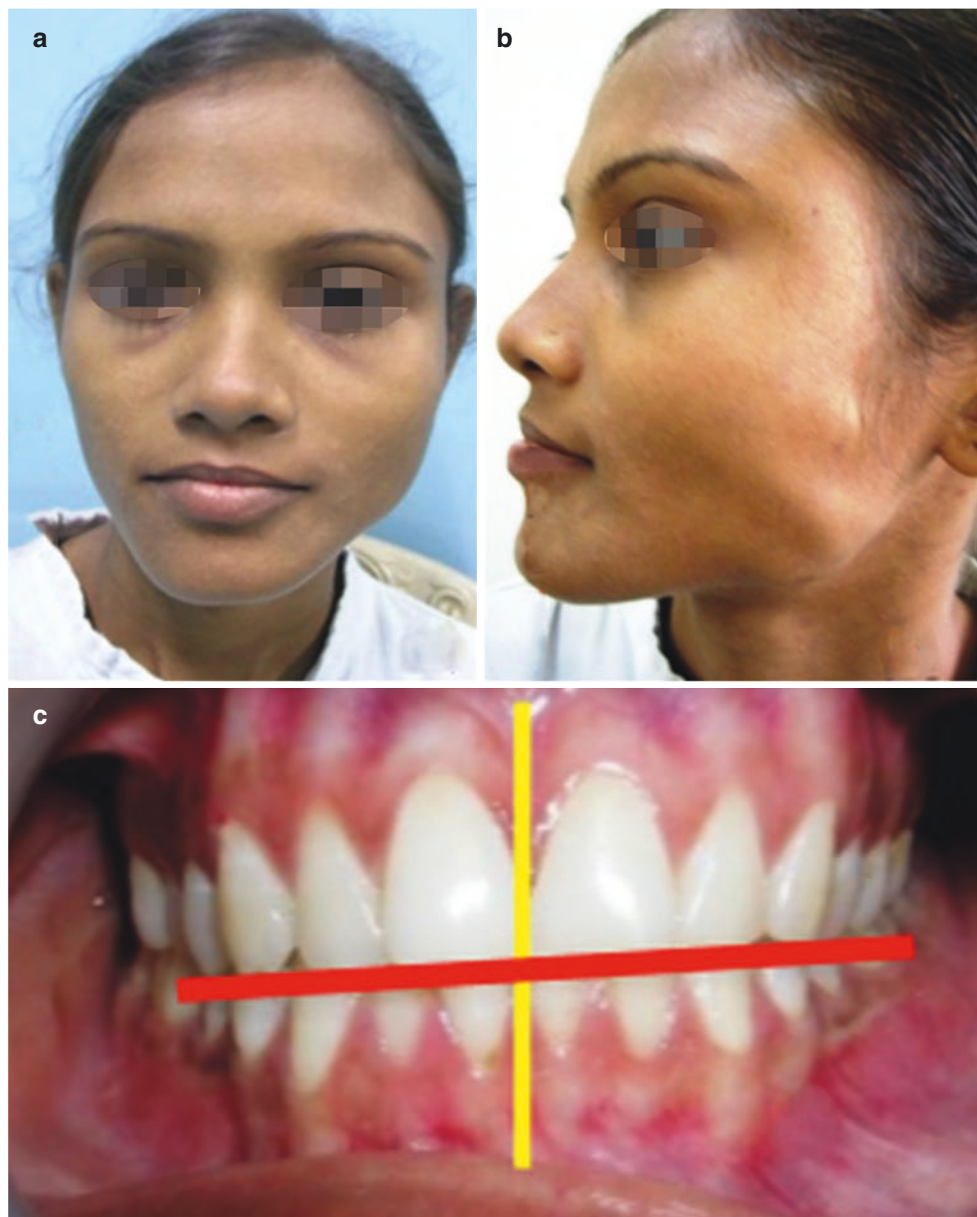Fig. 70.25 (a–g) Pre- and postoperative photographs of the same patient as in Fig. 70.22, showing restoration of symmetry and midline (a, b) pre and post-operative frontal photographs showing correction of asymmetry, (c, d) pre and post-operative profile photographs demonstrating increased vertical height of ramus, (e) pre-treatment intra oral

occlusion demonstrating severe shift in the dental midline with lingual crossbite on the left side, (f) orthodontic strap-up for dental and arch alignment, (g) post-treatment occlusion showing good dental rehabilitation

rovascular bundle, so as to prevent any damage to the same. The cut was initiated with a fine fissure bur under copious saline irrigation extending from buccal cortical plate to lingual cortical plate. With the help of an osteotome, the anterior cut was completed, and the lower inferior hyperplastic border was removed in one piece (Fig. 70.28b). The raw surface was smoothened with a vulcanite bur, and contouring was done to match the normal left side. The wound was closed in two layers with interrupted sutures using 3-0 vicryl. The surgical site was flushed with 2% povidone iodine solution.

For the masseteric hypertrophy on the left side, Botox [botulinum toxin Type A, Allergan™] powder was reconstituted with normal saline solution, pushed within the vial, and 30 units of it were administered using an insulin syringe and 30 gauge needle within the substance of the muscle, divided equally at three sites in a triangular fashion (Refer Chap. 33 and Fig. 33.10 for details on Botox injection to treat masseteric hypertrophy).

Complete correction of facial asymmetry with left side masseteric hypertrophy and right side condylar hyperplasia features was achieved with this surgical method (Fig. 70.29a, b).



©Association of Oral and Maxillofacial Surgeons of India

Fig. 70.26 (a, b) Frontal and profile views showing facial asymmetry due to condylar hyperplasia of the right side. (c) Occlusal view showing dental cant on account of condylar hyperplasia

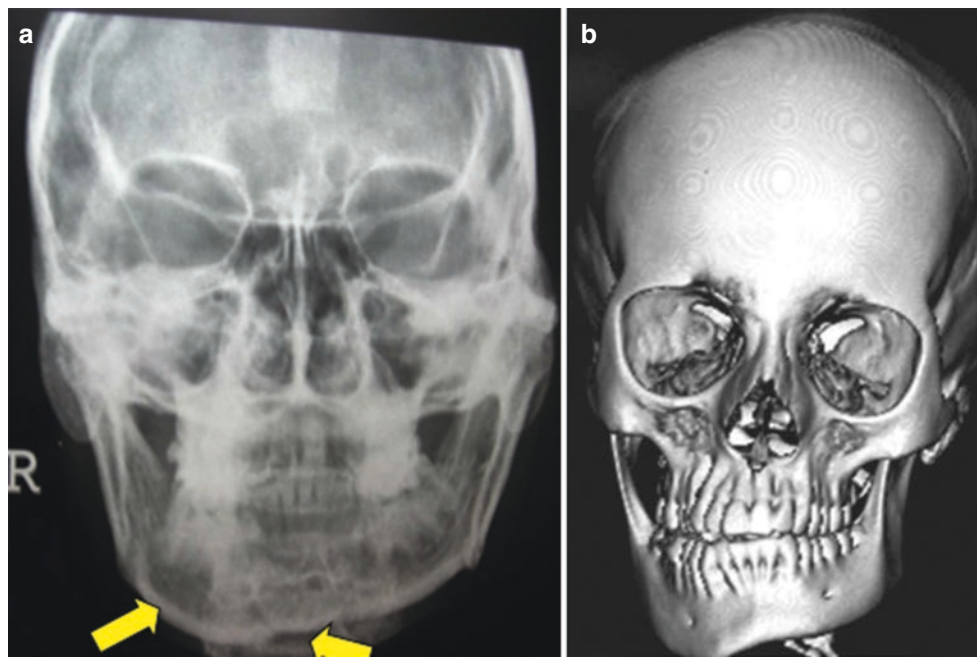
Case 2: Parry Romberg Syndrome (Figs. 70.30a, b, 70.31a, b, 70.32a, b, c, 70.33a–h and 70.34a–f)

An 18-year-old female patient reported with gradual disfigurement and shrinkage of the right side her face since last 8–9 years.

Clinical examination revealed an asymmetry of the face on the right side with a marked atrophy of facial soft tissue (Fig. 70.30a). Significant orbital dystopia along with a hypoplastic soft tissues in the right, evident on worm's view (Fig. 70.30b). Clinically, a deformed and

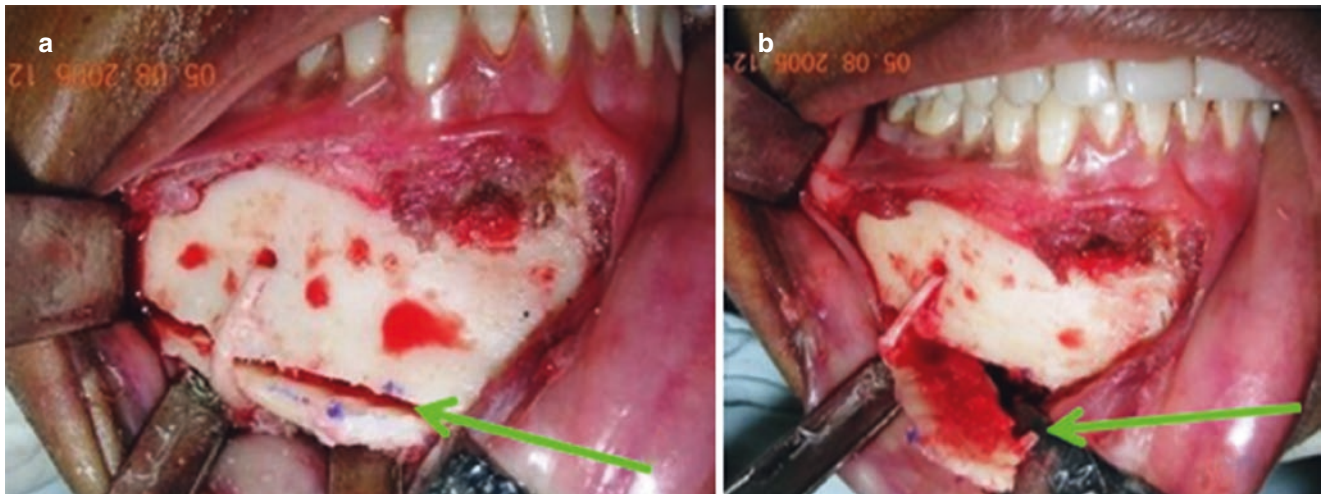
hypoplastic upper lip was seen with an increased vermilion show of the lower lip, resulting in a slanting rima oris. The right commissure, right ala of the nose, and the right supraorbital ridge region revealed obvious depression.

Intraoral examination revealed a missing upper right permanent canine along with crowding in the premolar region. Alveolar height in the maxillary right premolar region was reduced which was a pathognomonic sign of Parry Romberg (Fig. 70.31a, b). The occlusion was deranged, with a shift of the dental midline to the right.



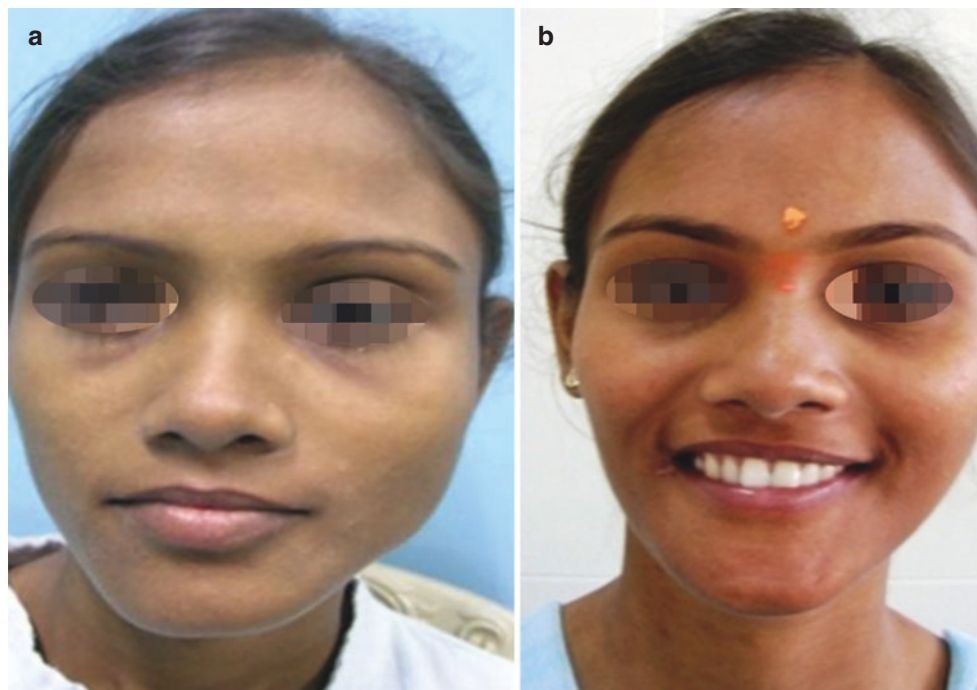
©Association of Oral and Maxillofacial Surgeons of India

Fig. 70.27 (a) PA mandible showing inferior border bowing on the right side and kink in chin region (yellow arrows) which stops at the midline. (b) 3D CT shows mild degree of tilting of chin and mandible toward the left side



©Association of Oral and Maxillofacial Surgeons of India

Fig. 70.28 (a, b) Inferior border osteotomy to remove the excessive contour below the mental nerve



©Association of Oral and Maxillofacial Surgeons of India

Fig. 70.29 (a) Pre- and (b) post-op correction in facial asymmetry. Reduction of fullness on left side and centralization of chin

Imaging studies revealed some degree of hypoplasia of mandible, zygoma, and maxilla on the right side. Presence of impacted permanent right maxillary canine was evident. The body-angle ramus, coronoid, and condylar process however appeared normal. Alveolar height was reduced in the right maxillary premolar region (Fig. 70.32a, b, c).

Management

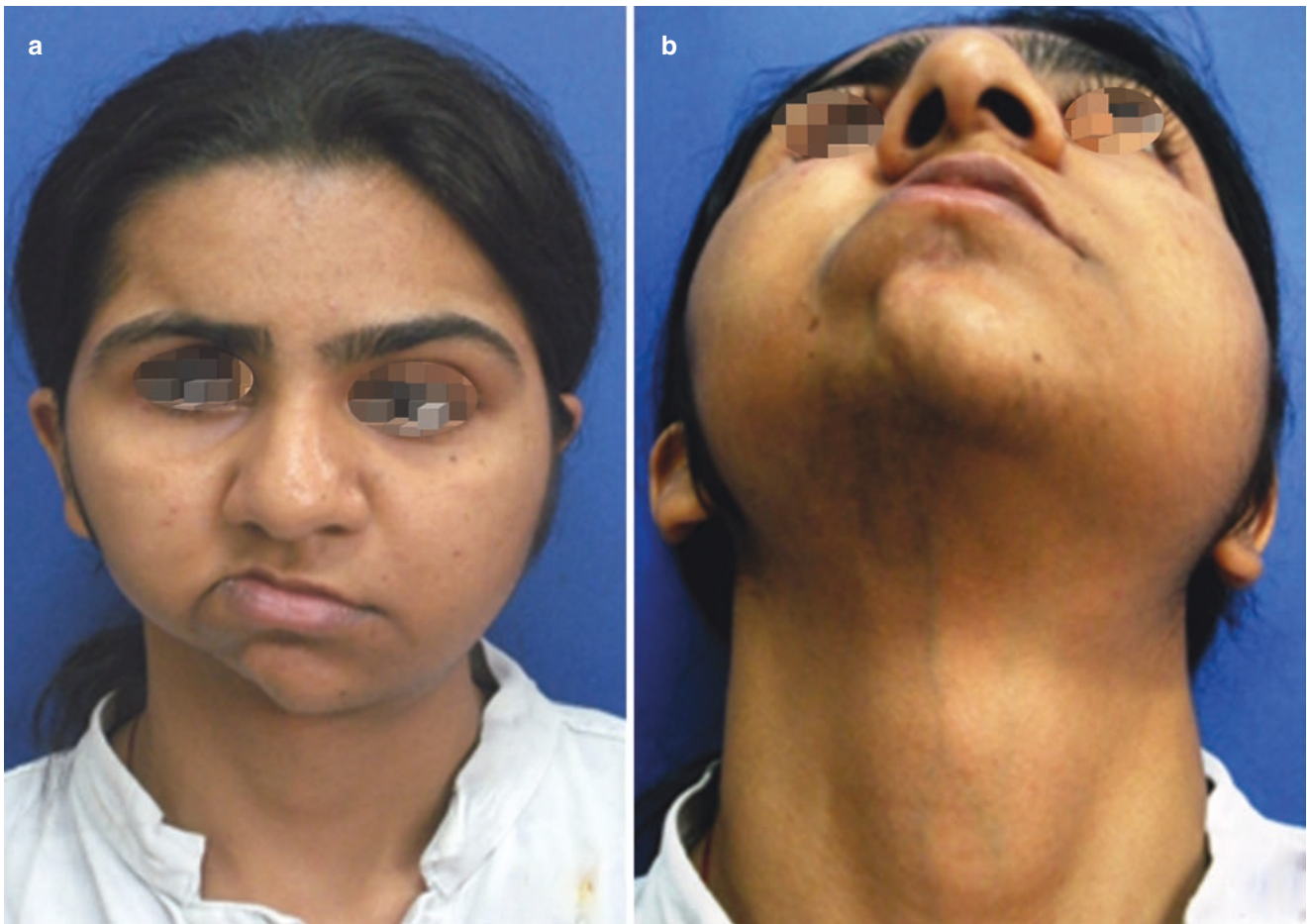The patient was prepared for GA administration for correction of facial asymmetry. A camouflage technique was planned wherein multiple Medpore© implants were used to fill up the deficient areas on the right side of her face in the right supra-orbital, right maxillary alveolar region in the canine, and premolar areas right parasymphysis region of the body of mandible and right side chin along with autologous lipo transfer to increase the volume of the upper lip. Two separate small incisions were taken in the submandibular region anteriorly and posteriorly keeping the intervening skin and tissues intact. Layerwise dissection was done to reach the angle, body, and the anterior regions of the mandible. Tunnelling was done between the two incisions so as to receive the pre-shaped Medpore© implant, which was inserted from the anterior site and was pushed posteriorly to sit on the body, angle, and a portion of the ramus. The implant was notched in the superior aspect, in the region of the mental nerve to prevent impingement of the same. Four long titanium screws were used to fix

the Medpore© implant on the body of the mandible on the right side (Fig. 70.33a). An additional half chin implant was placed to augment the deficient chin on the right side for achieving symmetry and was fixed with 2 long titanium screws (Fig. 70.33b). The incision sites were closed in two layers.

Another lateral eyebrow incision was taken on the right side (Fig. 70.33e). Dissection was done to expose the supra-orbital rim. Supraorbital foramen and nerve were identified. An infra-orbital rim Medpore© implant for the right side was inverted and placed on the right supraorbital region to augment this deficient area. Two long titanium screws were used to stabilize the Medpore© implants.

Intra-orally a vestibular incision was taken in the right premolar and canine region. A full-thickness mucoperiosteal flap was raised. The infra-orbital nerve was identified and protected. A paranasal Medpore© implant was fixed with 1 long titanium screw to give fullness in this region. The wound was sutured in two layers with 3-0 vicryl.

Periumbilical and medial thigh regions were prepared to harvest fat cells. Manual aspiration of the fat cells was done. Following the simple method of sedimentation, the fat cells were separated from the blood components (Fig. 70.33f). 2 mm incisions were taken on either side of the oral commissure. A large 16 gauge epidural needle attached to 10cc syringe was used to push the fat within the substance of the upper lip from either side (more on right side than on the left) increasing the



©Association of Oral and Maxillofacial Surgeons of India

Fig. 70.30 (a) Frontal view—right side reveals marked atrophy in the distribution of all three branches of trigeminal nerve. (b) Asymmetry of the inferior border evident on worm's-view involving soft and hard tissue

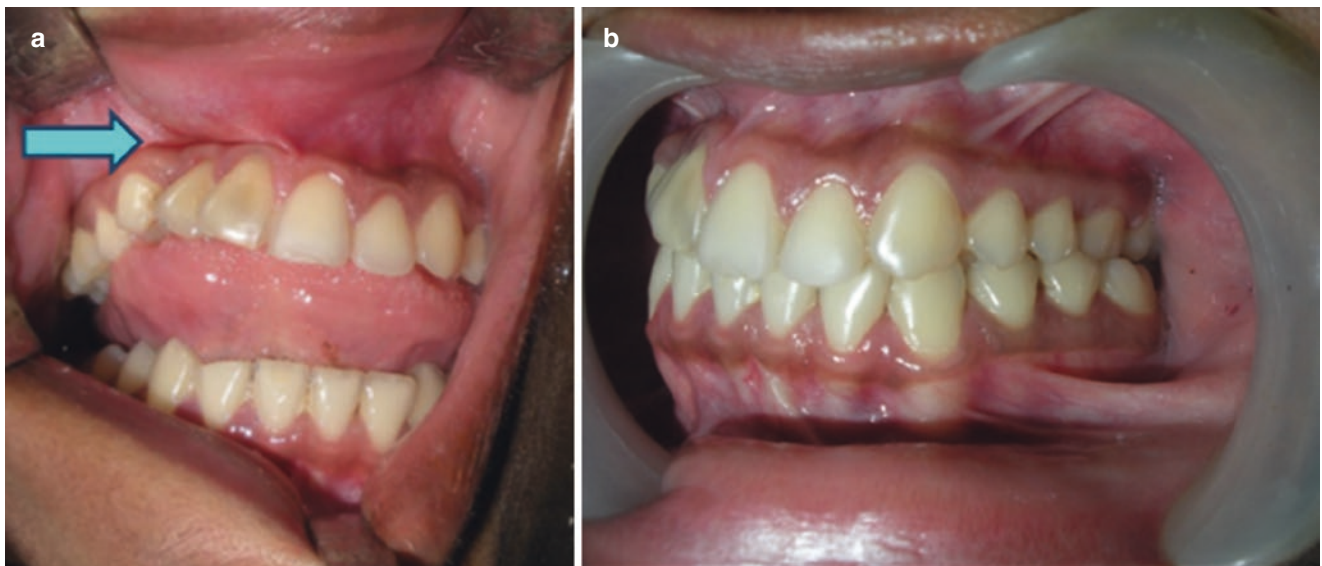

Fig. 70.31 (a, b) Intraoral examination of the same patient as in Fig. 70.30, reveals reduced alveolar height (blue arrow) in the right premolar region (a), as compared to the left side (b). Alveolar height reduction is an important clinical finding in Romberg's disease

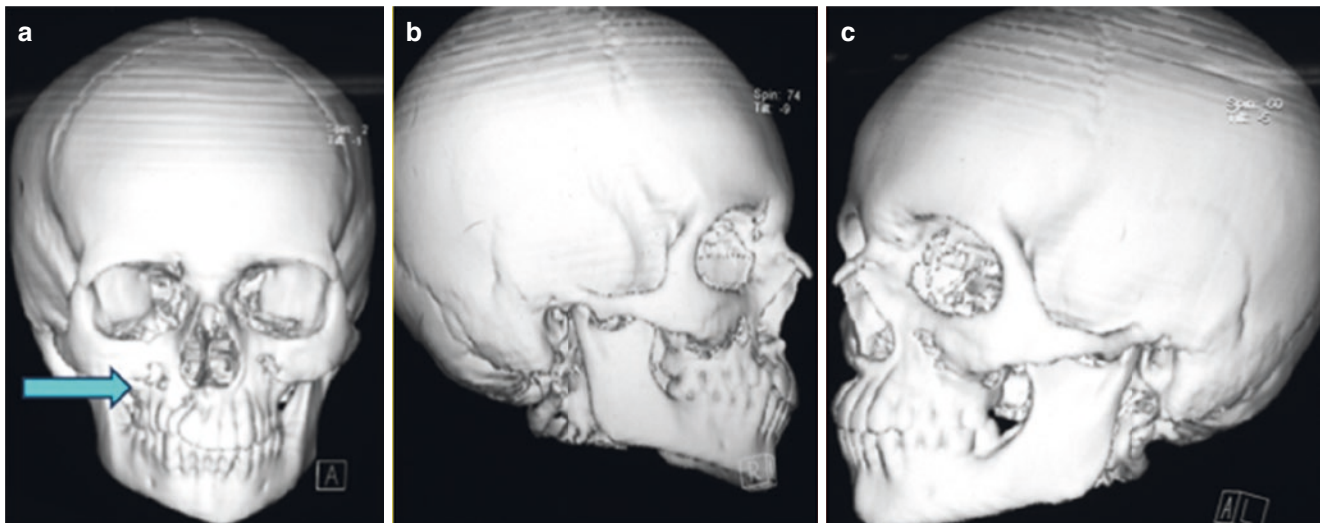
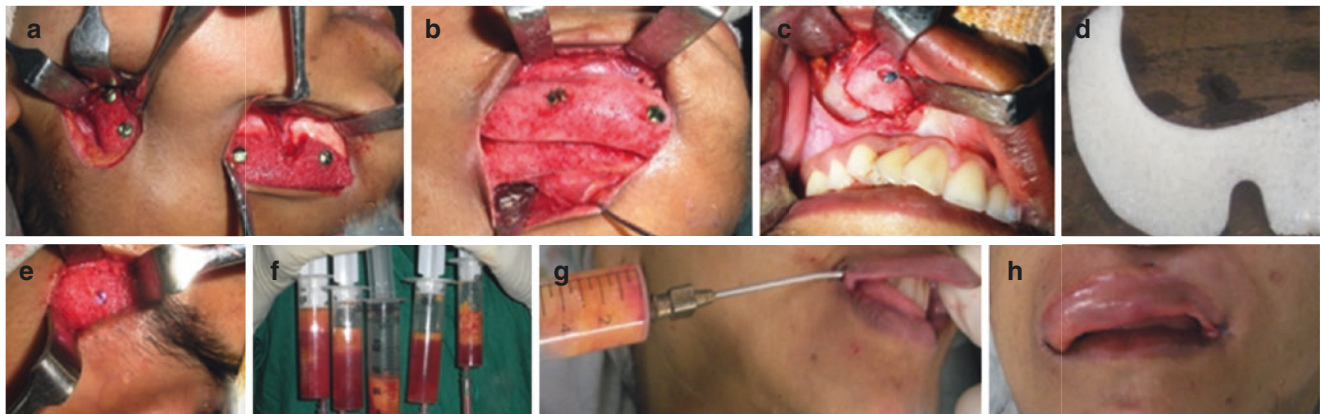


Fig. 70.32 (a, b) 3D CT of the patient in Fig. 70.30 reveals skeletal deficiency of alveolar height on right side (blue arrow), and reduction in vertical height of the ramus and body of the mandible on right side, (c) left side shows normal anatomy



©Association of Oral and Maxillofacial Surgeons of India

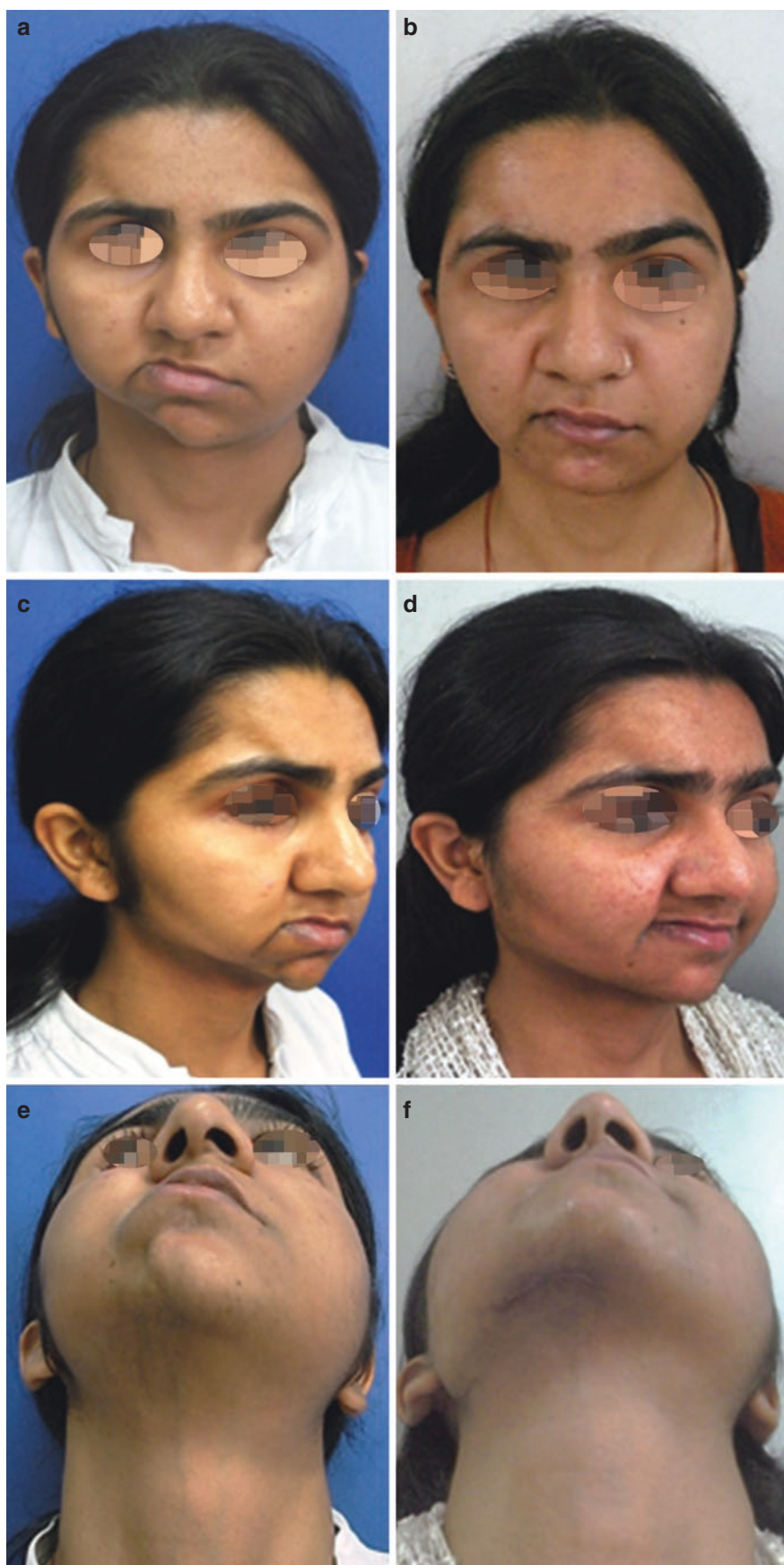Fig. 70.33 (a) Extra-oral incisions—submandibular incisions made anteriorly and posteriorly. Medpore implant in ramus and body fixed with four titanium screws. (b) Additional half chin implant fixed with two titanium screws on right side of chin region. (c) Paranasal and alveolar Medpore implant fixed through intra-oral approach with titanium screws. Infraorbital nerve protected. (d, e) Use of Medpore implant for

right side supra orbital rim. Notch placed superiorly to protect the supraorbital nerve. (f) Sedimentation to separate fat cells from blood components. Harvesting autologous fat grafts. (g) Introduction of fat cells into the upper lip through needle prick in right commissure. (h) Overcorrection achieved on table

volume of upper lip (Fig. 70.33g). A stitch on either side of the commissure was taken to prevent escape of fat cells (Fig. 70.33h). Overcorrection was done on table. Postoperatively, good facial symmetry was achieved with fullness at the deficient site using fat and implant (Fig. 70.34a–f).

For further case scenarios on management of facial asymmetry refer Figs. 68.19 and 68.38, in Chap. 68 on mandibular orthognathic procedures and Figs. 69.30, 69.31, 69.32 and 69.40 in Chap. 69 on maxillary orthognathic procedures.

Fig. 70.34 (a–f) Comparison of pre and post op results after 4 years. Satisfactory correction in facial asymmetry achieved. Pre (Fig. 70.30a) and post treatment frontal photographs (a, b) oblique facial views (c, d) and basal views (e, f) demonstrating better soft tissue balance and symmetry



References

- Little AC, Jones BC, De Bruine LM. Facial attractiveness: evolutionary based research. *Philos Trans R Soc Lond Ser B Biol Sci*. 2011;366(1571):1638–59.
- Thiesen G, Gribel BF, Freitas MPM. Facial asymmetry: a current review. *Dental Press J Orthod*. 2015;20(6):110–25.
- Chouinard AF, Kaban LB, Peacock ZS. Acquired abnormalities of the temporomandibular joint. *Oral Maxillofac Surg Clin North Am*. 2018;30(1):83–96.
- Wolford LM, Gonçalves JR. Condylar resorption of the temporomandibular joint: how do we treat it? *Oral Maxillofac Surg Clin North Am*. 2015;27(1):47–67.
- Pirttiniemi PM. Associations of mandibular and facial asymmetry: a review. *Am J Orthod Dentofac Orthop*. 1994;106:191–200.
- Bishara SE, Burkey PS, Kharouf JG. Dental and facial asymmetries: a review. *Angle Orthod*. 1994;64:89–98.
- Lundström A. Some asymmetries of the dental arches, jaws, and skull, and their etiological significance. *Am J Orthod*. 1961;47(2):81–106.
- Plint DA, Ellisdon PS. Facial asymmetries and mandibular displacements. *Br J Orthod*. 1974;5:227–35.
- Chia MS, Naini FB, Gill DS. The aetiology, diagnosis and management of mandibular asymmetry. *Ortho Update*. 2008;1(1):44–52.
- Haraguchi S, Iguchi Y, Takada K. Asymmetry of the face in orthodontic patients. *Angle Orthod*. 2008;78(3):421–6.
- Wolford LM. Facial asymmetry: diagnosis and treatment considerations. In: Fonseca's oral and maxillofacial surgery, vol. III. 3rd ed. St. Louis, MO: Saunders; 2017.
- Reyeneke JP. Basic guidelines for the diagnosis and treatment of specific dentofacial deformities. 2nd ed. New Malden: Quintessence Publishing; 2010.
- Cheong YW, Lo LJ. Facial asymmetry: etiology, evaluation, and management. *Chang Gung Med J*. 2011;34(4):341–51.
- Waite P, Urban S. Facial asymmetry. In: Peterson's principles of oral and maxillofacial surgery. 3rd ed. New York: McGraw-Hill Medical; 2012.
- Obwegeser HL, Makek MS. Hemimandibular hyperplasia: hemimandibular elongation. *J Maxillofac Surg*. 1986;14(4):183–208.
- Cohen MM Jr. Perspectives of craniofacial asymmetry. Part IV. Hemi-asymmetries. *Int J Oral Maxillofac Surg*. 1995;24:134–41.
- Kim JY, Jung HD, Jung YS, Hwang CJ, Park HS. A simple classification of facial asymmetry by TML system. *J Craniomaxillofac Surg*. 2014;42(4):313–20.
- Hwang HS. A new classification of facial asymmetry. In: McNamara JA, editor. Early orthodontic treatment: is the benefit worth the burden? Craniofacial growth series, vol. 44. Ann Arbor: University of Michigan; 2007. p. 269–94.
- Wolford LM, Movahed R, Perez DE. A classification system for conditions causing condylar hyperplasia. *J Oral Maxillofac Surg*. 2014;72(3):567–95.
- Srivastava D, Singh H, Mishra S, Sharma P, Kapoor P, Chandra L. Facial asymmetry revisited: part I-diagnosis and treatment planning. *J Oral Biol Craniofac Res*. 2018;8(1):40–3.
- Rodrigues DB, Castro V. Condylar hyperplasia of the temporomandibular joint. Types, treatment, and surgical implications. *Oral Maxillofac Surg Clin North Am*. 2015;27(1):155–67.
- Srivastava D, Singh H, Mishra S, Sharma P, Kapoor P, Chandra L. Facial asymmetry revisited: part I-diagnosis and treatment planning. *J Oral Biol Craniofac Res*. 2018;8(1):7–14.
- Cheong Y-W, Lo L-J. Facial asymmetry: etiology, evaluation, and management. *Chang Gung Med J*. 2011;34(1):341–51.
- Choi KY. Analysis of facial asymmetry. *Arch Craniofac Surg*. 2015;16(1):1.
- Photogrammetry [Internet]. Available from: <https://en.wikipedia.org/wiki/Photogrammetry>
- Heike CL, Upson K, Stuhau E, Weinberg SM. 3D digital stereophotogrammetry: a practical guide to facial image acquisition. *Head Face Med*. 2010;6(1):1–11.
- Stereolithography [Internet]. Available from: <https://en.wikipedia.org/wiki/Stereolithography>
- Farrell BB, Franco PB, Tucker MR. Virtual surgical planning in orthognathic surgery. *Oral Maxillofac Surg Clin North Am*. 2014;26(4):459–73.
- Nadershah M, Mehra P. Orthognathic surgery in the presence of temporomandibular dysfunction. What happens next? *Oral Maxillofac Surg Clin North Am*. 2015;27(1):11–26.
- Saridin CP, Raijmakers PGHM, Tuinzing DB, Becking AG. Bone scintigraphy as a diagnostic method in unilateral hyperactivity of the mandibular condyles: a review and meta-analysis of the literature. *Int J Oral Maxillofac Surg*. 2011;40(1):11–7.
- Cisneros GJ, Kaban LB. Computerized skeletal scintigraphy for assessment of mandibular asymmetry. *J Oral Maxillofac Surg*. 1984;42(8):513–20.
- Oron A, Arieli I, Pritsch T, Even-Sapir E, Halperin N, Agar G. SPECT versus planar scintigraphy as a clinical aid in evaluation of the elderly with knee pain. *ISRN Orthop*. 2013;2013:1–11.
- Laverick S, Bounds G, Wong WL. [18F]-fluoride positron emission tomography for imaging condylar hyperplasia. *Br J Oral Maxillofac Surg*. 2009;47(3):196–9.
- Srivastava D, Singh H, Mishra S, Sharma P, Kapoor P, Chandra L. Facial asymmetry revisited: part II-conceptualizing the management. *J Oral Biol Craniofac Res*. 2018;8(1):15–9.
- Costello BJ, Rivera RD, Shand J, Mooney M. Growth and development considerations for craniomaxillofacial surgery. *Oral Maxillofac Surg Clin North Am*. 2012;24(3):377–96.
- Pruzansky S. Not all dwarfed mandibles are alike. *Birth Defects*. 1969;5:120.
- Kaban LB, Padwa BL, Mulliken JB. Surgical correction of mandibular hypoplasia in hemifacial microsomia: the case for treatment in early childhood. *J Oral Maxillofac Surg*. 1998;56:628–38.
- Al-Moraissi EA, Wolford LM, Perez D, Laskin DM, Ellis E III. Does orthognathic surgery cause or cure temporomandibular disorders? A systematic review and meta-analysis Q2 Q24. *J Oral Maxillofac Surg*. 2017;75(9):1835–47.
- Bawane SS, Andrade NN. Hard and soft tissue changes following maxillary distraction osteogenesis and mandibular setback with bilateral sagittal split osteotomy. *J Maxillofac Oral Surg*. 2016;15(4):491–500.
- Posnick JC, Ricalde P, Ng P. A modified approach to “model planning” in orthognathic surgery for patients without a reliable centric relation. *J Oral Maxillofac Surg*. 2006;64(2):347–56.
- Guo J, Wang T, Han JJ, Jung S, Kook MS, Park HJ, Oh HK. Corrective outcome and transverse stability after orthognathic surgery using a surgery-first approach in mandibular prognathism with and without facial asymmetry. *Oral Surg Oral Med Oral Pathol Oral Radiol*. 2018;126(1):22–30.
- Schwartz HC. Efficient surgical management of mandibular asymmetry. *J Oral Maxillofac Surg*. 2011;69(3):645–54.
- Andrade NN, Aggarwal N, Mathai P, Nerurkar S. Versatility of unilateral prearthroplastic distraction osteogenesis in the correction of post-ankylosis facial deformities—a report of five different cases. *Oral Maxillofac Surg*. 2018;22(4):463–74.

44. Wolford LM, Karras SC, Mehra P. Considerations for orthognathic surgery during growth, part 1: mandibular deformities. *Am J Orthod Dentofac Orthop.* 2001;119(2):95–101.
45. Wolford LM, Karras SC, Mehra P. Considerations for orthognathic surgery during growth, part 2: maxillary deformities. *Am J Orthod Dentofac Orthop.* 2001;119(2):102–5.

Additional Reading

- Grummons DC, Kappeyne van de Coppello MA. A frontal asymmetry analysis. *Journal of Clinical Orthodontics: JCO.* 1987;21(7):448–465.

Open Access This chapter is licensed under the terms of the Creative Commons Attribution 4.0 International License (<http://creativecommons.org/licenses/by/4.0/>), which permits use, sharing, adaptation, distribution and reproduction in any medium or format, as long as you give appropriate credit to the original author(s) and the source, provide a link to the Creative Commons license and indicate if changes were made.

The images or other third party material in this chapter are included in the chapter's Creative Commons license, unless indicated otherwise in a credit line to the material. If material is not included in the chapter's Creative Commons license and your intended use is not permitted by statutory regulation or exceeds the permitted use, you will need to obtain permission directly from the copyright holder.

