

# Weight Preserving Image Registration for Monitoring Disease Progression in Lung CT

Vladlena Gorbunova<sup>1</sup>, Pechin Lo<sup>1</sup>, Haseem Ashraf<sup>4</sup>, Asger Dirksen<sup>4</sup>,  
Mads Nielsen<sup>1,3</sup>, and Marleen de Bruijne<sup>1,2</sup>

<sup>1</sup> Department of Computer Science, University of Copenhagen, Denmark

<sup>2</sup> Biomedical Imaging Group Rotterdam, Erasmus MC, Rotterdam, the Netherlands

<sup>3</sup> Nordic Bioscience A/S, Herlev, Denmark

<sup>4</sup> Department of Respiratory Medicine, Gentofte University Hospital, Denmark

**Abstract.** We present a new image registration based method for monitoring regional disease progression in longitudinal image studies of lung disease. A free-form image registration technique is used to match a baseline 3D CT lung scan onto a following scan. Areas with lower intensity in the following scan compared with intensities in the deformed baseline image indicate local loss of lung tissue that is associated with progression of emphysema. To account for differences in lung intensity owing to differences in the inspiration level in the two scans rather than disease progression, we propose to adjust the density of lung tissue with respect to local expansion or compression such that the total weight of the lungs is preserved during deformation. Our method provides a good estimation of regional destruction of lung tissue for subjects with a significant difference in inspiration level between CT scans and may result in a more sensitive measure of disease progression than standard quantitative CT measures.

## 1 Introduction

Chronic Obstructive Pulmonary Disease (COPD) is the fourth leading cause of death in the world [1]. COPD encompasses both small airway disease and emphysema which is characterized by the destruction of lung parenchyma. The current gold standard for diagnosing COPD is based on lung function tests (LFT) such as the forced expiratory volume in one second (FEV1) and forced vital capacity (FVC). These methods are well suited for diagnosing COPD but lack the sensitivity and reproducibility to detect mild emphysema or small changes in disease status.

CT analysis allows the quantification of emphysema with a higher accuracy, even in early stages. Emphysematous regions appear as areas with low-attenuation in CT scans of the lungs, suggesting that CT image intensities can be used to quantify the severity of emphysema. Averaged lung density,  $n$ -th percentile density, and relative area with attenuation below e.g. -910HU (emphysema index, RA-910HU) have all been successfully applied as emphysema measures. However, current CT emphysema measures have two major drawbacks: measurements are averaged over the complete lung region, which makes

it difficult to detect small, localized differences, and they are strongly influenced by variations in the inspiration level [2]. For accurate monitoring of disease development and progression one should be able to analyze regional changes. We propose to use image registration for this purpose. Non-rigid image registration of lung CT scans has previously been used as an aid in determining growth of lung nodules [3] but has to our knowledge not been applied to longitudinal studies of emphysema.

There exist two fundamentally different approaches to analyzing regional changes in longitudinal studies or image sequences using registration. One approach considers an almost perfect registration and subsequently analyzes the deformation field. This approach has for example been applied to lung SPECT and CT scans to analyze breathing motion [4]. The second approach aims at compensating for gross deformation caused by other factors not related to the disease process, and subsequently analyzes the differences in local appearance or intensity between the target and the registered image as a measure of disease progression. The second approach is taken in this paper; registration is used to correct for expected normal lung deformation and differences in inspiration level between scans, whereas the finer scale disease process of growing and merging emphysema bullae is revealed in the difference images.

In repeated breath-hold scans of the same subject, the difference in total lung volume between scans is often more than a half liter, even if the subjects are instructed to hold their breath at maximum inspiration. This has a large effect on the density of lung tissue in the CT scan and on common density derived measures of emphysema [2]. To correct for differences in inspiration level we used an assumption of total lung weight preservation throughout the respiratory cycle which was discussed previously in [5]. We propose to constrain the image registration to preserve local and global weight of lungs during deformation and adjust voxel intensity values with respect to local volume changes. A composition of affine and multi-level free-form registration was applied to align the baseline scan with the follow up and the obtained difference maps were analyzed for local tissue loss. The main advantages of the proposed method are: (a) it is robust to significant difference in total lung volume between baseline and follow-up scans; (b) it is capable of estimating regional destruction of lung tissue.

## 2 Image Registration Method

In this article we followed a common technique for registering medical images with considerable deformations. To correct for global differences in subject positioning and lung volume as well as essential local changes in the lungs, we applied a composition of global affine transform  $T_A$  and multi-level free-form B-Spline transforms  $T_{B-Spline}^i$ :

$$T_{final}(I_b) = T_A + \sum_{i=1}^3 T_{B-Spline}^u(I_b). \quad (1)$$

B-Spline image registration was successfully used in a large number of medical image registration tasks, see for example [6,7]. A composition of affine and free-form B-Spline transform with increasing grid resolution was applied to the baseline image for efficient image registration. We used a free-form multi-level B-Spline transform with third order B-spline basis functions. Based on segmented airways [8], corresponding carina points in the baseline and follow-up images were used to initialize the translation for the affine transformation.

For intra-subject registration of medical images of the same modality the mean sum of squared distances is a suitable similarity measure [9,10], given in the form

$$C(I_f, T(I_b)) = \frac{1}{|\Omega|} \|I_f - T(I_b)\|_{L_2}^2 = \frac{1}{|\Omega|} \int_{\Omega} [I_f - T(I_b)]^2 dx dy dz, \tag{2}$$

where  $I_f$  is the follow up image,  $I_b$  the baseline image and  $\Omega$  the region occupied by the follow up image, padded with 0 in the non-overlapping areas.

### 2.1 Weight-Preserving Cost Function

To allow for computation of the lung weight, first the lungs were segmented as described in [8]. The tissue density is adjusted with respect to the amount of expansion or compression that is given by the Jacobian determinant  $det(J)$  of imposed transformation. The large vessels were excluded by applying a threshold of  $\varepsilon = -380HU$ . The image intensities were shifted so that the intensity of air ( $-1000HU$ ) was set to 0 and thus stayed constant during the weight-preserving adjustments.

For affine registration we modified the mean sum of squared distances similarity measure (2) to preserve global lung weight as

$$C(I_f, T_A(I_b)) = \frac{1}{|\Omega|} \|I_f - \frac{w_{I_b}}{w_{T_A(I_b)}} T_A(I_b)\|_{L_2}^2, \tag{3}$$

in which  $w_{I_b}$  and  $w_{T(I_b)}$  are the total lung weight for the baseline and registered baseline image respectively and the weight is calculated as the sum of HU intensities inside both lungs and excluding the large vessels. The resulting registered image  $I_r$  was adjusted with respect to weight changes due to the affine transform:

$$I_r = \frac{1}{det(J_{T_A})} T_A(I_b(x, y, z)). \tag{4}$$

We also deformed the mask images of the lungs and vessels according to the acquired affine transform for use in further registration.

For the B-Spline transformations we preserved weight locally by adjusting the cost function (2) with respect to regional volume changes as expressed by the local value of the Jacobian of the transformation:

$$C(I_f, T_B(I_b)) = \frac{1}{|\Omega|} \int_{\Omega} [I_f - \frac{1}{det(J_{T_B}(x, y, z))} T_B(I_b)]^2 dx dy dz. \tag{5}$$

We imposed a reasonable constraint on Jacobian of local transformation  $0.5 \leq \det(J) \leq 2$ . The determinant of the Jacobian was computed via a finite difference scheme. The registered image was adjusted with respect to local volume changes similar to (4).

## 2.2 Measure of Disease Progression

We first subtracted the registered baseline image from the follow up, thus forming an intensity difference image. Negative areas then indicate local loss of lung tissue and thus progression of emphysema. To reduce the effect of noise and interpolation artifacts around vessel boundaries, the resulting difference maps were filtered with a median filter of size  $3 \times 3 \times 3$  and masked with the dilated vessel masks and segmented lung regions from both images.

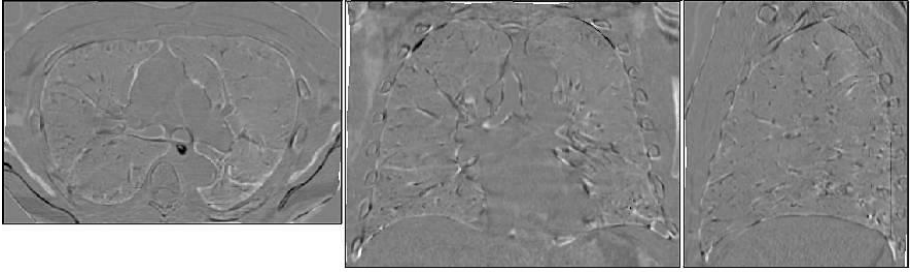
We assumed only voxels  $v = (x, y, z)$  with intensity difference within the interval  $(-500; -50)$  are disease-related. The reason for this is to remove artifacts due to interpolation and inaccurate registration and reduce the influence of noise. We compute an average density loss measure  $\mu$  over overlapping lungs volume  $V$ , by summing the disease-related intensity differences, given as:

$$\mu = \frac{1}{V} \sum_{\{v | I_f(v) - T_{final}(I_b)(v) \in (-500; -50)\}} I_f(v) - T_{final}(I_b)(v). \quad (6)$$

## 3 Experiments and Results

We evaluated the method on a set of 29 low dose CT image pairs collected from the Danish Lung Cancer Screening Trial. The images are selected such that they have a considerable difference in total lung volume ( $0.6 \pm 0.5L$ ) between baseline and follow up scans. The in-plane resolution was  $0.78 \times 0.78$  mm and the slice thickness was 1 mm. Image pairs have a time interval between baseline and follow up of approximately one year. Of these, at baseline 11 subjects had no COPD according to the GOLD guidelines [1], 5 were classified as having mild COPD, and 3 as moderate ( $FEV1/FVC = 66 \pm 10$ ). At follow up, 5 subjects are healthy, 11 have mild COPD and 3 have moderate COPD. 10 Image pairs were collected with a 3 month interval, of these 9 subjects had no COPD and 1 had mild COPD ( $FEV1/FVC = 74 \pm 4$ ).

To save computation time, the original CT lung scans were cropped according to the segmented lungs before image registration. A gradient descent algorithm was used for optimizing the parameters of the affine transform. The multi-level B-Spline transform was optimized using the L-BFGS method [7]. The first level was performed on a grid resolution of  $3 \times 3 \times 3$  grid points on the image domain, the second level on a resolution of  $6 \times 6 \times 6$  grid points and the finest level on a  $12 \times 12 \times 12$  or  $2.5 \times 2.5 \times 2.5$   $cm^3$  grid. The first two levels of the B-Spline transform were applied to smoothed and sub-sampled versions of the images whereas the finest level was applied to the original images. The image registration framework was implemented with ITK [11].



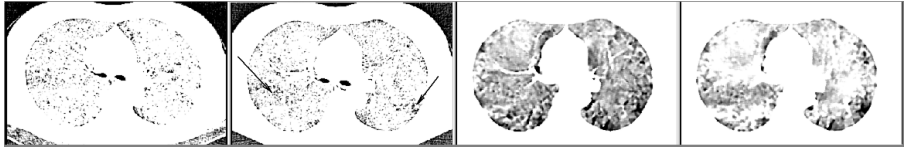
**Fig. 1.** A difference image illustrating an example of weight-preserving image registration, showing the deformed baseline image subtracted from the follow up image. From left to right the mid-axial, coronal and sagittal slice is shown.

Fig.1. shows the result of described image registration technique for an arbitrary subject. Differences in subject positioning within the CT scanner and part of the changes in lung volume were corrected via affine registration. The first level of the B-Spline transformation aligned global lung structures such as the lobes and diaphragm. The second level performed on the same resolution as pulmonary segments and adjusted internal lung deformations. Finally, the finest level corrects for deformations in the subsegmental level. Fig.1. shows clearly that the majority of internal lung structures is aligned with about 2-3 voxels accuracy; only a few misalignments near the lung and bronchial tree borders remain.

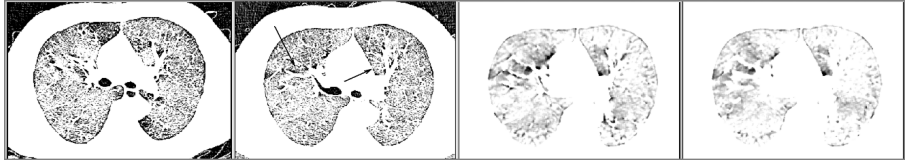
To verify the preservation of weight during the registration procedure, we compute the lung weight for standard and weight-preserving registered images and compare it with corresponding original image characteristics. The mean squared difference between the lung weight of the original baseline image and the registered image for standard image registration is  $1.18 \cdot 10^{-2}$ kg, two times more than for the proposed weight-preserving registration technique ( $5.09 \cdot 10^{-3}$ kg).

Examples of obtained local disease progression maps for four subjects with various values of differences in total lung volume and LFT are shown in Fig.2. The areas outside the lung and the vessel masks were excluded from the difference maps. Representative axial slices were chosen close to the carina point.

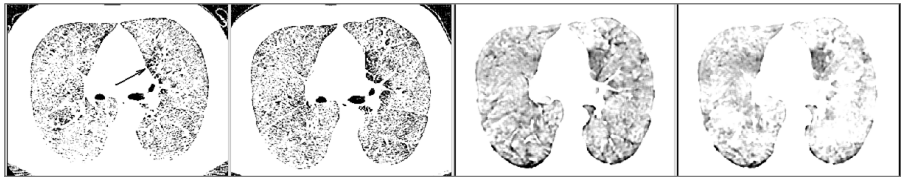
The resulting measure of disease progression is correlated to changes in RA-910HU and difference in FEV1 between baseline and follow up visits. Scattered plots are shown in Fig.3. We expect a positive correlation between our measure of disease progression and annual difference in FEV1 but not perfect, since this measure is known to vary substantially [12]. The correlation coefficient between annual difference in FEV1 and the registration based measure for standard registration  $\rho_{diffFEV1,\mu} = 0.1$  ( $p = 0.69$ ) and for weight-preserving registration  $\rho_{diffFEV1,\mu} = 0.47$  ( $p = 0.04$ ). The correlation coefficient between RA-910HU and registration based measurement for standard case  $\rho_{RA-910,\mu} = 0.82$  ( $p < 0.01$ ) and for weight-preserving registration  $\rho_{RA-910,\mu} = 0.73$  ( $p < 0.01$ ). The correlation coefficient between RA-910HU and annual difference in FEV1  $\rho_{diffFEV1,RA-910} = 0.04$  ( $p = 0.87$ ).



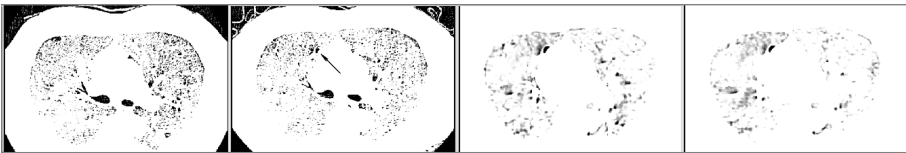
(a) Patient with  $\Delta TLV = 0.64L$ , mean FEV1/FVC = 69 and decrease in FEV1/FVC = -9.3



(b) Patient with  $\Delta TLV = 0.48L$ , mean FEV1/FVC = 68 and decrease in FEV1/FVC = -7.5



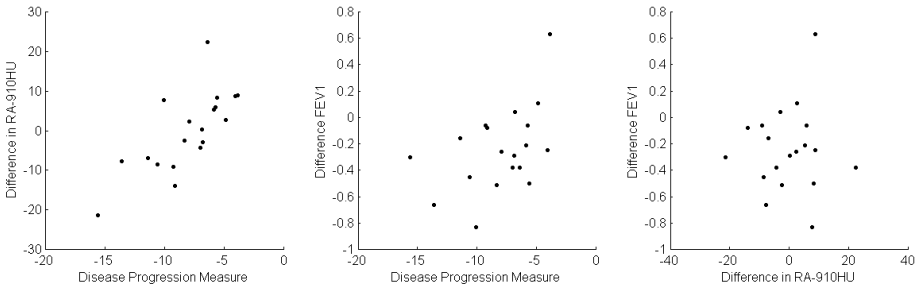
(c) Patient with  $\Delta TLV = 1.06L$ , mean FEV1/FVC = 65 and decrease in FEV1/FVC = -11.2



(d) Patient with  $\Delta TLV = 0.39L$ , mean FEV1/FVC = 69 and decrease in FEV1/FVC = -0.3

**Fig. 2.** Left most column shows an axial slice of a baseline scan; second column shows the most corresponding slice on the follow up scan with notable regions of emphysema progression indicated by arrows; third column shows the corresponding slice in difference image for the standard image registration technique; most right column shows difference image for weight-preserving image registration. The original scans were both thresholded at -910HU to reveal emphysematous areas; the difference images were median filtered and viewed at intensity window: 0 to -200.

To estimate influence of the inspiration level for the standard and weight-preserving image registration techniques we computed the correlation coefficients between difference in total lung volume and proposed disease progression measure for subjects scanned with 3 month interval. The correlation coefficient between the difference in total lung volume and the registration based measure for standard registration  $\rho_{diffTV,\mu} = 0.92$  ( $p < 0.01$ ) and for weight-preserving registration  $\rho_{diffTV,\mu} = 0.51$  ( $p = 0.14$ ).



**Fig. 3.** Relationship between annual difference in FEV1, difference in RA-910HU, and averaged weight loss in HU computed for the weight-preserving image registration for a group with 1 year time interval

## 4 Discussion and Conclusions

The proposed image registration method performed well for cases with considerable total difference in lung volume between baseline and follow up scans, both weight-preserving and standard registration generally align internal lung structures within 2mm.

The proposed weight-preserving image registration maintained the total weight of the lungs better than a standard registration approach. Remaining deviation between the original and registered image weight occurred due to natural limitations of the image registration technique such as the smoothing effect caused by linear interpolation and B-spline transformation.

The first three subjects in Fig.2. had a substantial increase in total lung volume from baseline to follow up, causing RA-910HU as well as standard registration to overestimate the changes in emphysema. The weight-preserving difference maps appear less dark in areas where there is no apparent disease progression in the original images. The darker areas in the weight-preserving difference maps correspond to localized areas of local emphysema progression clearly visible in the original images, while the difference maps based on standard image registration suggest a more diffuse tissue loss in the entire lung region. In the fourth case, where the difference in total lung volume was relatively small, both methods performed similar.

Comparison of the average local tissue loss with RA-910HU revealed a good, but not perfect correlation which indicates that the two measures may carry different information. Although we found low correlations with annual difference in FEV1 in this small sample, the measure based on weight preserving registration does seem to agree better with annual difference in FEV1 than do RA-910 and local progression measured using standard registration. This suggests that the proposed method may be more sensitive to subtle changes in disease status. It should be noted that the annual loss of tissue in most subjects with emphysema is very low, especially among normal smokers and mild COPD subjects, which constituted the majority of our test population. In future work we will investigate the proposed measures in a larger sample and with longer follow-up times.



To conclude, we propose an image registration based method for quantification of COPD disease progression which can estimate local destruction of lungs tissue and is less effected by differences in inspiration level than currently available methods.

**Acknowledgements.** This work is financially supported by the Danish Council for Strategic Research under the Programme Commission for Nanoscience and Technology, Biotechnology and IT (NABIIT), the Netherlands Organisation for Scientific Research (NWO), and AstraZeneca, Lund, Sweden.

## References

1. Rabe, K., et al.: Global strategy for the diagnosis, management, and prevention of chronic obstructive pulmonary disease gold executive summary. *Am. J. Respir. Crit. Care Med.* 176, 532–555 (2007)
2. Gietema, H., Schilham, A., van Ginneken, B., van Klaveren, R., Lammers, J., Prokop, M.: Monitoring of smoking-induced emphysema with CT in a lung cancer screening setting: Detection of real increase in extent of emphysema. *Radiology* 244, 3, 890–897 (2007)
3. Sluimer, I., Schilham, A., Prokop, M., van Ginneken, B.: Computer analysis of computed tomography scans of the lung: A survey. *IEEE Transactions on Medical Imaging* 25(4), 385–405 (2006)
4. Christensen, G.E., Song, J.H., Lu, W., Naqa, I.E., Low, D.A.: Tracking lung tissue motion and expansion/compression with inverse consistent image registration and spirometry. *Med. Phys.* 34(6), 2155–2164 (2007)
5. Shaker, S.B., Dirksen, A., Laursen, L.C., Skovgaard, L.T., Holstein-Rathlou, N.H.: Volume adjustment of lung density by computed tomography scans in patients with emphysema. *Acta Radiologica* 4 (2004)
6. Rueckert, D., Sonoda, L.I., Hayes, C., Hill, D.L.G., Leach, M.O., Hawkes, D.J.: Nonrigid registration using free-form deformations: Application to breast MR images. *IEEE Transaction on medical imaging* 18, 712–722 (1999)
7. Mattes, D., Haynor, D., Vesselle, H., Lewellen, T., Eubank, W.: PET-CT image registration in the chest using free-form deformations. *IEEE Transactions on Medical Imaging* 22, 120–128 (2003)
8. Lo, P., de Bruijne, M.: Voxel classification based airway tree segmentation. In: *Medical Imaging: Image Processing*, vol. 6914. SPIE (2008)
9. Hill, D.: Medical image registration review. *Phys. Med. Biol.* 46 (2001)
10. Modersitzki, J.: *Numerical Methods for Image Registration*. Oxford University Press, Oxford (2004)
11. ITK: Insight Segmentation and Registration Toolkit, <http://www.itk.org/>
12. Stolk, J., et al.: Progression parameters for emphysema: a clinical investigation. *Respir. Med.* 101(9), 1924–1930 (2007)