



# Imaging of Testicular and Scrotal Masses: The Essentials

# 24

Andreas G. Wibmer and Hebert Alberto Vargas

## Learning Objectives

- To identify the clinical scenarios where imaging of the testes and scrotum is indicated
- To learn the association between imaging features and the management of patients with testicular and scrotal masses

- Their age distribution overlaps with most scrotal and testicular malignancies, and asymptomatic neoplasms can be incidentally identified on imaging.
- About one third of scrotal/testicular malignancies can present with scrotal pain.
- Testicular infection, hematomas, and testicular infarcts can be focal and mimic testicular neoplasms, although the latter are commonly more vascularized on Doppler US. In the right clinical setting and absence of internal vascularity, focal infarct, hematoma, or infection might be an appropriate differential diagnosis and avoid futile surgery. However, these cases need to be followed up closely to document involution and exclude malignancy.

## 24.1 Clinical Scenarios Where Imaging Is Indicated

The first key to a meaningful radiology report is to be aware of the clinical indication for which the imaging study was requested.

### 24.1.1 Scrotal Pain With or Without a Palpable Mass

Infection (i.e., epididymitis/orchitis), torsion of the testis or testicular appendage, vascular pathologies (e.g., varicocele), hydrocele, and trauma are the most common causes of scrotal pain. Ultrasound (US) allows differentiation from testicular neoplasms and helps narrow the differential diagnosis in clinically equivocal cases. From an oncologic perspective, a few factors should be considered before contemplating these diagnoses:

---

A. G. Wibmer · H. A. Vargas (✉)  
Radiology- Memorial Sloan Kettering Cancer Center,  
New York, NY, USA  
e-mail: [wibmera@mskcc.org](mailto:wibmera@mskcc.org); [vargasah@mskcc.org](mailto:vargasah@mskcc.org)

### 24.1.2 Palpable Painless or Incidental Scrotal Mass

In this scenario, the first and most important task of imaging is localizing the mass to differentiate testicular from extra-testicular origin. In equivocal cases on US, magnetic resonance imaging (MRI) may be used as a problem-solving tool. As a second step, US (and in some selected cases MRI) may narrow the differential diagnosis, most importantly by identifying cysts, cyst-like lesions, and other benign entities with typical appearance (described below). In the absence of unequivocally benign imaging findings, it is important to clearly convey the suspicion for a malignant neoplasm to the referring physician. In case of a testicular mass, this often triggers an intervention (orchietomy), as further management hinges on adequate histopathologic characterization, which is not always possible through biopsies due to the microscopic heterogeneity of many testicular cancers.

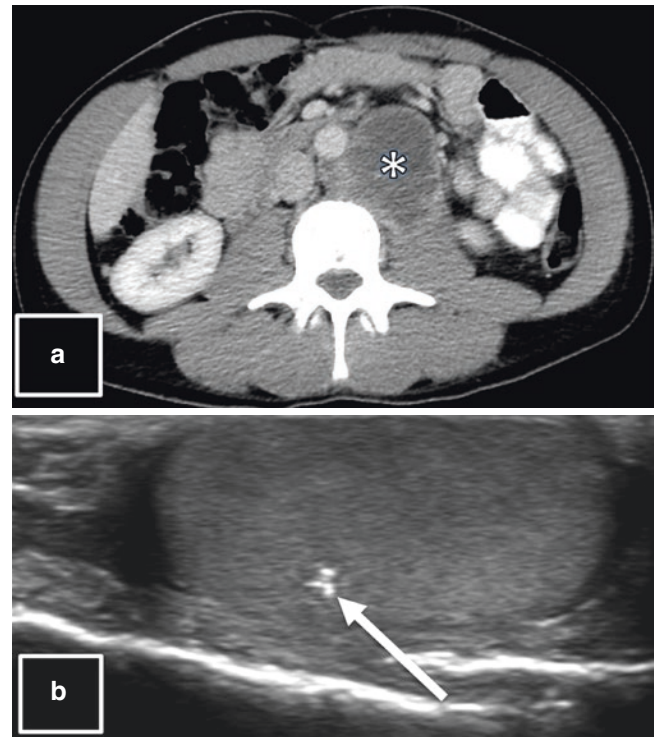
### 24.1.3 Isolated Retroperitoneal Lymphadenopathy

Lymphoma, extragonadal germ cell tumors, and testicular cancer metastases are the most common etiology for isolated retroperitoneal lymphadenopathy. Screening testicular US is routinely performed in this scenario. In case of testicular cancer, for which retroperitoneal nodes are the first lymphatic draining points and considered regional spread (i.e., “N”) in the TNM staging system, the spatial distribution of the retroperitoneal disease allows for some suggestions on the side of the testicular primary. Left-sided tumors typically metastasize to left para-aortic and pre-aortic nodes, while right-sided cancers metastasize to nodes around the inferior vena cava, including inter-aortocaval nodes. These considerations may seem somewhat academic for the reporting radiologist, who will diligently screen both testes anyway, not least due to the possibility of synchronous bilateral testicular cancers, seen in about 0.6% of all cases [1]. When confronted with equivocal testicular imaging findings, however, this information might help to reach a sound conclusion. If a testicular mass is identified, the objectives of imaging are similar to those described in the previous paragraph. Beyond specific imaging characteristics of some entities, which will be described below, the following facts might be helpful while interpreting these scans:

- Some types of primary testicular cancers, although widely metastatic, might be very small or involuted. On imaging, these primary tumors can be undetectable, or appear as small masses or focal calcifications, a phenomenon that has been referred to as “burned-out” primary tumor (Fig. 24.1).
- Some testicular cancers produce high levels of serum tumor markers, most notably alpha-fetoprotein (AFP), human chorionic gonadotropin (hCG), and lactate dehydrogenase (LDH). Although of limited sensitivity and specificity, high levels of these markers indicate a testicular origin of retroperitoneal lymphadenopathy and might help the radiologist to interpret equivocal imaging findings.

### 24.1.4 Follow-Up After Curative Treatment of Testicular Cancer

Patients with treated testicular cancer are at  $\geq 10$ -fold increased risk for developing contralateral metachronous cancer with a 15-year cumulative incidence of 1.9% [1]. This elevated pretest probability should be considered when performing surveillance studies. Patients having undergone



**Fig. 24.1** A 38-year-old with hip pain. (a) CT of the abdomen and pelvis shows left para-aortic and pre-aortic lymphadenopathy (asterisk), raising the suspicion for metastatic left-sided testicular cancer. (b) US of the left scrotum shows an intratesticular focal calcification (arrow); the right testis was unremarkable (not shown). Histopathology of the left orchiectomy specimen confirmed a “burned-out” germ cell tumor

treatment, particularly those who had metastatic disease, will also need follow-up imaging exams of other parts of the body. In this scenario, the following points deserve consideration:

- Most recurrences occur within the first 2 years after treatment. Late relapses, although less common, have been reported more than 5 years after treatment.
- The most common sites of recurrence are the retroperitoneal lymph nodes. Follow-up studies, especially computed tomography (CT), often spare the pelvis to minimize radiation dose.
  - CAVEAT: In patients with any kind of surgery involving the scrotum or inguinal canal (e.g., hernia repair, orchiopexy, or others), lymphatic drainage is altered, and recurrences can occur in variable anatomic patterns, including inguinal lymph node involvement.
  - In patients initially treated with adequate retroperitoneal lymph node dissection, retroperitoneal recurrence is rare. These patients are more likely to develop lung metastases.

- The most common site of organ metastases is the lung, and CT of the chest is more sensitive and specific for their detection than radiographs.
- After chemo- and/or radiotherapy, there is an increased long-term risk for secondary malignancies, most commonly cancers of the stomach, pancreas, urinary bladder, colon, lung, and esophagus and malignant mesothelioma of the pleura [2].

## 24.2 Imaging Characterization of Testicular and Scrotal Masses

Ultrasound is the initial imaging examination of choice for testicular and scrotal abnormalities; MRI may serve as a diagnostic adjuvant in selected cases. The main task of imaging – and also key to characterization – is to localize the mass. Masses arising within the testis have a higher likelihood of malignancy than those occurring in extra-testicular sites, including the epididymis (although there are some exceptions, as outlined below).


### 24.2.1 Testicular Masses

#### 24.2.1.1 Testicular Malignancies

Are typically heterogeneously hypoechoic compared to normal testicular tissue on US. They are well-defined, often lobulated lesions with internal blood flow detectable on Doppler US (Figs. 24.2 and 24.3). The likelihood of malignancy is high if all these features are present; and this high level of suspicion must be expressed in the radiology report. Characterization of histologic subtypes based on imaging is currently not possible; thus orchiectomy is typically the next step for most of these patients. These imaging features are not specific for testicular cancer and might also be encountered in benign or nonneoplastic tumor mimics (Fig. 24.4). The following paragraphs describe typical imaging features of more common benign and nonneoplastic testicular masses that may allow for confident exclusion of malignancy based on imaging.

#### 24.2.1.2 Testicular Microlithiasis

This frequently encountered entity is defined as the presence of five or more echogenic, non-shadowing foci <3 mm per testis (Fig. 24.5). Although it can be associated with testicular cancer, the European Society of Urogenital Radiology recommends against follow-up of isolated microlithiasis in the absence of risk factors (i.e., personal or family history of



**Fig. 24.2** A 38-year-old with a painless palpable right scrotal mass. (a) Gray-scale US of the scrotum shows microlithiasis and an intratesticular, well-circumscribed, lobulated, heterogeneously hypoechoic mass (arrows) with (b) internal vascularity on Doppler US. These features are the hallmarks of a malignant testicular neoplasm; the final diagnosis of seminoma was established after orchiectomy

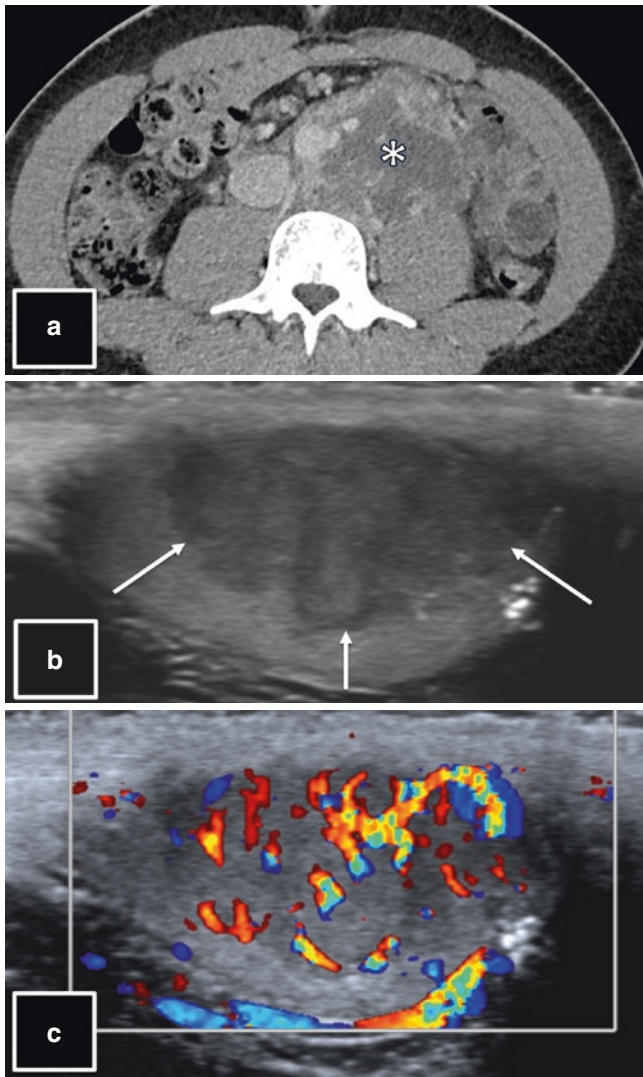
germ cell tumor, testicular atrophy <12 mL, history of mal-descent or orchiopexy) [3].

#### 24.2.1.3 Cystic Testicular Lesions

Similar to other organ systems, cysts in the testes are well-defined, homogeneously hypoechoic lesions with posterior acoustic enhancement on US (Fig. 24.6). Complex cysts have some degree of internal echogenicity. However, all cysts lack internal vascularity on Doppler US. The differentiation of tunica albuginea cysts which are found in a peripheral or paratesticular location vs. central cysts has no clinical significance. Ectasia of the rete testis is typically encountered in older men and appears as a cluster of multiple small cysts and tubules along the testicular mediastinum (Fig. 24.7). Testicular hematomas and abscesses can have large cystic components and, if considered as a differential diagnosis in the appropriate clinical setting, always need close follow-up. Cystic changes can be seen in testicular malignancies; however, purely cystic cancers are exceedingly rare.

#### 24.2.1.4 Epidermoid Cysts

This benign lesion can have typical features on US allowing for confident diagnosis in most cases. Multiple concentric

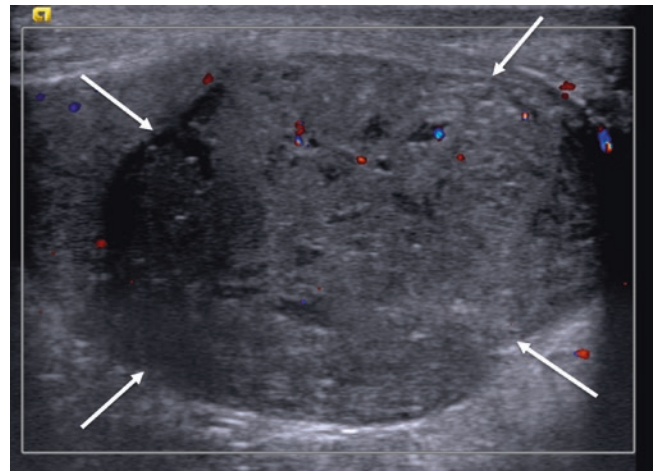


**Fig. 24.3** A 24-year-old with back pain. (a) CT of the abdomen and pelvis shows left para-aortic and pre-aortic lymphadenopathy (arrow), suspicious for metastatic left-sided testicular cancer. (b) Gray-scale US of the scrotum shows a left-sided intratesticular, well-circumscribed, lobulated, heterogeneously hypoechoic mass (arrows) with (c) internal flow on Doppler US. These features are the hallmarks of a malignant testicular neoplasm; the final diagnosis of mature teratoma was established after orchiectomy

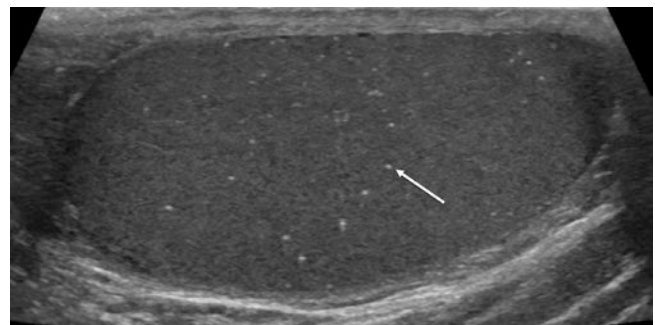
layers of keratinous debris give it a more solid appearance of a round hypoechoic lesion with multiple concentric hyperintense internal layers resembling an “onion skin” and lacking internal blood flow (Fig. 24.8). Although these findings are specific for the entity, some epidermoid cysts can also mimic testicular cancers on imaging (Fig. 24.4).

#### 24.2.1.5 Focal Infections, Hematomas, and Infarcts

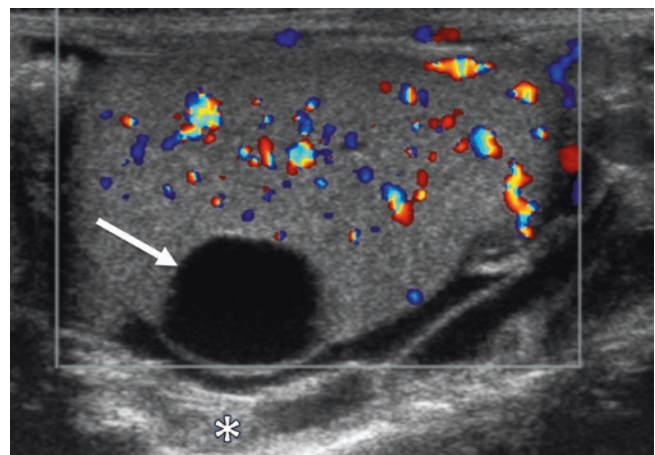
In the adequate clinical context, these entities might be considered in the differential diagnoses: local or systemic signs of infection (Fig. 24.9) and recent history of inguinal or scro-



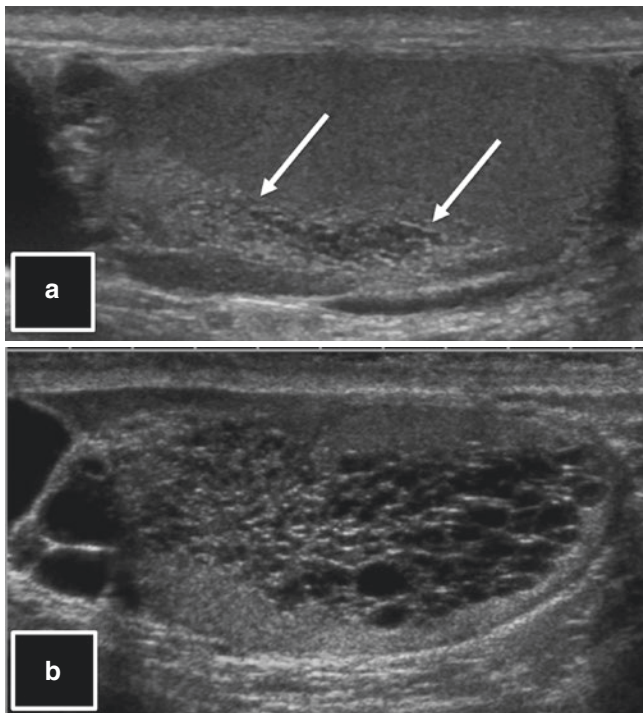
**Fig. 24.4** A 54-year-old with a painless palpable right scrotal mass. (a) US of the scrotum shows an intratesticular, well-circumscribed, lobulated, heterogeneously hypoechoic mass (arrows) with low-level internal vascularity on Doppler US. These features are the hallmarks of a malignant testicular neoplasm, justifying orchiectomy; the final histopathologic diagnosis was epidermoid cyst



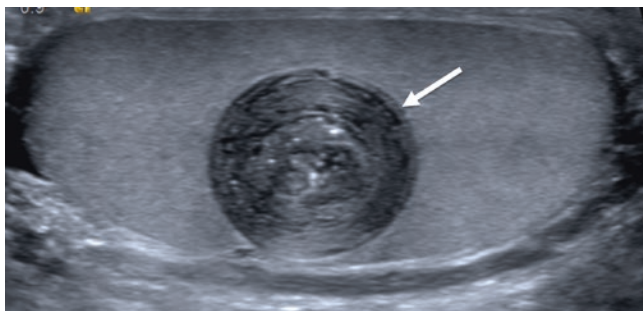
**Fig. 24.5** Imaging features of microlithiasis. Multiple (i.e.,  $\geq 5$  per testis) microcalcifications (i.e.,  $< 3$  mm) within the testicular parenchyma; one microcalcification is marked with an arrow



**Fig. 24.6** Imaging features of a simple testicular cyst. A round, well-defined, homogeneously hypoechoic lesion (arrow) with posterior acoustic enhancement (asterisk) and lack of internal flow

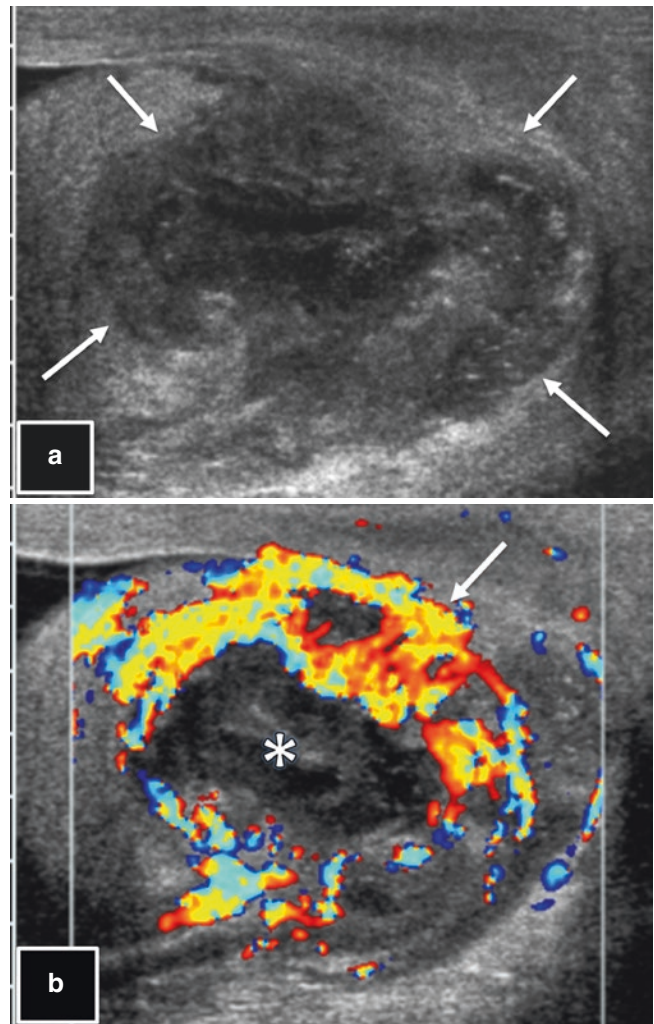


**Fig. 24.7** Two cases of ectasia of the rete testis. (a) 67-year-old patient with prostate cancer and an incidentally discovered testicular lesion. US of the scrotum shows a cluster of multiple small cysts and tubules along the testicular mediastinum (arrows), consistent with rete testis ectasia. (b) In this example of a 70-year-old patient with prostate cancer and a remote history of scrotal surgery, rete ectasia is more extensive, occupying large parts of the testis



**Fig. 24.8** A 23-year-old with a painless palpable scrotal mass. US of the scrotum shows a round, well-delineated lesion with multiple concentric hyperintense internal layers, resembling an “onion skin,” consistent with epidermoid cyst, justifying a nonsurgical, observational approach. The appearance of the mass did not change over the course of 3 years

tal surgery/trauma, torsion, or abnormal states of coagulation for hematoma and infarction (Fig. 24.10). All these entities share the lack of internal vascular flow on Doppler US. As previously mentioned, all cases must be monitored to document involution and exclude malignancy.



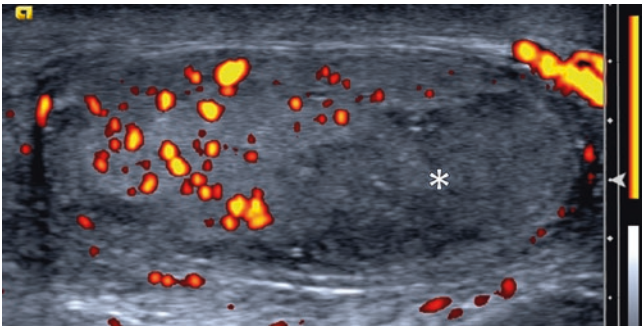
**Fig. 24.9** An 88-year-old with anastomotic leakage after rectal surgery, pelvic abscesses, sepsis, and painful scrotal swelling. (a) US of the scrotum shows a well-circumscribed, lobulated, heterogeneously hypoechoic mass (arrows) with (b) intense peripheral (arrow) but no central (asterisk) flow on Doppler US. The patient underwent orchiectomy, which confirmed the infectious etiology

#### 24.2.1.6 Testicular Adrenal Rest

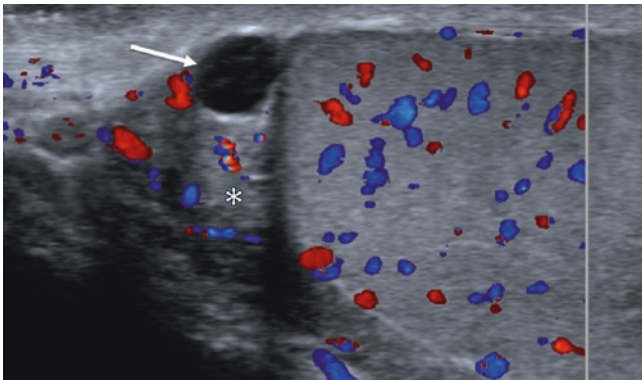
These benign masses occur in patients with congenital adrenal hyperplasia. In addition to clinical history, bilaterality is the key to the diagnosis [4], although unilateral appearance has been reported [5]. Their imaging features are otherwise similar to testicular cancer.

#### 24.2.2 Epididymal Masses

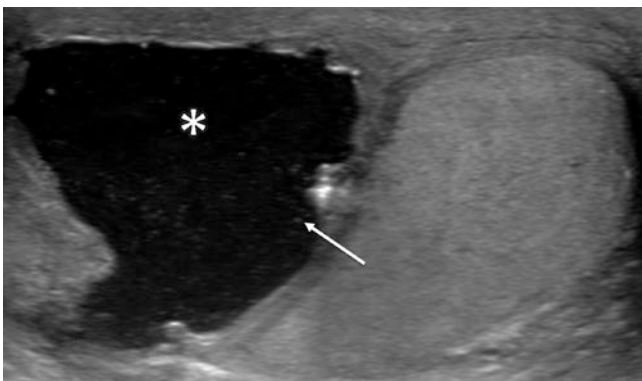
Epididymal masses or mass-like lesions are frequently encountered as incidental findings on scrotal ultrasound. They are almost always benign and do not require specific treatment. Cysts are well-defined, homogeneously



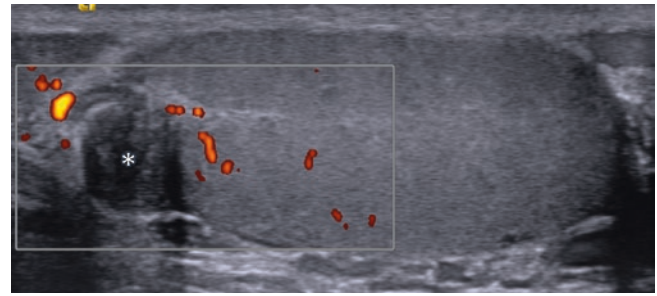
**Fig. 24.10** A 56-year-old with painless right scrotal swelling after recent right nephrectomy with reported gonadal vein tie off/thrombosis. US of the scrotum shows an intratesticular, well-circumscribed, lobulated, heterogeneously hypoechoic mass without internal flow on Power Doppler ultrasound (asterisk). The clinical history and imaging appearance suggest partial/focal testicular infarction, and involution was documented on follow-up US (not shown)



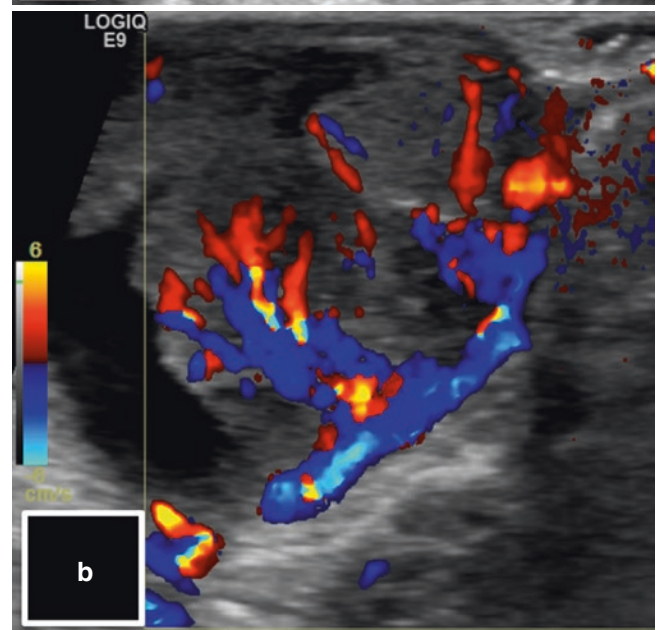
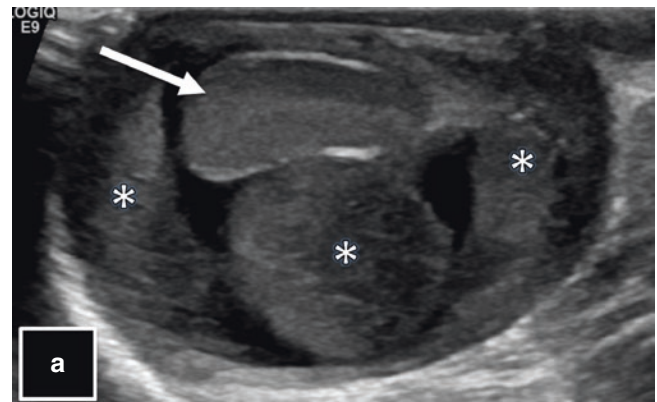
**Fig. 24.11** Imaging features of a simple epididymal cyst. A round, well-defined, homogeneously hypoechoic lesion within the epididymis (arrow) with posterior acoustic enhancement (asterisk) and lack of internal flow.



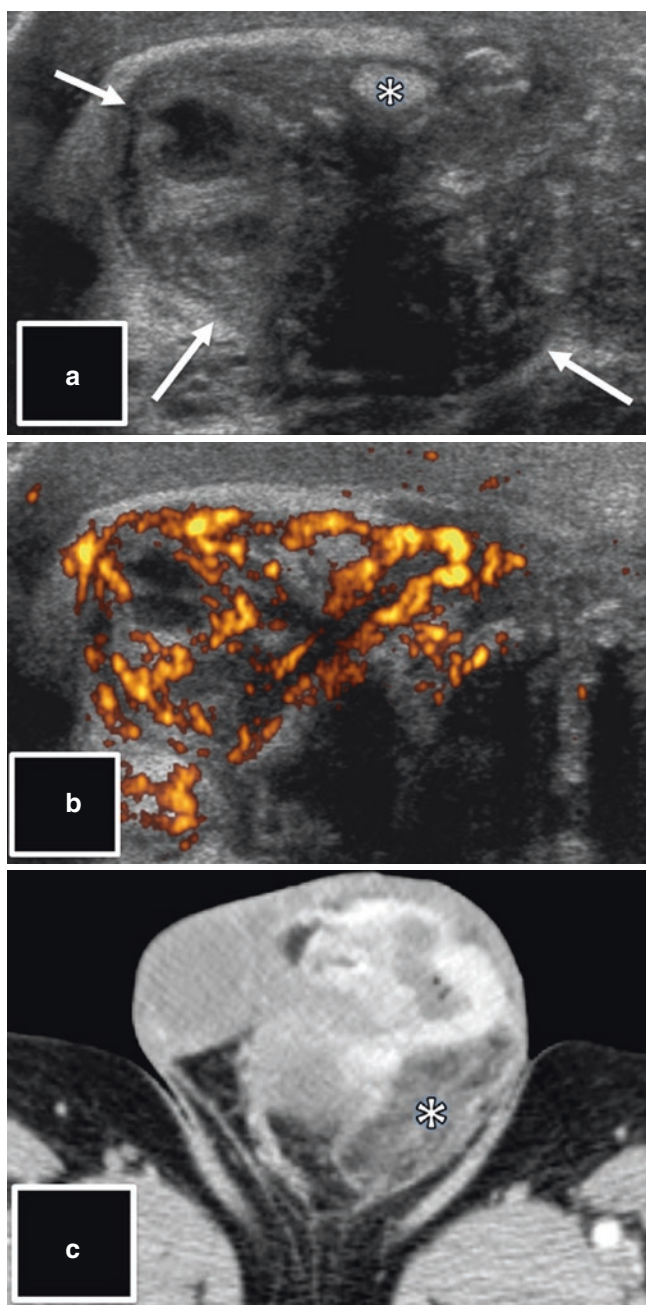
**Fig. 24.12** A 61-year-old with resolved scrotal pain but persistent swelling after antibiotic therapy for epididymitis. US of the scrotum shows a cystic epididymal lesion (asterisk) with multiple small internal low-level echoes (the arrow is pointing at one), consistent with spermatocele



**Fig. 24.13** A 35-year-old with scrotal pain without a palpable mass. US of the scrotum shows a round, well-delineated, heterogeneously hypoechoic mass within the epididymis without detectable flow on Doppler US (asterisk). These imaging findings are non-specific; however, the epididymal location suggests a benign entity; excisional biopsy showed adenomatoid tumor



**Fig. 24.14** A 2-year-old with scrotal swelling and mild scrotal pain. (a) Gray-scale US of the scrotum shows a large extra-testicular, hypoechoic mass (asterisk); the normal testis is marked with an arrow. (b) Doppler US demonstrates intense intralesional blood flow. In this age group, the suspicion for extra-testicular rhabdomyosarcoma, which was confirmed on histopathology, has to be unequivocally conveyed to the referring physician



**Fig. 24.15** A 61-year-old with a long-standing history of hydrocele and a recent increase of scrotal swelling. (a) Gray-scale US shows an extra-testicular, heterogeneously hypointense mass (arrows) with (b) intense internal flow on Doppler US; the normal epididymis is marked within (asterisk) (a). These findings are suspicious for malignancy; (c) the presence of intralesional fat (asterisk) on staging CT suggests liposarcoma, which was confirmed on histopathology

hypoechoic lesions of varying size, most frequently located in the epididymal head (Fig. 24.11). Multiple small low-level echoes within a cystic lesion in a patient with prior vasectomy or other inguinal/scrotal surgery are suggestive of a spermatocele (Fig. 24.12). The most common solid neoplasms of the epididymis are adenomatoid tumors and leiomyomas. Both entities are well defined and show variable size, echogenicity, and vascular flow (Fig. 24.13). The differentiation of these benign neoplasms from sperm (cell) granulomas is rarely possible and not necessary from a clinical perspective.

### 24.2.3 Extra-Testicular Masses

As with epididymal tumors, most scrotal neoplasms outside the testes are benign, most commonly lipomas and fibrous pseudotumors. Scrotoliths are calcified tumor-like masses that can be encountered in any part of the scrotum. The rare exceptions are paratesticular rhabdomyosarcomas in children and adolescents, as well as sarcomas, metastases, and locally advanced scrotal skin cancer in adults.

#### 24.2.3.1 Malignant Paratesticular Tumors

Key to the diagnosis of a rhabdomyosarcoma is patient age in conjunction with a hypoechoic extra-testicular mass that is highly vascular on Doppler US (Fig. 24.14). Paratesticular sarcomas are heterogeneous, markedly hypervascular tumors of adult men; liposarcomas can contain macroscopic fat (Fig. 24.15). The diagnosis of metastases and locally advanced skin cancer can be made in the adequate clinical context.

#### 24.2.3.2 Fat-Containing Paratesticular Lesions

The presence of fat in an extra-testicular mass, most accurately assessed on MRI, can guide the radiologist toward the correct diagnosis. The most common fat-containing paratesticular neoplasm is lipoma of the spermatic cord. Large, markedly hypervascular fat-containing masses in an adult are suspicious for liposarcoma (Fig. 24.15). Fat-containing tumor mimics are inguinal-scrotal hernias and fat necrosis after trauma or surgery.

#### Key Points

- The role of imaging testicular and scrotal masses will vary according to the clinical scenario.
- Imaging is helpful to establish or narrow the differential diagnoses.

### 24.3 Concluding Remarks

Understanding the clinical scenario in which a scrotal imaging exam is performed is pivotal for meaningful radiology reports. Solid testicular masses with internal vascular flow must prompt a high level of suspicion for testicular malignancy, unless unequivocal imaging findings suggest a benign diagnosis. Most epididymal and paratesticular masses are benign; however, irregularly shaped, ill-defined, hypervascular masses may represent malignant tumors.

---

### References

1. Fossa SD, Chen J, Schonfeld SJ, McGlynn KA, McMaster ML, Gail MH, et al. Risk of contralateral testicular cancer: a population-based study of 29,515 U.S. men. *J Natl Cancer Inst.* 2005;97(14):1056–66.
2. Travis LB, Fossa SD, Schonfeld SJ, McMaster ML, Lynch CF, Storm H, et al. Second cancers among 40,576 testicular cancer patients: focus on long-term survivors. *J Natl Cancer Inst.* 2005;97(18):1354–65.
3. Richenberg J, Belfield J, Ramchandani P, Rocher L, Freeman S, Tsili AC, et al. Testicular microlithiasis imaging and follow-up: guidelines of the ESUR scrotal imaging subcommittee. *Eur Radiol.* 2015;25(2):323–30.
4. Wang Z, Yang Z, Wang W, Chen LD, Huang Y, Li W, et al. Diagnosis of testicular adrenal rest tumors on ultrasound: a retrospective study of 15 cases report. *Medicine.* 2015;94(36):e1471.
5. Stikkelbroeck NM, Suliman HM, Otten BJ, Hermus AR, Blickman JG, Jager GJ. Testicular adrenal rest tumours in postpubertal males with congenital adrenal hyperplasia: sonographic and MR features. *Eur Radiol.* 2003;13(7):1597–603.

**Open Access** This chapter is licensed under the terms of the Creative Commons Attribution 4.0 International License (<http://creativecommons.org/licenses/by/4.0/>), which permits use, sharing, adaptation, distribution and reproduction in any medium or format, as long as you give appropriate credit to the original author(s) and the source, provide a link to the Creative Commons license and indicate if changes were made.

The images or other third party material in this book are included in the book's Creative Commons license, unless indicated otherwise in a credit line to the material. If material is not included in the book's Creative Commons license and your intended use is not permitted by statutory regulation or exceeds the permitted use, you will need to obtain permission directly from the copyright holder.

