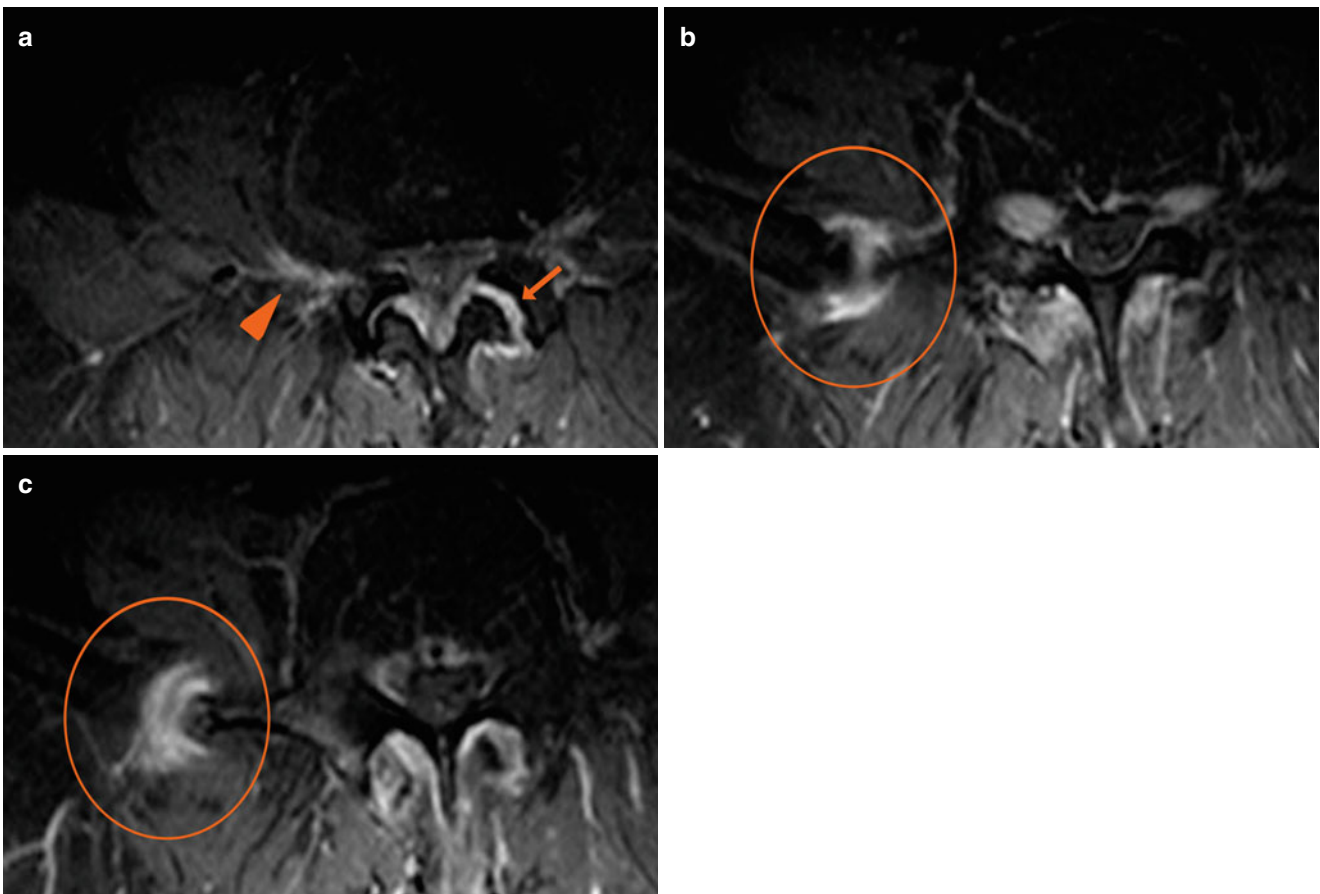


Synovitis

Bone Collision

- A 74-year-old patient
- Chronic low back pain
- Radiculopathy on the right side
- Exacerbation of pain with lateral flexion on the right side



**Fig. 1** (a–c) Axial SE T1-weighted images with fat saturation following administration of contrast medium (a–c). Extraforaminal disc protrusion with surrounding contrast enhancement due to peridiscal inflammation (a, arrowhead). Contrast enhancement of the left facet joint space, indicating

synovitis (a, arrow). Bone collision between the right transverse process of L4 and ipsilateral iliac wing, with contrast enhancement at the same level indicating reactive-inflammatory phenomena (b, c, circle)