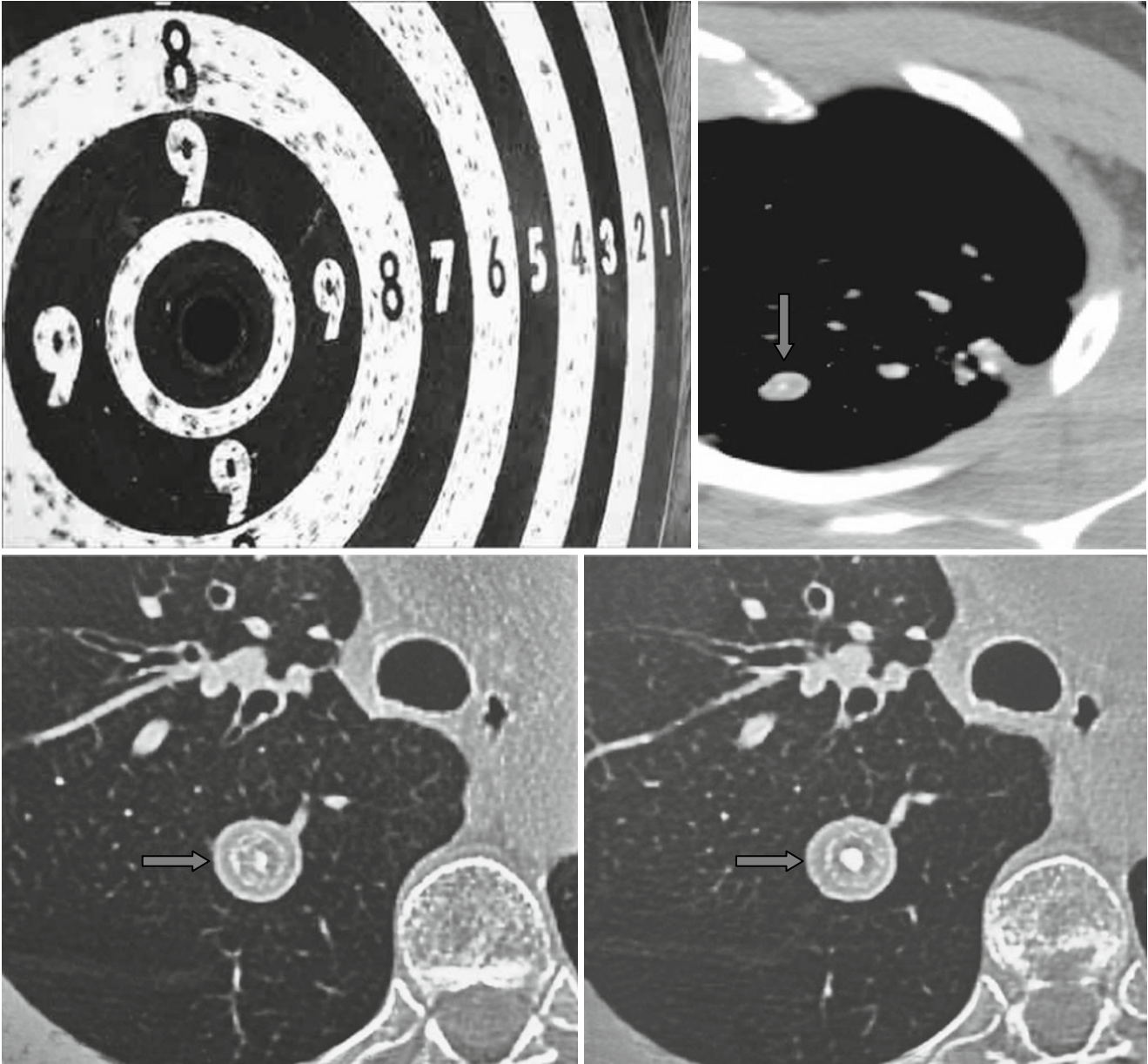


Target Calcification Sign



Concentric (laminar) calcification in a lung nodule known as the “target” sign (↑) occurs in tuberculomas and histoplasmosis.