

Traumatic Lumbar Collapse Vertebroplasty

99

Extracanalicular Cement Leakage

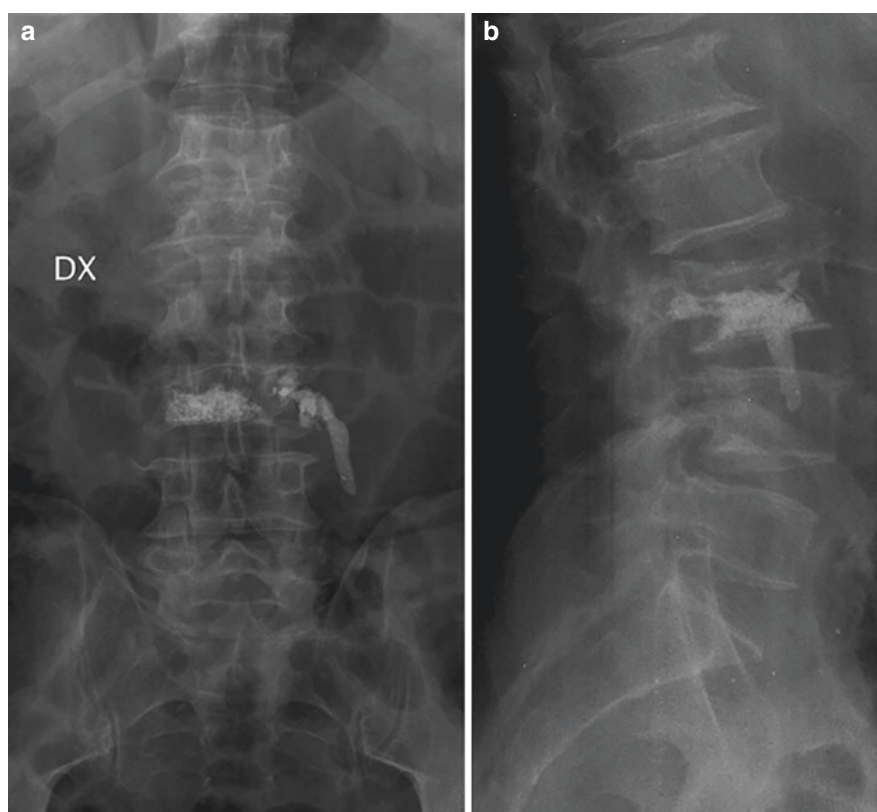
Tommaso Scarabino, Michele Maiorano, Claudia Rutigliano,
Vincenzo Brandini, and Michele Santoro

- Patient with L3 post-traumatic vertebral collapse treated by vertebroplasty
- Early XR follow-up

99.1 Post-vertebroplasty Follow-Up

See Fig. 99.1.

Fig. 99.1 (a, b) XR antero–posterior (a) and lateral (b). Cement in left paravertebral space, no symptoms



T. Scarabino (✉) · M. Maiorano
Department of Radiology—Neuroradiology, “Lorenzo Bonomo”
Hospital, Andria, Italy

C. Rutigliano
Department of Radiology/Neuroradiology, “L. Bonomo” Hospital,
Andria, BT, Italy

V. Brandini · M. Santoro
Department of Neurosurgery, “Lorenzo Bonomo” Hospital,
Andria, Italy