



Sub-acute Onset of Guillain-Barré Syndrome Post-mRNA-1273 Vaccination: a Case Report

Shivaraj Nagalli¹ · Nidhi Shankar Kikkeri²

Accepted: 6 January 2022 / Published online: 18 January 2022
© The Author(s), under exclusive licence to Springer Nature Switzerland AG 2022

Abstract

Ever since the start of the pandemic, SARS-CoV-2 has taken the lives of millions of people around the globe. Several COVID-19 vaccines have been developed with rapidity to prevent acquiring COVID-19 infection, hospitalizations, and deaths. The routine side effects of these vaccines are commonly known and non-severe. Few serious side effects such as thrombosis with thrombocytopenia syndrome (TTS) and Guillain-Barré syndrome (GBS) are increasingly reported particularly after inoculation with ChAdOx1 nCoV-19 (Oxford/AstraZeneca) and Ad26.COV 2.S (Johnson & Johnson's Janssen). Rare cases of GBS after BNT162b2 (Pfizer-BioNTech), an mRNA vaccine, are also reported. However, the true association of these cases to COVID-19 continues to be unclear and the safety of these vaccines continues to be great in preventing deaths from COVID-19 infection. We report a case of middle-aged female who had a gradual onset of lower extremity weakness with a nadir of symptoms reached 10 and 12 weeks after the onset. This protracted course (sub-acute) is atypical for a "classical" GBS. The presence of an antecedent event, autonomic symptoms such as hypotension, and the need for ventilator support favored the diagnosis of GBS than chronic inflammatory demyelinating polyneuropathy (CIDP). This is the first known case to be reported of sub-acute onset of Guillain-Barré syndrome after receiving the mRNA-1273 vaccine.

Keywords COVID-19 · Guillain-Barré syndrome · Sub-acute · mRNA vaccine · Case report

Introduction

Coronavirus disease 2019 (COVID-19) is an acute viral illness caused by severe acute respiratory syndrome coronavirus-2 (SARS-CoV-2). Ever since its first detection in Wuhan, China, during late 2019, SARS-CoV-2 has infected over 220 million people causing more than 4.5 million deaths worldwide and the numbers are increasing [<https://www.worldometers.info/coronavirus/>]. Tremendous efforts are put into the development of these vaccines which have been developed at record speed. However, the side effect profile is still yet to be fully established for these vaccines. Some of the rare side effects which are increasingly reported

are thrombosis with thrombocytopenia syndrome (TTS) and Guillain-Barré syndrome (GBS).

Guillain-Barré syndrome (GBS) is a heterogeneous group of disorders characterized by an acute immune-mediated inflammatory polyneuropathy involving peripheral nerves and neurons. It is typically preceded by an infection involving respiratory and gastrointestinal systems. A smaller proportion of cases are also associated with surgery, trauma, and vaccinations [1–3]. Recently, cases of GBS have been reported after vaccination against coronavirus disease 2019 (COVID-19) [4–10]. We are reporting the first known case of Guillain-Barré syndrome with sub-acute onset that occurred after receiving the first dose of an mRNA-1273 vaccine.

This article is part of the Topical Collection on *Covid-19*

✉ Shivaraj Nagalli
shivanagalli21@gmail.com

¹ Brookwood Baptist Health, 1000 1st St N., Alabaster, AL 35007, USA

² University of Alabama, Birmingham, AL, USA

Case Presentation

A 49-year-old female with a past medical history of hypertension, hyperlipidemia, hypothyroidism, and bipolar disorder presented to the hospital with complaints of worsening weakness involving her lower extremities for 8 weeks.

The weakness began 10 days after receiving the first dose of mRNA-1273 (Moderna vaccine). Her weakness started in her bilateral feet, gradually ascended up to involve the waist and upper extremities. This was associated with ataxia and falls. Numbness in lower extremities and voice changes were also reported. The patient denied a history of diarrhea, rhinorrhea, cough, or congestion prior to the onset of the above symptoms.

Physical examination was remarkable for decreased power of 2/5 in bilateral lower extremities involving proximal and distal muscles and 4/5 in bilateral upper extremities throughout. Muscle tone and bulk were normal. Sensations were diminished to light touch throughout in lower and upper extremities. Severe dysmetria was noted during the finger-nose-finger test. Deep tendon reflexes were absent in the lower and upper extremities. No involuntary movements were noted during the physical exam.

A spinal tap revealed albuminocytological dissociation as shown in Table 1. Routine screening of SARS-CoV-2 was negative. The patient was then admitted to the neurology service with the impression of Guillain-Barré syndrome. A few hours into admission, the patient's respiratory status declined with a drop in forced vital capacity (FVC) requiring emergency endotracheal intubation.

Plasma exchange was initiated subsequently. Magnetic resonance imaging (MRI) brain showed no evidence of acute intracranial hemorrhage, ischemia/infarct, or brain edema. Postcontrast images demonstrated no abnormal parenchymal or meningeal enhancement (Image 1). MRI of cervical, thoracic, and lumbar spine showed no evidence of myelopathy (Image 2).

Serology was negative for GQ1B antibodies. Nerve conduction velocity studies (NCVS) revealed absent sural response and decreased peroneal motor response and the median and ulnar motor responses were of low amplitude. Electromyography demonstrated borderline reduced recruitment with borderline high amplitude, long duration motor unit potentials in the triceps, deltoid, vastus medialis, and tensor fascia lata muscles. Plasma exchange was continued for a total of five sessions. Her symptoms gradually improved and the patient was subsequently extubated. The

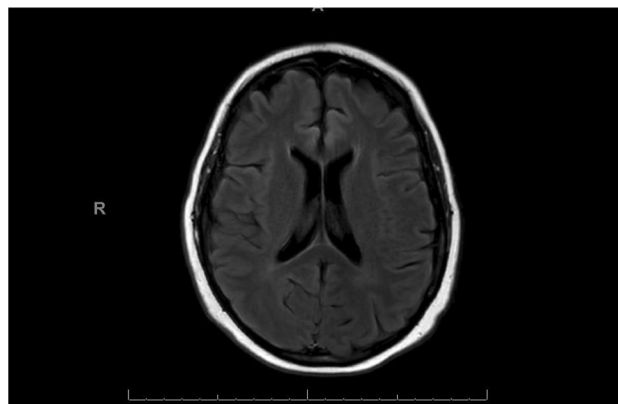


Image 1 Axial section of MRI Brain FLAIR showing normal cerebral structures

hospital course was further complicated by autonomic symptoms such as hypotension that was managed with midodrine. She was subsequently discharged to a facility for continued rehabilitation.

Discussion

Several vaccines have been developed at a record speed to curb its spread further and are effective in reducing the risks of hospitalizations and deaths. However, vaccine hesitancy is not uncommon despite its good efficacy.

Vaccines that are currently in use in the USA are BNT162b2 (Pfizer-BioNTech), mRNA-1273 (Moderna), and Ad26.COV 2.S (Johnson & Johnson's Janssen). Vaccines such as ChAdOx1 nCoV-19 (Oxford/AstraZeneca), Gam-COVID-Vac (Sputnik V), and others are in use elsewhere in the world. [<https://www.who.int/emergencies/diseases/novel-coronavirus-2019/covid-19-vaccines>] These vaccines in general are well-tolerated. Symptoms suggestive of reactogenicity such as pain, redness, swelling at the site of inoculation, myalgia, fevers, chills, and headaches are some of the common side effects that are seen after vaccination [<https://www.cdc.gov/coronavirus/2019-ncov/vaccines/expect/after.html>]. Recently, myocarditis and pericarditis are also reported in some patients who received mRNA vaccines [7]. Neurological adverse events such as cerebral sinus venous thrombosis, intracranial hemorrhage that are associated with thrombocytopenia (termed as thrombocytopenia with thrombosis syndrome or vaccine-induced thrombocytopenia with thrombosis), and Guillain-Barré syndrome are also increasingly reported after receiving COVID-19 vaccines, particularly ChAdOx1 nCoV-19 (Oxford/AstraZeneca) [11] and Ad26.COV 2.S [12]. Few cases of GBS after receiving BNT162b2 are reported [5, 8, 9].

Table 1 Results of cerebrospinal fluid (CSF) analysis showing albuminocytological dissociation

CSF parameters	Patient values	Normal values
CSF glucose	65 mg/dL	50–70 mg/dL
CSF protein	59 mg/dL	20–40 mg/dL
CSF WBC count	<1 cells/cumm	0–5 cells/cumm
CSF RBC count	0 cells/cumm	<1 cells/cumm
CSF xanthochromia	Absent	Absent
CSF lactic acid	1.6 mmol/L	1.2–2.1mmol/L

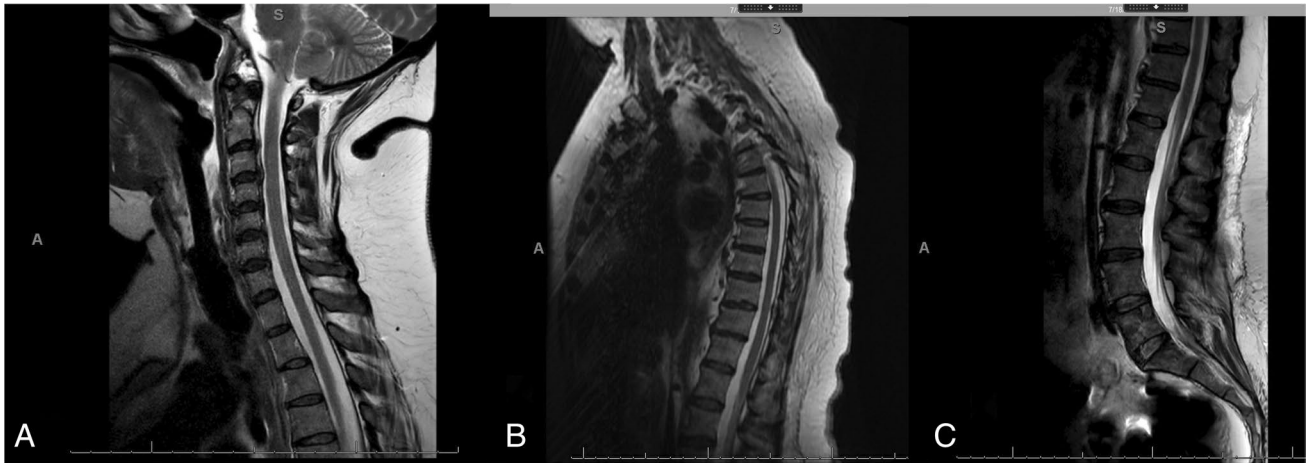


Image 2 Sagittal T2 of cervical (a), thoracic (b), and lumbar (c) spines showing normal appearance of spinal cord, conus medullaris, and cauda equina

Guillain-Barré syndrome is an acute immune-mediated heterogenous neurological disease affecting peripheral nerves and nerve roots, which is typically preceded by bacterial or viral infections. Infection with *Campylobacter jejuni* is the most commonly identified preceding infection. Other causes such as infections with cytomegalovirus, *Mycoplasma pneumoniae*, Epstein-Barr virus, and Zika virus have also been identified [4]. Cases of GBS are also reported after surgery, trauma, and vaccinations. In the past, cases of GBS post-vaccination were initially reported in 1976 during a mass vaccination campaign after an influenza outbreak. Although later studies found that the incidence of GBS was slightly higher after influenza vaccination, epidemiological studies have not found a direct association between vaccines and GBS [1]. Recently, some cases of GBS are being reported after the COVID-19 vaccination. Most of these were reported post-ChAdOx1 nCoV-19 and a total of 11 cases of GBS are reported after BNT162b2 vaccination (that includes an observational study) and none after the mRNA-1273 vaccine to date [5].

GBS is typically characterized by progressive, ascending, symmetrical paresthesias, and muscle weakness that are associated with diminished or absent deep tendon reflexes. Autonomic dysfunction, involvement of cranial nerves, and respiratory failure requiring mechanical ventilation can also occur. The estimated incidence rate of GBS in the USA and Europe is approximately between 0.81 and 1.89 cases per 100,000 person-years. Incidence increases with age, and the condition is also slightly more common in men. The lifetime risk of developing GBS is reported to be about 1 in 1000 [1].

The pathogenesis is thought to be due to an immune response where the antibodies cross-react with the myelin or axons (molecular mimicry) of the peripheral nerves or nerve roots [4]. Complement activation and generation of

anti-ganglioside antibodies have also been implicated in the pathogenesis. It is postulated that the contaminating proteins or other vaccine components may elicit anti-ganglioside antibody production [1]. In the observational study by García-Grimshaw et al. [5], concurrent infections were noted which may have been the triggering source for the immune-mediated polyradiculopathy. Albuminocytologic dissociation on CSF analysis is pathognomonic in the appropriate clinical setting. The anti-GQ1b antibodies are present in the Miller-Fisher variant (ophthalmoplegia, ataxia, and areflexia) of GBS. Decreased velocity and increased latency are typically seen in nerve conduction studies.

Our patient had developed symptoms acutely 10 days after being inoculated with the first dose of the COVID-19 vaccine. But, the nadir of symptoms reached sometime between 10 and 12 weeks. This protracted course of development of symptoms (“sub-acute”) is atypical for a classical case of GBS. The presence of albuminocytologic dissociation confirms the diagnosis of immune-mediated polyneuropathy. NCVS and EMG were supportive of our diagnosis. The diagnosis of chronic inflammatory demyelinating polyneuropathy (CIDP) is also a possibility given the prolonged course of symptoms. However, the features such as the precise onset of symptoms, presence of an antecedent event, the autonomic symptom hypotension, and the need for ventilator support favor the diagnosis of GBS and go against CIDP.

Although there are several cases of GBS that are reported in the Vaccine Adverse Events Reporting System (VAERS), this is the first known case of “sub-acute” onset of GBS to be reported that has developed post-mRNA-1273 vaccination. The true relationship between the occurrences of these cases with COVID-19 vaccines is unknown at this time. Is it a mere coincidence or is it truly associated with COVID-19 vaccines? This needs to be further investigated. A recent

large population-level study assessing the safety of BNT162b2 (another mRNA vaccine) found no association with Bell's palsy, herpes zoster, or GBS. [13] Furthermore, it is important to realize there are several reported cases of neurological complications such as transverse myelitis and GBS after COVID-19 infection. [14–16] After reviewing the occurrences of GBS, the Advisory Committee on Immunization Practices of the United States in July 2021 determined that the benefits of COVID-19 vaccination in preventing COVID-19 morbidity and mortality outweigh the risks for these rare serious adverse events [<https://www.who.int/emergencies/diseases/novel-coronavirus-2019/covid-19-vaccines>].

Conclusion

Vaccination is an effective strategy in reducing the risk of acquiring COVID-19 infection, its severity, hospitalizations, and deaths. Neurological adverse events such as Guillain-Barré syndrome post-vaccination are being reported. However, the causal relationship between GBS and any of these COVID-19 vaccines is not established. Increased vigilance, surveillance, and reporting of such cases post-vaccination are needed to estimate their true prevalence, and further studies are needed to establish their relationship. It is important to reiterate that the safety profile of these vaccines continues to be great and the benefits of them preventing COVID-19 infection far outweigh the risks of GBS based on the available evidence to date.

Supplementary Information The online version contains supplementary material available at <https://doi.org/10.1007/s42399-022-01124-1>.

Author Contribution Shivaraj Nagalli wrote the manuscript, did the research, and collected the references. Nidhi Shankar Kikkeri collected the detailed information and assisted in drafting the manuscript.

Code Availability Not applicable.

Declarations

Ethics Approval Waived/not applicable.

Consent to Participate Consent taken from the patient to publish this case.

Consent for Publication Consent taken from the patient to publish this case.

Conflict of Interest The authors declare no competing interests.

References

- McKean N, Chircop C. Guillain-Barré syndrome after COVID-19 vaccination. *BMJ Case Rep.* 2021;14(7):e244125. <https://doi.org/10.1136/bcr-2021-244125>.
- Rudant J, Dupont A, Mikaeloff Y, Bolgert F, Coste J, Weill A. Surgery and risk of Guillain-Barré syndrome: a French nationwide epidemiologic study. *Neurology.* 2018;91(13):e1220–7. <https://doi.org/10.1212/WNL.0000000000006246>.
- Tan IL, Ng T, Vucic S. Severe Guillain-Barré syndrome following head trauma. *J Clin Neurosci.* 2010;17(11):1452–4. <https://doi.org/10.1016/j.jocn.2009.11.037>.
- Hasan T, Khan M, Khan F, Hamza G. Case of Guillain-Barré syndrome following COVID-19 vaccine. *BMJ Case Rep.* 2021;14(6):e243629. <https://doi.org/10.1136/bcr-2021-243629>.
- García-Grimshaw M, Michel-Chávez A, Vera-Zertuche JM, Galnares-Olalde JA, Hernández-Vanegas LE, Figueroa-Cucurachi M, Paredes-Ceballos O, Reyes-Terán G, Carbajal-Sandoval G, Ceballos-Liceaga SE, Arauz A, Valdés-Ferrer SI. Guillain-Barré syndrome is infrequent among recipients of the BNT162b2 mRNA COVID-19 vaccine. *Clin Immunol.* 2021:108818. <https://doi.org/10.1016/j.clim.2021.108818>
- Razok A, Shams A, Almeer A, Zahid M. Post-COVID-19 vaccine Guillain-Barré syndrome; first reported case from Qatar. *Ann Med Surg (Lond).* 2021;67:102540. <https://doi.org/10.1016/j.amsu.2021.102540>.
- Pepe S, Gregory AT, Denniss AR. Myocarditis, pericarditis and cardiomyopathy after COVID-19 vaccination [published online ahead of print, 2021 Jul 30]. *Heart Lung Circ.* 2021;S1443-9506(21)01156-2 <https://doi.org/10.1016/j.hlc.2021.07.011>
- Waheed S, Bayas A, Hindi F, Rizvi Z, Espinosa PS. Neurological complications of COVID-19: Guillain-Barre syndrome following Pfizer COVID-19 vaccine. *Cureus.* 2021;13(2):e13426. <https://doi.org/10.7759/cureus.13426>.
- Scendon R, Petrelli C, Scaloni G, Logullo FO. Electromyoneurography and laboratory findings in a case of Guillain-Barré syndrome after second dose of Pfizer COVID-19 vaccine. *Hum Vaccin Immunother.* 2021:1–4. <https://doi.org/10.1080/21645515.2021.1954826>
- Patel SU, Khurram R, Lakhani A, Quirk B. Guillain-Barre syndrome following the first dose of the chimpanzee adenovirus-vectored COVID-19 vaccine, ChAdOx1. *BMJ Case Rep.* 2021;14(4):e242956. <https://doi.org/10.1136/bcr-2021-242956>.
- Sharifian-Dorche M, Bahmanyar M, Sharifian-Dorche A, Mohammadi P, Nomovi M, Mowla A. Vaccine-induced immune thrombotic thrombocytopenia and cerebral venous sinus thrombosis post COVID-19 vaccination; a systematic review. *J Neurol Sci.* 2021;428:117607. <https://doi.org/10.1016/j.jns.2021.117607>.
- Rosenblum HG, Hadler SC, Moulia D, Shimabukuro TT, Su JR, Tepper NK, Ess KC, Woo EJ, Mba-Jonas A, Alimchandani M, Nair N, Klein NP, Hanson KE, Markowitz LE, Wharton M, McNally VV, Romero JR, Talbot HK, Lee GM, Daley MF, Mbaeyi SA, Oliver SE. Use of COVID-19 vaccines after reports of adverse events among adult recipients of Janssen (Johnson & Johnson) and mRNA COVID-19 vaccines (Pfizer-BioNTech and Moderna): update from the Advisory Committee on Immunization Practices - United States, July 2021. *MMWR Morb Mortal Wkly Rep.* 2021;70(32):1094–9. <https://doi.org/10.15585/mmwr.mm7032e4>.
- Shasha D, Bareket R, Sikron FH, Gertel O, Tsamir J, Dvir D, Mossinson D, Heymann AD, Zacay G. Real-world safety data for the Pfizer BNT162b2 SARS-CoV-2 vaccine: historical cohort study. *Clin Microbiol Infect.* 2022;28(1):130–4. <https://doi.org/10.1016/j.cmi.2021.09.018>.
- Alberti P, Beretta S, Piatti M, Karantzoulis A, Piatti ML, Santoro P, Viganò M, Giovannelli G, Pirro F, Montisano DA, Appollonio I, Ferrarese C. Guillain-Barré syndrome related to COVID-19 infection. *Neurol Neuroimmunol Neuroinflamm.* 2020;7(4):e741. <https://doi.org/10.1212/NXI.0000000000000741>.
- Caress JB, Castoro RJ, Simmons Z, Scelsa SN, Lewis RA, Ahlawat A, Narayanaswami P. COVID-19-associated Guillain-Barré

- syndrome: the early pandemic experience. *Muscle Nerve*. 2020;62(4):485–91. <https://doi.org/10.1002/mus.27024>.
- 16 Munz M, Wessendorf S, Koretsis G, Tewald F, Baegi R, Krämer S, Geissler M, Reinhard M. Acute transverse myelitis after COVID-19 pneumonia. *J Neurol*. 2020;267(8):2196–7. <https://doi.org/10.1007/s00415-020-09934-w>.

Publisher's Note Springer Nature remains neutral with regard to jurisdictional claims in published maps and institutional affiliations.