



A Case of Restrictive Lung Disease Masquerading as SARS-CoV-2 Pneumonia: the Complexity of Integrating Lung Ultrasound in Clinical Management

Yale Tung-Chen¹ · Tomás Villén-Villegas² · Andrea Gutiérrez-Villanueva¹ · Marta Nogue-Infante³

Accepted: 6 January 2022 / Published online: 24 January 2022
© The Author(s), under exclusive licence to Springer Nature Switzerland AG 2022

Abstract

This report aims to highlight the importance of integrating the lung ultrasound findings in the clinical judgment, and to integrate its findings, exemplified in this patient, thought to have COVID-19 bilateral pneumonia, and turn out to have an infectious spondylodiscitis and secondary, a restrictive lung disease. As ultrasound devices become increasingly portable and affordable, the future potential of lung ultrasound relies on a not lesser degree of clinical skills acquisition.

Keywords Coronavirus disease 2019 (COVID-19) · Severe acute respiratory syndrome coronavirus 2 (SARS-CoV-2) · Lung ultrasound (LUS)

Introduction

Lung ultrasound has gained popularity over the last few years, mainly because it is an established technique available at the bedside of the patient for evaluating thoracic pathologies, especially sensitive to abnormalities in the pleura and subpleural spaces. However, before expanding its use, we must be aware of the many limitations of the technique.

Case Report

We report the case of a 60-year-old man who was hospitalized in the Internal Medicine ward due to lower respiratory tract infection, after presenting to the emergency department (ED) with a 2-week history of dyspnea on exertion and an intense bilateral dorsal pain irradiated to the anterior chest, exacerbated with deep breathing and movement.

He had a history of advanced liver cirrhosis complicated with portal hypertension and coagulopathy, with the need of repeated blood transfusions, therefore a peripherally inserted central catheter (PICC) was placed 5 months earlier.

In the ED he was afebrile (36.2 °C), hemodynamically stable (PA 110/58 mmHg, HR 62 bpm), O₂ saturation in room air was 96%. Physical examination revealed tenderness, especially in the left subscapular area. Heart auscultation was normal and subtle dry bibasal crackles were present during lung auscultation.

A chest X-ray was ordered but showed no significant consolidations. With the presumptive diagnosis of radio-occult pneumonia, lung ultrasound (LUS) was performed with a hand-held device (ButterflyIQ—Butterfly Network, Guilford, CT, USA) and showed areas of pulmonary subpleural consolidations (Fig. 1A, white arrow) in the right posterior lung and a focal B line pattern (Fig. 1B, white arrow), especially in the left lung base.

Laboratory tests showed a WBC of $11.1 \times 10^3/\mu\text{L}$ (normal value—NV: 4.0–11.5), lymphocytes $0.8 \times 10^3/$

Topical Collection on *COVID-19*.

✉ Yale Tung-Chen
yale.tung@salud.madrid.org

Tomás Villén-Villegas
tomasvillen@gmail.com

Andrea Gutiérrez-Villanueva
a.gutierrezv@hotmail.com

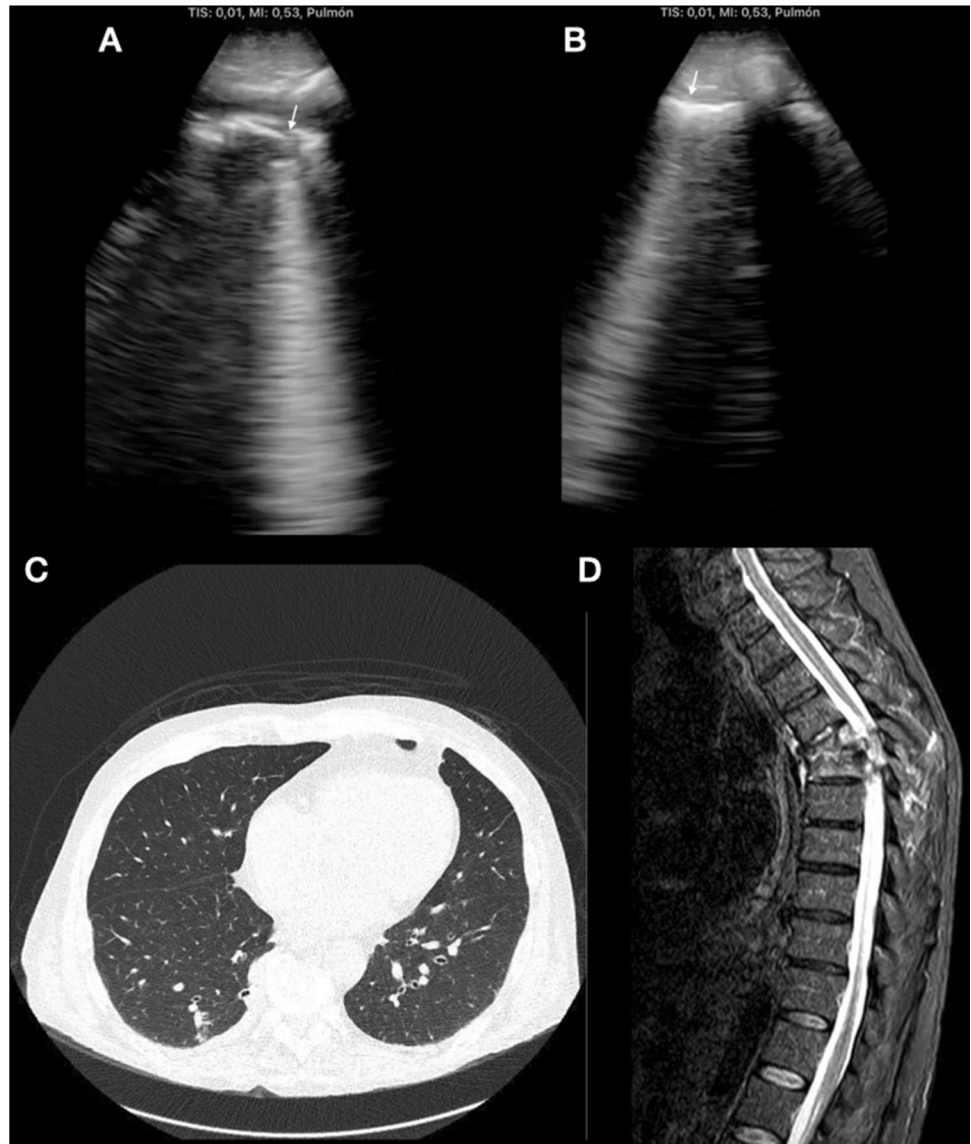
Marta Nogue-Infante
martanogue13@gmail.com

¹ Department of Internal Medicine, Hospital Universitario Puerta de Hierro Majadahonda, Majadahonda, Spain

² Department of Medicine, Universidad Francisco de Vitoria, Madrid, Spain

³ Department of Medicine, University of Lleida, Lleida, Spain

Fig. 1 Lung ultrasound, right posterior lung showing a subpleural consolidation (A, white arrow) and left posterior lung showing a B-line artifact (B, white arrow). Chest CT (C) and MRI (D), revealing absence of lung consolidations and a significant spondylodiscitis



μL (NV: 1.2–4.0), reactive C-protein 39 mg/L (NV: 0.1–10.0), and D-dimer 540 ng/ml (NV: 0–500). Blood gas analysis showed hypoxemia 66 mmHg [NV: 75–100 mmHg]. Kidney and liver function markers were within normal parameters. A nasopharyngeal swab reverse transcription-polymerase chain reaction (RT-PCR) of the nucleic acid of SARS-CoV-2 test resulted negative. He was then admitted to the internal medicine ward. Dexamethasone and thromboprophylaxis were started with the suspicion of a false negative RT-PCR.

The next day, the patient continued to present the previously described dorsal pain leading us to perform a chest computed tomography (Fig. 1C), which revealed absence of lung consolidations, a subtle subpleural band in the right lower lobe, and thickening of bronchial walls. However, the most relevant findings were bony erosive changes with narrowing of the intervening T5/T6 disc space and surrounding

soft tissue swelling, confirmed with magnetic resonance imaging (Fig. 1D).

During the present hospitalization, vancomycin was added after being diagnosed with infectious spondylodiscitis subsequent PICC insertion. *Staphylococcus epidermidis* was isolated from blood cultures. He presented a satisfactory evolution and was discharged after surgical treatment.

Discussion

Lung ultrasound has a growing importance, particularly during the current pandemic, as it allows an early detection of suspected cases with negative X-ray or RT-PCR [1].

However, lung ultrasound, in particular B-lines and subpleural consolidations remain a nonspecific sign of increased density of the peripheral lung parenchyma and partial loss

of aeration [2]. The appropriate use of LUS is integrating it with the clinical assessment, due to the overlapping features with different etiologies, and the correct chronology of the disease. This is vital information, that as exemplified with the case reported, eventually mislead to an erroneous interpretation of the findings, omitting the clinical suspicion of a devastating disease.

As ultrasound devices become increasingly portable and affordable, the future potential of lung ultrasound relies on a not lesser degree of clinical skills acquisition.

Acknowledgements - Yale Tung Chen is the guarantor of the content of the present letter.

- The authors certify that have no commercial associations that might pose a conflict of interest in connection with this editorial letter.

Author Contribution All authors have contributed to this work. All authors read and approved the final manuscript. This work has not been supported by public grants or financial support. No sources of funding were used to assist in the preparation of this study. Each author certifies that he has no commercial associations that might pose a conflict of interest in connection with the submitted article. We certify that this research was conducted in conformity with ethical principles of our institution. This work, figures and tables, have not been previously published and reproduced from another source.

Funding This work has not been supported by any public grants or other kind of financial support.

Data Availability Data available upon justifiable request to the correspondent author.

Code Availability Not applicable.

Declarations

Ethics Approval A case report is a medical/educational activity that does not meet the definition of “research”, which is: “a systematic

investigation, including research development, testing and evaluation, designed to develop or contribute to generalizable knowledge.” Therefore, the activity *does not* have to be reviewed by an IRB.

Consent to Participate Informed consent was obtained from the patient.

Consent for Publication Informed consent was obtained from the patient. A case report is a medical/educational activity that does not meet the definition of “research”, which is: “a systematic investigation, including research development, testing and evaluation, designed to develop or contribute to generalizable knowledge.” Therefore, the activity does not have to be reviewed by an IRB.

Competing Interests No sources of funding were used to assist in the preparation of this letter. The author certifies that he has no commercial associations that might pose a conflict of interest in connection with the submitted article.

References

1. Tung-Chen Y, Martí de Gracia M, Díez-Tascón A, Alonso-González R, Agudo-Fernández S, Parra-Gordo ML, Ossaba-Vélez S, Rodríguez-Fuertes P, Llamas-Fuentes R. Correlation between chest computed tomography and lung ultrasonography in patients with coronavirus disease 2019 (COVID-19). *Ultrasound Med Biol.* 2020;46(11):2918–26. <https://doi.org/10.1016/j.ultrasmedbio.2020.07.003>.
2. Tung-Chen Y, Algora-Martín A, Llamas-Fuentes R, Rodríguez-Fuertes P, Martínez Virto AM, Sanz-Rodríguez E, Alonso-Martínez B, Rivera Núñez MA. Point-of-care ultrasonography in the initial characterization of patients with COVID-19. *Med Clin (Engl Ed).* 2021;156(10):477–84. <https://doi.org/10.1016/j.medcle.2020.12.016>.

Publisher's Note Springer Nature remains neutral with regard to jurisdictional claims in published maps and institutional affiliations.