

CASE REPORT

# A 12-Day-Old Boy with Methemoglobinemia After Circumcision with Local Anesthesia (Lidocaine/Prilocaine)

Evelien Kuiper-Prins<sup>1</sup> · Gerthe Femke Kerkhof<sup>1</sup> · Catharina Gertrudis Maria Reijnen<sup>1</sup> · Pieter Jan van Dijken<sup>1</sup>

Published online: 24 September 2016

© The Author(s) 2016. This article is published with open access at Springerlink.com

**Abstract** A 12-day-old boy presented with duskiess 4 h after circumcision with local anesthesia: infiltration with lidocaine (6 mL 1 %) and topical EMLA cream (2.5 % lidocaine/2.5 % prilocaine). He had no respiratory distress, but a strikingly dark skin. A blood sample showed dark, chocolate brown blood with a raised methemoglobin of 49.8 % (normal <1.5 %) and a lactate of 10 mmol/L. A diagnosis of methemoglobinemia was made. The patient was treated with oxygen administration, but methemoglobin concentration was still 45 % 1 h later. After administration of two doses of intravenous methylene blue (total 0.7 mg/kg), the methemoglobin concentration decreased to 3.3 %, and had normalized to 1.3 % 1 day later. This confirmed the diagnosis of an acquired methemoglobinemia after local use of lidocaine and topical lidocaine/prilocaine. Hemoglobin can be oxidized to methemoglobin, which is unable to transport oxygen. The most common cause of acquired methemoglobinemia is ingestion or skin exposure to an oxidizing agent, for example lidocaine and prilocaine. Neonates are more susceptible to developing acquired methemoglobinemia but, according to most guidelines, local anesthesia is considered to be safe in this patient group. This is the first case report of a term neonate with methemoglobinemia of almost 50 % occurring in a Western country and successfully treated with intravenous methylene blue. In conclusion, severe methemoglobinemia may be observed after the use of local lidocaine/prilocaine for a circumcision, especially in neonates. The safety of local anesthesia in this patient group needs to be reconsidered.

## Key Points

Methemoglobinemia can be caused by local anesthesia (lidocaine/prilocaine).

Neonates are more susceptible to developing methemoglobinemia.

Severe methemoglobinemia can be treated with intravenous methylene blue; glucose-6-phosphate dehydrogenase (G6PD) deficiency is a contraindication.

## Introduction

Cyanosis can be caused by methemoglobinemia, a raised concentration of methemoglobin in the circulation. Methemoglobin is, in contrast to hemoglobin, unable to transport oxygen, and the function of the remaining hemoglobin is impaired, leading to functional anemia [1–3].

Methemoglobinemia can be congenital or acquired. Congenital methemoglobinemia is characterized by diminished enzymatic reduction of methemoglobin to functional hemoglobin. Affected patients appear cyanotic but are generally asymptomatic. Acquired methemoglobinemia is more common and typically results from exposure to specific drugs or agents that cause an increase in the production of methemoglobin [1].

## Case Report

A 12-day-old Afghan boy presented at our emergency department because of duskiess. He was born at term, through an uncomplicated vaginal delivery, without

✉ Evelien Kuiper-Prins  
evelienprins89@gmail.com

<sup>1</sup> Department of Pediatrics, St Elisabeth Ziekenhuis, Hilvarenbeekseweg 60, 5022 GC Tilburg, The Netherlands

neonatal complications. Family history was negative for blood diseases and favism. There was no history of neonatal jaundice. Approximately 4 h before presentation he underwent a circumcision in a private clinic with local anesthesia: topical EMLA cream (2.5 % prilocaine/2.5 % lidocaine; the precise amount and size of the application area is unclear) applied 1 h before circumcision and infiltration with 6 mL lidocaine 1 % a few minutes before circumcision.

We saw a 12-day-old neonate with weight 3700 g, length 55 cm and head circumference 36.5 cm. His heart rate was 190/min, respiratory rate 50/min, saturation 85 % with a non-rebreathing mask with 12 L 100 % oxygen, blood pressure 85/60 mmHg, and he had a temperature of 36.8 °C. He had no respiratory distress and was actively suckling on his soother. Of note was his distinct dark skin, and dark brown lips (Fig. 1a). Further physical examination was normal.

Blood collection showed dark, chocolate brown blood. His capillary blood gas showed pH 7.30, pCO<sub>2</sub> 4.14 kPa, BE -9.8 mmol/L, a raised methemoglobin of 49.8 % (normal <1.5 %) and a lactate of 10.0 mmol/L. A diagnosis of methemoglobinemia with significant lactate acidemia reflecting functional anemia at tissue level was made.

After 1 h of oxygen treatment only, due to the mild symptoms, his methemoglobin concentration was still 45 %, and treatment was started with intravenous methylene blue in a two-step fashion due to his unknown glucose-6-phosphate dehydrogenase (G6PD) status, as methylene blue is contraindicated with G6PD deficiency [1]. After administration of two doses of methylene blue (total 0.7 mg/kg), methemoglobin concentration decreased to 3.3 %. His skin color completely normalized during treatment (Fig. 1b). One day later, methemoglobin had normalized to 1.3 %, ruling out congenital methemoglobinemia.

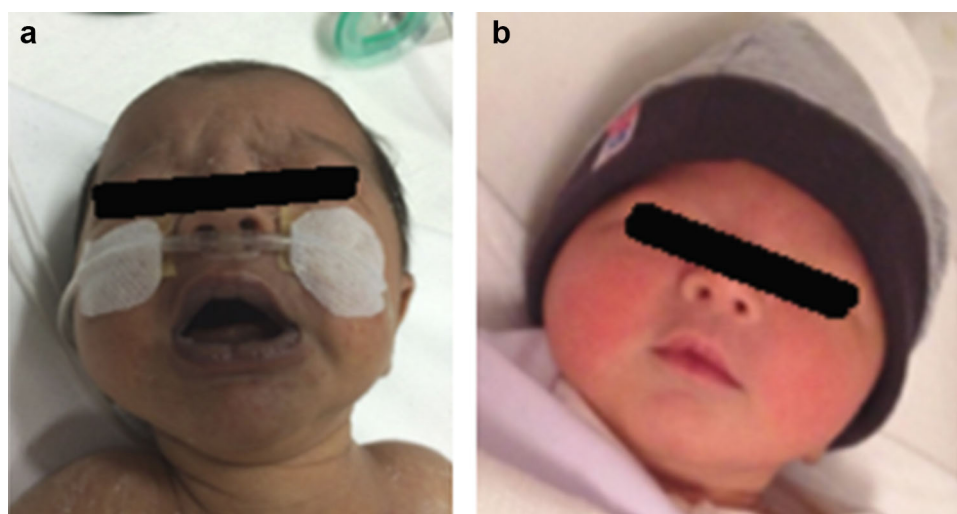## Discussion

This case report presents a 12-day-old boy with methemoglobinemia (49.8 %) after local anesthesia (infiltration with lidocaine and topical use of lidocaine/prilocaine) for circumcision. Methemoglobin concentration normalized with intravenous methylene blue treatment.

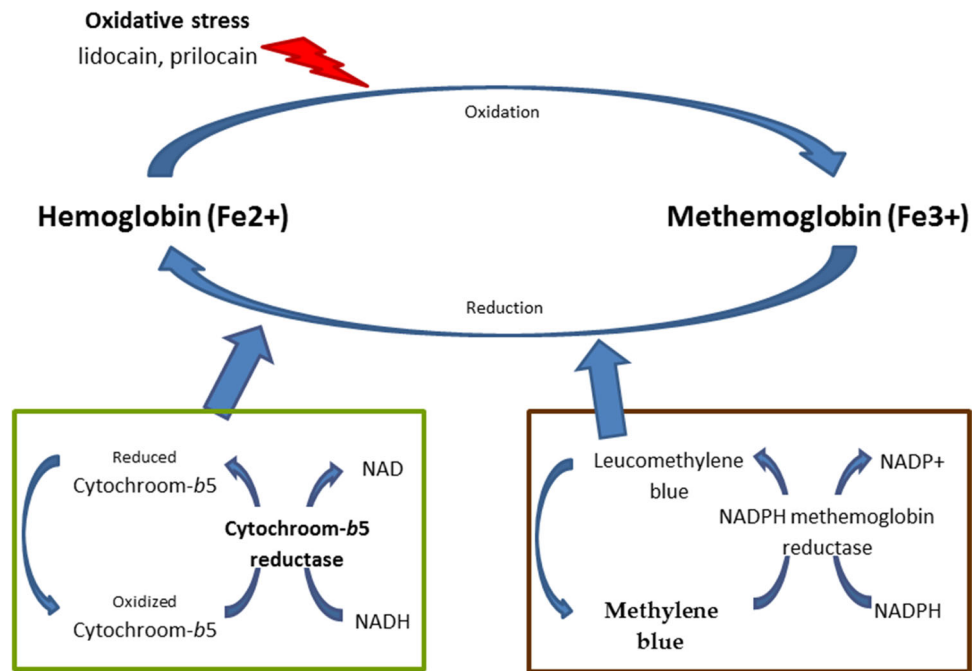
The iron in hemoglobin is normally found in the Fe<sup>2+</sup> state, but this can be oxidized to the Fe<sup>3+</sup> state to form methemoglobin (Fig. 2). Red blood cells are continuously exposed to oxygen free radicals by carrying oxygen in a high concentration, resulting in continuous formation of a physiologic concentration of methemoglobin. Several endogenous reduction systems ensure that, in healthy individuals, methemoglobin concentration is kept at 1.5 % of total hemoglobin. The cytochrome-*b5* reductase system is the predominant system and accounts for approximately 99 % of daily methemoglobin reduction. Another enzyme that reduces methemoglobin is reduced nicotinamide adenine dinucleotide phosphate (NADPH) methemoglobin reductase. In normal conditions, this enzyme plays a negligible role in reducing methemoglobin. It is actually a generalized reductase with an affinity for dyes, such as methylene blue, which are normally not found in the body. NADPH methemoglobin reductase will reduce these dyes, which in turn reduce methemoglobin. In patients with G6PD deficiency, this pathway is not working, leading to high levels of these dyes, which could in turn lead to more oxidative stress and more oxidation of methemoglobin. Therefore, treatment of choice for severe acute methemoglobinemia is intravenous methylene blue, a heterocyclic aromatic chemical compound, but G6PD deficiency is a contraindication [1–3].

Young infants are more susceptible to developing methemoglobinemia because fetal hemoglobin is more easily oxidized than adult-type hemoglobin. Besides,

**Fig. 1** **a** 12-day-old boy with a methemoglobinemia of 49.8 %. Of note is his dark, brown skin color, with dark brown lips. **b** The same boy directly after treatment with intravenous methylene blue



**Fig. 2** Hemoglobin can be oxidized to form methemoglobin by oxidative stress. Methemoglobin can be reduced to hemoglobin by the cytochrome-*b5* and NADPH methemoglobin reductase systems. *NADH* nicotinamide adenine dinucleotide



young infants have lower levels of cytochrome-*b5* reductase in their red blood cells during the first 4 months of life, resulting in a lower capacity to reduce methemoglobin [1].

The most common cause of acquired methemoglobinemia is ingestion or skin exposure to an oxidizing agent, for example lidocaine and prilocaine [2–5]. Drugs that induce methemoglobinemia are not usually the causative agents themselves. Instead, these drugs are metabolized to an oxidative free radical. Because of the variability in metabolism among individuals, not every patient may experience methemoglobinemia when exposed to such agents [1].

In this case, methemoglobinemia was caused by local lidocaine and topical lidocaine/prilocaine, which is not a new phenomenon in children; however, most cases concern preterm infants. Only three case reports of term infants have been published. In 1997, Kumar et al. described a 2-day-old boy with a methemoglobinemia of 16 % after lidocaine/prilocaine application on the prepuce; this methemoglobinemia resolved spontaneously [2]. A similar case was reported in 2000, with a methemoglobinemia of 16 % after application of lidocaine/prilocaine on the prepuce for 3 h. In this case, methemoglobin concentration also decreased without treatment with methylene blue [3].

In 2014, Uygur et al. reported an 18-day-old Indian boy with a methemoglobinemia of 50 % after local anesthesia for circumcision (lidocaine/prilocaine), successfully treated with methylene blue [4]. To date, methemoglobinemia after topical anesthesia in neonates has not been reported in Western countries.

Possible factors that contributed to the development of high levels of methemoglobinemia include an excessive

amount of topical agents, large application area, prolonged application time, diseased and/or inflamed skin, prematurity and concomitant use of other methemoglobin-inducing agents [5].

Clearly, a high methemoglobin concentration can occur after lidocaine/prilocaine application on the prepuce. Nevertheless, the Dutch pharmacologic guideline states that it is safe to use these topical agents for circumcision, even in neonates [6]. The US National Library of Medicine states that topical lidocaine/prilocaine should not be used in neonates with a gestational age <37 weeks, or in infants under the age of 12 months who are receiving treatment with methemoglobin-inducing agents. They also state that infants up to 3 months of age should be monitored for methemoglobin concentration before, during and after the application [7]. However, topical lidocaine/prilocaine application in infants younger than 3 months is not discouraged.

In 2014, Tran and Koo reviewed the literature regarding the risk of systemic toxicity associated with the use of topical lidocaine/prilocaine in the pediatric and adult population. They concluded that all nine trials in children aged younger than 3 months reported clinically insignificant levels of methemoglobin. The highest level observed was 6.2 %, without symptoms [5]. However, in these trials, topical lidocaine/prilocaine was applied to intact skin, not on the prepuce of the infants [5]. In contrast, in all reported cases previously described, topical lidocaine/prilocaine was absorbed through the transmucosal route. Although this review showed no significant methemoglobinemia after lidocaine/prilocaine application, case

reports and our case show that it can lead to life-threatening degrees of methemoglobinemia in young infants.

## Conclusion

Life-threatening degrees of methemoglobinemia may be observed after the use of local anesthetic agents for circumcision in young infants. The safety of local anesthesia in this vulnerable patient group needs to be reconsidered.

**Author contributions** Evelien Kuiper-Prins diagnosed the boy with methemoglobinemia, treated him, and drafted the initial manuscript. Gerthe Femke Kerkhof critically reviewed and revised the manuscript. Catharina Gertrudis Maria Reijnen supervised Evelien Kuiper-Prins in treating the patient, and critically reviewed the manuscript. Pieter Jan van Dijken critically reviewed and revised the manuscript. All authors approved the final manuscript as submitted and agree to be accountable for all aspects of the work.

## Compliance with Ethical Standards

**Funding source** No funding was secured for this case report.

**Financial disclosure** The authors have no financial relationships relevant to this article to disclose.

**Conflict of interest** Evelien Kuiper-Prins, Gerthe Femke Kerkhof, Catharina Gertrudis Maria Reijnen and Pieter Jan van Dijken declare that they have no conflicts of interest.

**Informed consent** Written informed consent was obtained from the patient's parents for publication of this case report and any

accompanying images. A copy of the written consent may be requested for review from the corresponding author.

**Open Access** This article is distributed under the terms of the Creative Commons Attribution-NonCommercial 4.0 International License (<http://creativecommons.org/licenses/by-nc/4.0/>), which permits any noncommercial use, distribution, and reproduction in any medium, provided you give appropriate credit to the original author(s) and the source, provide a link to the Creative Commons license, and indicate if changes were made.

## References

1. Wright RO, Lewander WJ, Woolf AD. Methemoglobinemia: etiology, pharmacology, and clinical management. *Ann Emerg Med.* 1999;34(5):646–56.
2. Kumar AR, Dunn N, Naqvi M. Methemoglobinemia associated with a prilocaine-lidocaine cream. *Clin Pediatr.* 1997;36:239–40.
3. Couper RTL. Methaemoglobinaemia secondary to topical lignocaine/prilocaine in a circumcised neonate. *J Paediatr Child Health.* 2000;36(4):406–7.
4. Uygur O, Esen S, Tanriverdi S, et al. Noninvasive diagnosis and continuous monitoring of local anesthetic-induced methemoglobinemia in a neonate. *Indian J Hematol Blood Transfus.* 2014;30(Suppl 1):180–2.
5. Tran AN, Koo JY. Risk of systemic toxicity with topical lidocaine/prilocaine: a review. *J Drug Dermatol.* 2014;13(9):1118–22.
6. Farmacotherapeutisch Kompas. Dutch pharmacologic manual. Available at: [https://www.farmacotherapeutischkompas.nl/bladeren-volgens-boek/preparaatteksten/lidocaine\\_prilocaine](https://www.farmacotherapeutischkompas.nl/bladeren-volgens-boek/preparaatteksten/lidocaine_prilocaine). Accessed 11 Jan 2016.
7. U.S. National Library of Medicine. DailyMed. Available at: <http://dailymed.nlm.nih.gov/dailymed/drugInfo.cfm?setid=b466c7eb-bca3-4686-ada6-325103ab06f3>. Accessed 11 Jan 2016.