

# Diagnostic performance of magnetic resonance arthrography of the shoulder in the evaluation of anteroinferior labrum abnormalities: a prospective study

Anastasia Fotiadou · Antonios Drevelegas ·  
Michelangelo Nasuto · Giuseppe Guglielmi

Received: 16 December 2012 / Revised: 13 January 2013 / Accepted: 22 January 2013 / Published online: 9 February 2013  
© The Author(s) 2013. This article is published with open access at Springerlink.com

## Abstract

**Objective** To evaluate the diagnostic performance of magnetic resonance (MR) arthrography of the shoulder in the diagnosis of anteroinferior labrum lesions, using arthroscopy as the reference standard and to classify these lesions.

**Methods** Institutional review board approval was obtained. The study population included 59 consecutive patients with history and clinical diagnosis of acute or chronic anterior shoulder instability. A total of 62 MR arthrograms were performed, since three patients had undergone a bilateral procedure. Arthroscopy, which was performed within a mean of 3 months (range 2–5 months) after MR arthrography, was used as the reference standard. Sensitivity, specificity, accuracy, positive and negative predictive values were then calculated.

**Results** MR arthrography showed a sensitivity of 96 % and a specificity of 80 % for the overall detection of anteroinferior labrum abnormalities. The diagnostic accuracy was 95 % and the positive and negative predictive values were 98 % and 66 % respectively. Ten lesions were

non-classifiable on surgery, of which eight were non classifiable on MR arthrography also.

**Conclusions** MR arthrography is highly accurate for the detection and classification of shoulder anteroinferior labrum lesions. Shoulder surgeons can confidently rely on this method to determine which patients will benefit from arthroscopy.

## Main Messages

- MR arthrography is accurate for the detection and classification of shoulder labrum lesions.
- MR arthrography is a valuable tool for the preoperative planning in acute or chronic instability.
- Shoulder surgeons can rely on this method to determine which patients will benefit from arthroscopy.

**Keywords** Shoulder · Anteroinferior labrum · MR arthrography · Arthroscopy · Shoulder instability

## Introduction

The shoulder joint is the most commonly dislocated major joint in the body. Its geometry provides the largest mobility among the other articulations but also predisposes to inherent instability [1]. The incidence of traumatic shoulder instability has been reported to be 1.7 % in the general population, with increased rates in men, athletes and the military [2]. In particular, anteroinferior dislocation is the most common type of glenohumeral instability accounting for over 90 % of all shoulder dislocations [3].

Although the labrum and the glenohumeral ligaments, particularly the inferior glenohumeral ligament (IGHL), have a critical role in the passive stabilisation of the shoulder, dynamic stabilisers are primarily muscular and include the rotator cuff, which provides a compressive stabilising effect [4, 5]. Associated injuries to the capsulolabral

A. Fotiadou (✉)  
Department of Radiology, Hinchingsbrooke Hospital NHS Trust,  
Huntingdon PE29 6NT, Cambridgeshire, UK  
e-mail: natfot@yahoo.gr

A. Drevelegas  
Department of Radiology, Aristoteleion University,  
Thessaloniki, Greece

M. Nasuto · G. Guglielmi  
Department of Radiology, Scientific Institute Hospital  
“Casa Sollievo della Sofferenza”, Viale Cappuccini 1,  
71103 San Giovanni Rotondo (FG), Italy

G. Guglielmi  
Department of Radiology, University of Foggia, Viale L. Pinto 1,  
71120 Foggia, Italy

structures have been reported in most traumatic anterior shoulder dislocations and may play an important role in predicting recurrent instability [6].

Preoperative imaging is essential to obtain a detailed description of possible lesions with excellent delineation of the anterior labrum and associated glenohumeral ligament complex [7–9]. Computed tomography (CT) and CT arthrography are optimal in the quantification of glenoid bony lesions (bony Bankart) or fractures of the humeral head (Hill-Sachs), but show several limitations in the evaluation of muscles and tendons [10, 11].

Magnetic resonance (MR) arthrography has been reported to be superior to standard magnetic resonance (MR) imaging for the detection of suspected labral and/or ligamentous abnormalities and for distinguishing partial-thickness from full-thickness tears in the rotator cuff [12]. The superiority of MR arthrography lies with the fact that the contrast injected within the joint space distends the joint capsule, outlines intra-articular structures and leaks into abnormalities. Hence, MR arthrography exploits the natural advantages gained from joint effusion [13, 14].

To the best of our knowledge, there are very few publications on the diagnostic accuracy of MR arthrography for the delineation of anteroinferior labrum abnormalities of the shoulder. In these studies, the usefulness of MR arthrography in acute and chronic shoulder instability has been established, showing its role in the preoperative planning of arthroscopic reconstructions and in the identification of patients who might profit from an open rather than an arthroscopic surgical procedure [15, 16]. However, combined studies on the accuracy of MR arthrography of the shoulder and the imaging/arthroscopic classification of the imaging features are extremely limited. The purpose of our study was to evaluate the diagnostic performance of MR arthrography of the shoulder in the diagnosis of anteroinferior labrum lesions, using arthroscopy as the reference standard and to classify these lesions.

## Materials and methods

The protocol was approved by the hospital's board. The study was a 2-year (May 2010–May 2012) prospective analysis that included 59 consecutive patients (age range 16–65 years; mean age 29.3 years; 31 female and 28 male). The inclusion criteria were: (1) history of acute or chronic (more than three episodes of dislocation during a period of more than 2 months) anterior instability of the shoulder, (2) strong clinical suspicion of shoulder instability, (3) MR arthrography of the affected shoulder and (4) subsequent arthroscopy. Exclusion criteria were: (1) previous shoulder surgery, (2) fracture of the greater tuberosity of the humerus with malalignment after reduction and (3) nerve damage

related to dislocation or reduction. In all cases initial clinical evaluation of the shoulder was performed by one experienced consultant shoulder surgeon. Those patients with strong clinical suspicion of anteroinferior labrum lesions were referred to the Radiology Department to have an MR arthrogram performed. The average time interval between the clinical and imaging appointment was 3 weeks. All MR arthrograms were performed by one experienced consultant musculoskeletal radiologist (5 years of experience). The images were interpreted for lesion depiction, location and characteristics by the same radiologist. Thereafter, the findings on the MR arthrography report were compared with the arthroscopic ones, as documented in the surgical notes of the patients, with regards to lesion presence and classification. The classification system for fibro-cartilaginous lesions of the glenoid labrum in shoulder instability, published by Faletti et al. [15] was used for the image interpretation and at arthroscopy. According to this system, in terms of grading, grade 0 corresponds to normal findings and grade I represents a tear of the glenoid labrum up to 1 cm in size. In grade II, the lesion involves the middle-inferior portion of the labrum, its size is >1 cm and is associated with a large capsule. In grade III, the lesion involves a larger portion of the labrum in all its extent, but with its bases still normally inserted. Finally, in grade IV, the anterior fibrocartilaginous glenoid labrum appears entirely discontinuous and anteriorly dislocated. In relation to the imaging criteria classification, demonstration of contrast between the glenoid and the detached labroligamentous complex with associated anterior displacement was characterised as Bankart lesion [12, 13]. An ALPSA lesion was diagnosed when medial displacement of the anteroinferior labroligamentous complex on the glenoid neck was seen [13, 14].

A lesion was classified as Perthes when a non-displaced tear of the anteroinferior labrum with intact medial periosteum was visualised [11]. If anteroinferior labrum lesions could not be assigned to one of the aforementioned categories, they were characterised as non-classifiable.

All patients underwent arthroscopy within an average of 3 months after MR arthrography. The same shoulder surgeon who did the initial clinical examination performed all arthroscopic procedures. He was blinded to the MR arthrography report. Arthroscopy was used as the reference standard, with a scope to evaluate the sensitivity, specificity, positive and negative predictive values and the diagnostic accuracy of MR arthrography.

## MRA procedure

In all cases the intra-articular injection was performed fluoroscopically under sterile conditions. The approach was anterior with the patient lying supine and the arm slightly externally rotated. The injection site was localised directly over the medial margin of the humeral head, at the junction

between the middle and lower third of the glenoid. Local anaesthetic was injected into the superficial tissues, over the site selected for joint entry. A 22-gauge spinal needle was used and its placement was confirmed with a small volume of iodinated contrast medium. Paramagnetic contrast (undiluted pre-filled 20-ml syringe of Magnevist 2 mmol/l solution for intra-articular injection, Bayer Schering Pharma, Newbury, Berkshire, UK) was then administered within the shoulder joint space. The volume injected depended on the capacity of the individual joint, but it did not exceed 15 ml. The procedure was well tolerated by all patients and there were no reactions or side effects observed.

All MR imaging scans were performed on a 1.5-T Unit (Siemens Magnetom Symphony, whole body compact, Erlangen, Germany) within 15 min after the intra-articular injection, to minimise absorption of the contrast and loss of capsular distension. All patients underwent imaging with the humerus in neutral position. The MR imaging protocol consisted of T1-weighted sequences with fat suppression in three planes (axial, coronal and sagittal). The imaging parameters were as follows: sagittal: FOV = 150, TR/TE = 951/13, coronal: FOV = 150, TR/TE = 668/13, axial: FOV = 150, TR/TE = 696/13. A STIR coronal sequence was performed in all cases as well: TR/TE = 96/29. The slice thickness was 4 mm with a gap of 0.8 mm and an acquisition of 2.

## Results

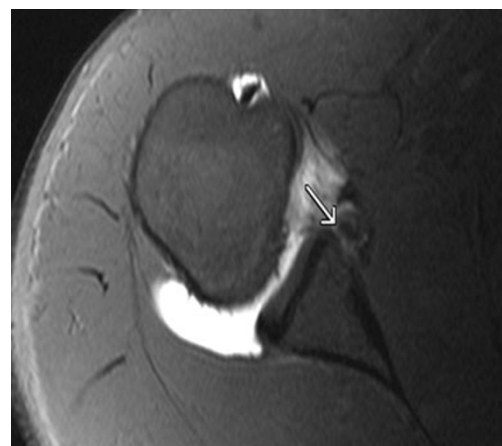In the 2-year study period, a total number of 62 MR arthrograms (mean, four patients per month; range, two to eight patients) were performed in 59 consecutive patients, since three patients underwent a bilateral procedure. In 43/59 patients the anterior instability was acute and in the remaining 16 it was chronic. Thirty-six MR arthrograms were of the right shoulder and 26 of the left one. At arthroscopy, 57 anteroinferior labrum lesions were diagnosed. Forty-seven out of 57 were classified as follows: 25 Bankart lesions, 14 ALPSA and 8 Perthes lesions. Of those, MR arthrography correctly classified all (100 %) Bankart and ALPSA lesions. In relation to Perthes lesions, MR arthrography correctly categorised 75 % of them (6/8). Based on these results, MR arthrography correctly classified 96 % (45/47) anteroinferior labrum lesions. Overall, the MR arthrography findings were positive for an anteroinferior labral abnormality in 56/62 cases. There were one false-positive and two false-negative MR arthrography cases. The false-positive case was incorrectly diagnosed on MR arthrography as ALPSA lesion, which was not confirmed at surgery. In the two false-negative MR arthrography cases, the lesions did not appear demarcated with contrast material and were arthroscopically proven to be Perthes lesions (Table 1). In total, there were 5/62 arthroscopically normal cases.

**Table 1** Comparison of correct classification of anteroinferior labrum lesions between MR arthrography and arthroscopy

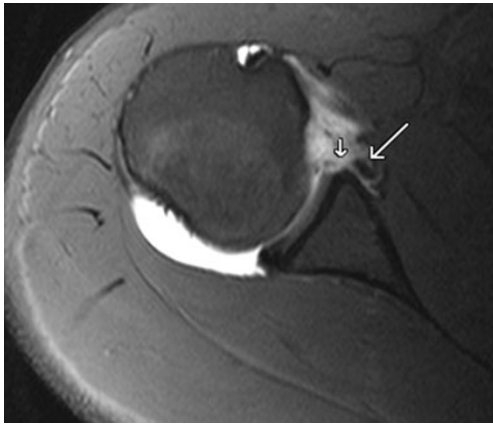
Type of lesion	Number of lesions at arthroscopy	Number of lesions on MR arthrography
Bankart	25	25
ALPSA	14	14
Perthes	8	6

The MR imaging feature seen in all Bankart lesions was avulsion of the anteroinferior labrum with associated anterior displacement (Figs. 1 and 2). In all 14 true-positive ALPSA lesions, medial displacement of the anteroinferior labroligamentous complex was detected on MR arthrography (Figs. 3 and 4). In the six cases classified as Perthes, stripped but intact medial periosteum and a non-displaced tear of the anteroinferior labrum were visualised (Fig. 5). Ten cases were non-classifiable at arthroscopy, of which eight were categorised as non-classifiable on MR arthrography as well (80 %). These were present in the group with acute instability, and significant degenerative change with scar tissue formation was seen intra-operatively. The corresponding imaging feature was loss of the triangular shape of the labrum with swelling.

In 10/16 patients with a history of chronic instability the lesions found at arthroscopy were non-classifiable. In the remaining six patients, they were classified as ALPSA. In the two Perthes false-negative MR arthrography cases, the stripped periosteum was not visualised on imaging and the tear did not appear to be delineated by contrast. MR arthrography showed a sensitivity of 96 % and a specificity of 80 % for the overall detection of anteroinferior labrum abnormalities. The diagnostic accuracy was 95 %,



**Fig. 1** Axial T1-weighted image with fat suppression, in a 35-year-old female patient with a history of acute dislocation. There is displacement and detachment of the anteroinferior labrum from the glenoid rim seen (arrow). The periosteum is disrupted also. The lesion was correctly classified as Bankart

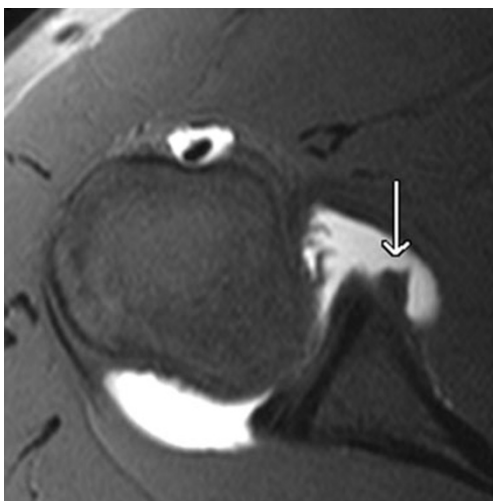


**Fig. 2** Axial T1-weighted image with fat suppression in a 21-year-old male patient with a history of acute dislocation. There is anterior displacement of the detached anteroinferior labroligamentous complex detected (*long arrow*). There is a chondral defect identified at the glenoid rim as well (*short arrow*). The lesion was correctly classified as Bankart lesion

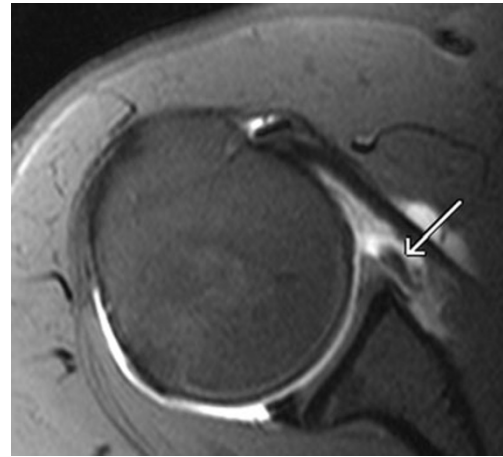
and the positive and negative predictive values were 98 % and 66 % respectively.

### Discussion

In patients with strong clinical evidence of labro-ligamentous injury of any joint, it is imperative that an accurate diagnosis is made. In such patients, it is important to establish a specific diagnostic pathway, since most of them have significant pain and restriction of movement, and inappropriate management may result to impairment [15, 16]. In all these cases, MR arthrography should be considered the imaging investigation of choice. In the shoulder joint, the intra-articular injection



**Fig. 3** Axial T1-weighted image with fat suppression, in a 34-year-old male patient with a history of chronic shoulder instability. There is medial displacement of the anteroinferior labroligamentous complex demonstrated (*arrow*), correctly categorised as an ALPSA lesion

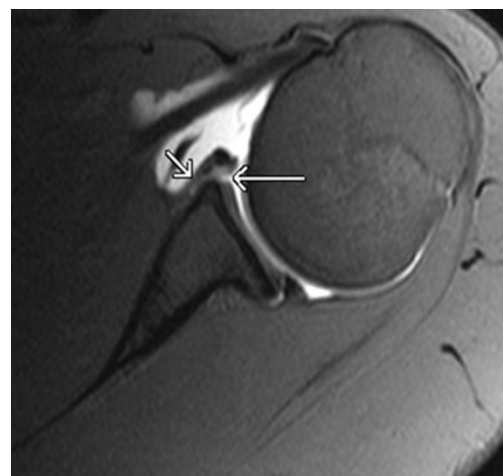


**Fig. 4** Axial T1-weighted image with fat suppression, in a 41-year-old male patient with a history of chronic shoulder instability. The detached labroligamentous complex seems to be medially displaced (*arrow*). The lesion was correctly characterised as ALPSA lesion

of contrast material allows visualisation of the glenoid labrum and glenohumeral ligaments in great detail [17, 18]. MR arthrography has also been proven to be useful in demonstrating partial-thickness articular surface supraspinatus tendon tears [19].

Arthroscopic repair of the shoulder labrum is providing considerable clinical improvement. Therefore, accurate identification of labral and glenohumeral ligament tears has become a significant diagnostic goal [20, 21]. The purpose of our study was to assess the diagnostic performance of MR arthrography in the diagnosis of anteroinferior labrum lesions, using arthroscopy as the reference standard and to classify these lesions.

Based on our results MR arthrography displayed an accuracy of 96 % for the correct classification of anteroinferior



**Fig. 5** Axial T1-weighted image with fat suppression, in a 32-year-old male patient. A tear of the anteroinferior labrum is noted (*long arrow*). The periosteum appears to be medially stripped, but intact (*short arrow*). There was correct classification of the lesion as Perthes lesion



labrum lesions and showed a sensitivity of 96 % and a specificity of 80 % for the overall detection of anteroinferior labrum abnormalities. Our results are comparable to those by Waldt et al. [14], who reported 88 % sensitivity and 91 % specificity of MR arthrography for the depiction of anteroinferior labroligamentous complex injuries. Our results are also comparable with those reported by Palmer and Caslowitz [22] who found a sensitivity of 92 % and a specificity of 92 % and Tirman et al. [23], who reported a sensitivity of 89 % and a specificity of 98 % for the detection of labral tears in patients with glenohumeral instability. However, it should be taken into consideration that in the study by Tirman et al. [23], saline was used for the MR arthrography. Also, our results are comparable with the findings in the study by Chandnani et al. [19] with reported sensitivity of 90 % and accuracy of 83 %. In this report, MR imaging, MR arthrography and CT arthrography were compared.

It should be pointed out that there was no control group in our study, which might represent a limitation. On the other hand, MR arthrography is considered to be an invasive procedure and is only performed in patients with relevant history and clinical examination findings. In addition, our study was prospective and the protocol incorporated herein reflects the everyday clinical practice, based on which there is careful selection of patients undergoing specialised imaging investigations such as MR arthrography.

Another point that should be made is that the radiologist who performed the intra-articular injections and interpreted the images was not blinded to the history and the clinical examination findings. Nonetheless, this again falls into the context of everyday clinical practice, since the radiologist who authorises the protocol for an imaging investigation should have all the relevant details in order to decide whether the request is justified or not. Moreover, the fact that only one radiologist performed the MR arthrograms and interpreted the images represents a possible bias. Inter-reader agreement could not be evaluated for this reason. Nevertheless, MR arthrograms are procedures that require skills of subspecialisation, and in district hospitals they are most commonly performed and interpreted by a single consultant. This argument becomes even stronger when the limited number of patients who undergo these investigations is taken into consideration.

With regards to the MR arthrography findings in anteroinferior labrum lesions in our study, these are consistent with the published literature [17, 24]. There was 80 % agreement between MR arthrography and arthroscopy in relation to non-classifiable cases. In these, scar tissue formation was seen during surgery, which was demonstrated as loss of the triangular shape and swelling of the anteroinferior labrum on MR arthrography. In addition, the majority of

non-classifiable lesions occurred in patients with chronic instability (10/16) which is again consistent with the published data [25].

## Conclusion

MR arthrography is highly accurate for the detection and classification of anteroinferior labrum abnormalities. MR arthrography was shown to be a valuable tool for the pre-operative planning in patients with acute or chronic instability. Shoulder surgeons can confidently rely on this method to determine which patients will benefit from arthroscopy.

**Open Access** This article is distributed under the terms of the Creative Commons Attribution License which permits any use, distribution, and reproduction in any medium, provided the original author(s) and the source are credited.

## References

- Itoi E, Lee SB, Berglund LJ, Berge LL, An KN (2000) The effect of a glenoid defect on anteroinferior stability of the shoulder after Bankart repair: a cadaveric study. *J Bone Joint Surg Am* 82:35–46
- Owens BD, Dawson L, Burks R, Cameron KL (2009) Incidence of shoulder dislocation in the United States military: demographic considerations from a high-risk population. *J Bone Joint Surg Am* 91:791–796
- Boone JL, Arciero RA (2010) Management of failed instability surgery: how to get it right the next time. *Orthop Clin N Am* 41:367–379
- Lippitt S, Matsen F (1993) Mechanisms of glenohumeral joint stability. *Clin Orthop Relat Res* 291:20–28
- Labriola JE, Lee TQ, Debski RE, McMahan PJ (2005) Stability and instability of the glenohumeral joint: the role of shoulder muscles. *J Shoulder Elbow Surg* 14:32–38
- Owens BD, Nelson BJ, Duffey ML et al (2010) Pathoanatomy of first-time, traumatic, anterior glenohumeral subluxation events. *J Bone Joint Surg Am* 92:1605–1611
- Neviaser TJ (1993) The anterior labroligamentous periosteal sleeve avulsion lesion: a cause of anterior instability of the shoulder. *Arthroscopy* 9:17–21
- Neviaser TJ (1993) The GLAD lesion: another cause of anterior shoulder pain. *Arthroscopy* 9:22–23
- Bell JE (2010) Arthroscopic management of multidirectional instability. *Orthop Clin N Am* 41:357–365
- Rhee RB, Chan KK, Lieu JG, Kim BS, Steinbach LS (2012) MR and CT arthrography of the shoulder. *Semin Musculoskelet Radiol* 16:3–14
- Fritz J, Fishman EK, Small KM et al (2012) MDCT arthrography of the shoulder with datasets of isotropic resolution: indications, technique, and applications. *AJR Am J Roentgenol* 198:635–646
- Sanders TG, Tirman PF, Linares R, Feller JF, Richardson R (1999) The glenolabral articular disruption lesion: MR arthrography with arthroscopic correlation. *AJR Am J Roentgenol* 172:171–175
- Tirman PF, Palmer WE, Feller JF (1997) MR arthrography of the shoulder. *Magn Reson Imaging Clin N Am* 5:811–839
- Waldt S, Burkart A, Imhoff AB, Bruegel M, Rummeny EJ, Woertler K (2005) Anterior shoulder instability: accuracy of MR

- arthrography in the classification of anteroinferior labroligamentous injuries. *Radiology* 237:578–583
15. Faletti C, De Filippo M, Giudice G, Larciprete M, Seccia A, Regis G (2002) Fibro-cartilaginous lesions of the glenoid labrum in shoulder instability: a proposed classification using sagittal-oblique arthro-MRI. *Radiol Med* 104:68–74
  16. Beltran J, Bencardino J, Mellado J, Rosenberg ZS, Irish RD (1997) MR arthrography of the shoulder: variants and pitfalls. *Radiographics* 17:1403–1412
  17. Stoller DW (1997) MR arthrography of the glenohumeral joint. *Radiol Clin N Am* 35:97–116
  18. Green MR, Christensen KP (1994) Magnetic resonance imaging of the glenoid labrum in anterior shoulder instability. *Am J Sports Med* 22:493–498
  19. Chandnani VP, Yeager TD, DeBerardino T et al (1993) Glenoid labral tears: prospective evaluation with MRI imaging, MR arthrography, and CT arthrography. *AJR Am J Roentgenol* 161:1229–1235
  20. Schaeffeler C, Mueller D, Kirchhoff C, Wolf P, Rummeny EJ, Woertler K (2011) Tears at the rotator cuff footprint: prevalence and imaging characteristics in 305 MR arthrograms of the shoulder. *Eur Radiol* 21:1477–1484
  21. Jonas SC, Walton MJ, Sarangi PP (2012) Is MRA an unnecessary expense in the management of a clinically unstable shoulder? a comparison of MRA and arthroscopic findings in 90 patients. *Acta Orthop* 83:267–270
  22. Palmer WE, Caslowitz PL (1995) Anterior shoulder instability: diagnostic criteria determined from prospective analysis of 121 MR arthrograms. *Radiology* 197:819–825
  23. Tirman PF, Stauffer AE, Crues JV 3rd et al (1993) Saline magnetic resonance arthrography in the evaluation of glenohumeral instability. *Arthroscopy* 9:550–555
  24. Aliprandi A, Fausto A, Quarenghi M, Modestino S, Randelli P, Sardanelli F (2006) One-shot CT and MR arthrography of the shoulder with a mixture of iodinated and paramagnetic contrast agents using arthroscopy as a gold standard. *Radiol Med* 111:53–60
  25. Volpi D, Olivetti L, Budassi P, Genovese E (2003) Capsulo-labroligamentous lesions of the shoulder: evaluation with MR arthrography. *Radiol Med* 105:162–170