Can J Anesth/J Can Anesth (2020) 67:754–755
https://doi.org/10.1007/s12630-020-01625-4

IMAGES

Chest computed tomography images of early coronavirus disease (COVID-19)

Rong Chen, MD · Jun Chen, MD · Qing-tao Meng, MD, PhD

Received: 7 March 2020 / Revised: 8 March 2020 / Accepted: 9 March 2020 / Published online: 11 March 2020

Severe acute respiratory syndrome-related coronavirus (SARS-CoV-2) has rapidly spread throughout China and as of 8 March 2020 has spread to over 100 countries with 105,000 confirmed cases of coronavirus-related disease (COVID-19).[1] The high infectivity and mortality of COVID-19 makes this a serious public health threat.[2] Recent studies have confirmed that fever, dry cough, and fatigue are the main manifestations.[3] Some patients have other symptoms, such as nasal congestion, runny nose, sore throat, myalgia, and diarrhea. Seriously-ill patients may develop dyspnea and/or hypoxemia one week after the onset of symptoms, and critically-ill patients can quickly progress to acute respiratory distress syndrome, septic shock, severe metabolic acidosis, coagulopathy, and multiple organ dysfunction syndrome.[3]

We report a 27-yr-old pregnant woman at 36 weeks gestation who was admitted to the hospital with fever, dry cough, and fatigue as the main manifestations. Her SARS-CoV-2 reverse transcriptase polymerase chain reaction (RT-PCR) test was positive and although she developed

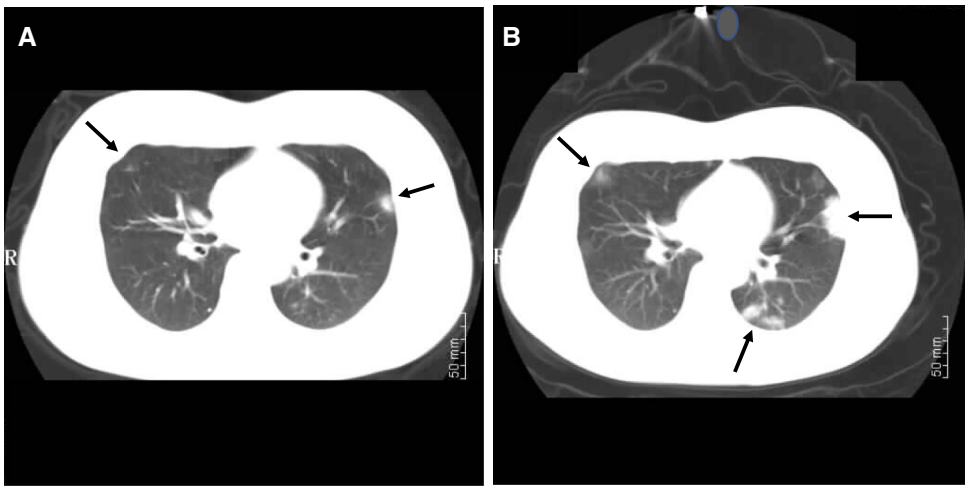

Figure Chest computed tomography (CT) scan at the time of admission (A) of a 27-yr-old 36-week pregnant woman with coronavirus disease (COVID-19). The CT scan shows the characteristic peripheral (and/or subpleural) ground-glass opacities. These are seen in the left lower lobe/lingula junction and in the right middle lobe (arrows). Two days after admission (B), the size, density, and distribution of these opacities had progressed (arrows)

Rong Chen and Jun Chen authors contributed equally to this work

R. Chen, MD · Q. Meng, MD, PhD (✉)
Department of Anesthesiology, Renmin Hospital of Wuhan University, Wuhan, China
e-mail: mengqingtao2018@126.com

Department of Anesthesiology, East Hospital, Renmin Hospital of Wuhan University, Wuhan, China

J. Chen, MD
Department of Radiology, Renmin Hospital of Wuhan University, Wuhan, China

tachypnea, she did not develop significant hypoxemia. After admission, a computed tomography (CT) scan (Figure A) revealed the typical COVID-19 findings of patchy peripheral and subpleural ground-glass opacities[4] in the left lower lobe/lingula junction. The right middle lobe of the lung also showed a small subpleural opacity of uneven density and blurred margins. Two days after admission, a repeat CT scan showed (Figure B) the number, density, and size of the lesions. Because of concern about potential further progression of the COVID-19 pulmonary manifestations, an uncomplicated elective Cesarean delivery was performed. The RT-PCR for SARS-CoV-2 was negative in the neonate.

Conflicts of interest None.

Funding statement None.

Editorial responsibility This submission was handled by Dr. Hilary P. Grocott, Editor-in-Chief, *Canadian Journal of Anesthesia.*

References

1. *World Health Organization.* Coronavirus disease 2019 (COVID-19) Situation Report – 48. Available from URL: https://www.who.int/docs/default-source/coronaviruse/situation-reports/20200308-sitrep-48-covid-19.pdf?sfvrsn=16f7ccef_4 (accessed March 2020).
2. *Yang X*, *Yu Y*, *Xu J*, *et al*. Clinical course and outcomes of critically ill patients with SARS-CoV-2 pneumonia in Wuhan, China: a single-centered, retrospective, observational study. Lancet Respir Med 2020; . https://doi.org/10.1016/s2213-2600(20)30079-5.
3. *Huang C*, *Wang Y*, *Li X*, *et al*. Clinical features of patients infected with 2019 novel coronavirus in Wuhan, China. Lancet 2020; 395: 497-506.
4. *Li Y*, *Xia L*. Coronavirus Disease 2019 (COVID-19): Role of chest CT in diagnosis and management. AJR Am J Roentgenol 2020; . https://doi.org/10.2214/AJR.20.22954.