

Significance of persistence of antibodies against *Leishmania infantum* in sicilian patients affected by acute visceral leishmaniasis

Pasquale Mansueto · Ilenia Pepe · Aurelio Seidita · Francesca Scozzari · Giustina Vitale · Francesco Arcoleo · Inglese Elvira · Enrico Cillari · Giovam Battista Rini · Nicola Napoli · Salvatore Di Rosa · Serafino Mansueto · Gaetana Di Fedè

Received: 2 March 2011 / Accepted: 13 June 2011 / Published online: 29 June 2011
© Springer-Verlag 2011

Abstract The background of this article is as follows: Few data are available about the persistence of serum-specific IgG antibodies to *L. infantum* after acute VL. The objective of this article is to evaluate the persistence of antibodies against *L. infantum* in patients healed from acute VL, and the kinetic of the same antibodies observed in 2 cases of VL relapse and 2 cases of resistance to therapy. The methods which we used to obtain our objective are the following: 55 apparently immunocompetent, HIV-negative patients were examined for antibodies to *L. infantum* by IFAT over 14 years period, and we got the following

results: Serum-specific IgG antibodies titers decrease slowly, but constantly. In the patients with a diagnosis of VL relapse, the kinetic of antibodies was characterized by an initial reduction, and a subsequent antibody levels rapidly increase, while in the patients with a clinical and parasitological diagnosis of VL not responding to specific therapy, we demonstrated persistent high level of antibodies to *L. infantum*. Finally, we conclude that specific antibodies to *L. infantum* might persist for many years, and decrease slowly, but steadily. The persistence of these specific antibodies is not related to poor therapeutic response or prognosis, but an acute increase in their levels might be a sentinel of a VL relapse, while persistence of high antibody levels could suggest a resistance to therapy.

This paper is dedicated to the memory of our Prof. Serafino Mansueto who devoted a large part of his life and his scientific work and research to the study of visceral leishmaniasis, with inexhaustible passion and interest.

P. Mansueto (✉) · I. Pepe · A. Seidita · F. Scozzari · G. Vitale · G. B. Rini · S. Mansueto
Dipartimento di Medicina Clinica e delle Patologie Emergenti,
University of Palermo, Via del Vespro, 141,
90146 Palermo, Italy
e-mail: pamansu@unipa.it

F. Arcoleo · I. Elvira · E. Cillari
Unità Operativa Complessa di Patologia Clinica,
Azienda Ospedaliera Ospedali Riuniti ‘Villa Sofia-Cervello’,
Palermo, Italy

N. Napoli
Washington University, St. Louis, MO, USA

S. Di Rosa
Azienda Ospedaliera Ospedali Riuniti ‘Villa Sofia-Cervello’,
Palermo, Italy

G. Di Fedè
Dipartimento di Discipline Chirurgiche ed Oncologiche,
University of Palermo, Palermo, Italy

Keywords Visceral leishmaniasis · *L. infantum* · Kinetic of antibodies · Persistence of antibodies · VL relapse · VL resistance

Abbreviations

VL Visceral leishmaniasis
IFAT Immunofluorescent antibody test

Introduction

Visceral leishmaniasis (VL), caused by *Leishmania (L.) infantum* and transmitted to human by the bite of hematophagous sandflies belonging to *Phlebotomus* spp., is endemic in areas bordering the Mediterranean sea (Spain, France, Italy, Greece, Morocco, Tunisia, etc.) [1]. In Italy, in the years 1996–2005 were reported 1,507 cases, of which 316 (20.9%) (Istituto Nazionale di Statistica, ISTAT, data) in Sicily [2].

Diagnosis of VL is carried out on the basis of clinical signs and symptoms (fever, hepatosplenomegaly, pancytopenia, hypergammaglobulinemia, detection of serum anti-*Leishmania* antibodies) and/or microscopic detection of *Leishmania* promastigotes in Giemsa-stained smears of bone marrow aspirates and/or biopsy, or lymph node or spleen aspiration [3].

Methods for detection of parasite-specific antibodies employ enzyme-linked immunosorbent assay (ELISA), indirect immunofluorescent antibody test (IFAT), and Western blotting. Furthermore, *Leishmania*-specific polymerase chain reaction (PCR) of peripheral blood is used to confirm parasite infection [3]. It is commonly accepted that it is possible to detect only the presence of serum-specific IgG antibodies, given that the appearance and disappearance of serum-specific IgM antibodies occurs rapidly, always before a specific diagnosis of VL could be made [4–6].

Serological tests may remain positive for long periods of time, after VL-specific treatment and apparent healing, although decreases in antibodies titers are evident [7]. In some studies, the persistence of antibodies for prolonged periods after treatment appears to indicate a therapeutic inefficacy or also the possibility of disease reactivation, while in other reports, there is not any indication of a poor prognosis and/or a risk of VL relapse [7–13].

In this study, we have analyzed, together with clinical signs, the persistence of serum IgG antibodies against *L. infantum* in sicilian patients with VL, admitted consecutively to our hospital, both cured after acute episode, and with relapse or resistance to specific therapy.

Materials and methods

Patients

The study was performed in our *Dipartimento di Medicina Clinica e delle Patologie Emergenti*, which acts as referral adult Medical Centre for all western Sicily (Italy), considered an endemic area for VL. Fifty-five apparently immunocompetent, HIV-negative patients, clinically healed after an effective treatment of an acute episode of VL, were examined over a 14 years period (January 1992–December 2006) for serum IgG antibodies to *L. infantum*. The samples were collected during the acute phase of the disease (basal), every 6 months for the first year after the treatment and every 12 months for the subsequent 14 years after the treatment. All patients were also submitted to clinical examination.

We also examined the persistence and kinetic of serum IgG antibodies to *L. infantum* in 2 patients with a diagnosis of VL relapse and 2 with resistance to specific therapy.

Whole blood (5 ml) was collected into sterile tubes at the acute phase stage and at the follow-up stage. Blood was allowed to coagulate for 2–3 h at 4°C prior to centrifugation. Serum samples were preserved at –20°C until analysis.

Diagnosis of acute VL was based on clinical symptoms, such as persistent irregular fever, pallor, weight loss, hepatosplenomegaly, anemia, neutropenia, thrombocytopenia, hypergammaglobulinemia, and was confirmed by the presence of antibodies against *L. infantum*, detected by IFAT, and of *L. infantum* bodies in bone marrow aspirates and/or biopsy, and in some cases, also with parasites isolation and culture from bone marrow aspirates and/or biopsy, and/or from peripheral blood. VL patients were treated with a complete course of meglumine antimoniate (MA, 20 mg/kg daily, by intramuscular injection, for 4 weeks) [9, 14] or liposomal amphotericin B (1–3 mg/kg daily, for 5 days, with a final dose at 11th day, with no incremental dosage, infused slowly over 2 h). Patients were considered cured and discharged when fever subsided, and there was weight gain and absence of *L. infantum* bodies in the bone marrow aspirates and/or biopsy. By these criteria, all the patients were considered clinically cured. During the follow-up period, none of the examined patients showed signs or symptoms of active disease. VL relapse was defined by the recurrence of a clinical and parasitological (i.e., stained preparations from bone marrow aspirate and/or biopsy) diagnosis of *L. infantum* infection, after specific treatment of the disease [15].

Informed, written consent from all participants and the approval of the ethical committee of our institution were obtained for this study.

IFAT for *L. infantum*

All sera were analyzed by IFAT, using “in-house antigen” to increase tests sensitivity [16].

In details, promastigotes of *L. infantum* (zymodeme MON-1), previously isolated from a VL patient, identified as *L. infantum*, and then cultivated in our laboratory, were propagated in Medium 199 (Gibco, Milan, Italy), supplemented with 25 mM HEPES (Gibco, Milan, Italy) and 10% fetal calf serum (Gibco, Milan, Italy). After 48 h of incubation at 27°C, whole parasites were collected by centrifugation, washed three times in cold phosphate-buffered saline (PBS, Bio-Merieux, Rome, Italy), and then fixed on slides (Bio-Merieux, Rome, Italy), until to obtain 30–40 parasites for microscopic field. Anti-*L. infantum* serum-specific IgG antibodies were then evaluated as previously described [17, 18].

The lower limit of positivity (cut-off) has been set to discriminate optimally between sera of clinical documented cases of VL and normal human sera. All samples

showing a titer at a dilution $\geq 1:100$ were considered to be positive.

To ensure comparable results over more than 10 years, we tested all the samples with the same antigen batch, and the assays were carried out by the same operator.

Results

Of the 55 patients studied, 67% were men (mean age 45 ± 11 , range 16–85 years) and 33% were women (mean age 32 ± 9 , range 22–63 years). Twelve were treated with MA and 33 with liposomal amphotericin B.

In Fig. 1 is reported the box plot analysis of the kinetic of specific IgG antibodies to *L. infantum*, examined in different periods of time, after the onset of acute VL, in cured and apparently healed subjects. To linearize the relation between time and results, we expressed them in a logarithmic scale. After acute VL and VL-specific treatment, serum-specific IgG antibodies titers, detected in the 100% of the examined cases during the acute phase of the disease, decreased slowly, but constantly, from a seropositivity of 98.1% at 6 months to a seropositivity of 16.3% at 72 months. During the follow-up, antibodies to *L. infantum* persisted mainly at low levels (from 1:100 to 1:200) until their disappearance in 4–6 years. In 8 patients (14.5%), specific antibodies to *L. infantum* were detected even after 14 years after acute VL and VL-specific treatment, at low-medium titers (from 1:100 to 1:1,600), without any symptoms/signs of persistent or relapsing VL.

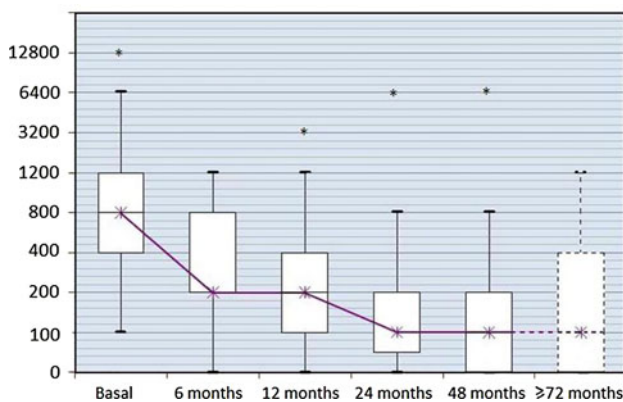


Fig. 1 Box plot analysis of the kinetic of specific IgG antibodies to *L. infantum*, examined in different periods of time, after the onset of acute VL, in cured and apparently healed subjects. Titres are expressed in logarithmic scale. The results represented by “*” are anomaly in the statistical analysis and they are not considered in box plot elaboration [27]. The last box because of scanty number of cases should not be considered, even if the trend of population is not different from the previous one

In Table 1, we showed the anti-*L. infantum* antibodies kinetic of 2 patients with a diagnosis of VL relapse and 2 with a diagnosis of resistance to specific therapy. The first two patients (no. 1 and no. 2) had a clinically and parasitological confirmed relapse of VL, probably due to an inadequate anti-*Leishmania* therapy, carried out in other hospitals. In these two patients, clinically cured after the first cycle of treatment, the kinetic of specific antibodies to *L. infantum* was characterized by an initial reduction, after the first VL episode, and a subsequent antibody levels increase 12 and 24 months afterward, respectively, consistent to a sentinel epiphenomenon of a contemporary clinically and parasitological confirmed VL recurrence. We successfully treated both patients with liposomal amphotericin B. After these therapy cycles, the antibody titers decreased under the cut-off level, remaining negative during a 6 years follow-up. The other two patients (no. 3 and no. 4) had a clinical and parasitological diagnosis of VL not responding to specific therapy, and persistent high levels of antibodies to *L. infantum*, as expression of resistance to therapy. Then, the patients were successfully treated with liposomal amphotericin B and antibody levels reduced significantly in a few months, until to disappear, persisting at negative titer in the following 6 years.

Discussion

Based on the results of our study, patients specifically cured and apparently healed after an acute episode of VL could be divided into three subtypes of antibody response: (1) patients whose anti-*L. infantum* antibodies disappear within 2 years after diagnosis and treatment, as just reported in the literature [7–13]; (2) patients showing low antibody titers for 4–6 years; and (3) patients whose antibody titers remain constantly at low-medium levels for more than 6 years.

Considering our cases of VL relapse and resistance to specific therapy, it is possible to hypothesize that monitoring of *L. infantum* antibody levels, both in case of acute and not apparently motivated increase of antibody levels and of persistence of high antibody levels, respectively, might be useful for a better definition of these two conditions. However, other studies are required, with more patients and adequate controls.

In few patients (8 of 55, 14.5%), we found detectable, at low-medium concentrations (from 1:100 to 1:1,600), serum IgG antibodies to *L. infantum* after more than 72 months (up to 14 years after acute VL and specific VL treatment). In all these subjects, we did not diagnose a relapsing disease or a resistance to specific therapy. However, the ethical committee of our institution did not consider ethically acceptable to submit these apparently seropositive healthy

Table 1 Kinetic of anti-*L. infantum* antibodies levels in 2 patients with a diagnosis of VL relapse and 2 with resistance to specific therapy

Patient no.	Medication	Second treatment	Antibody titers											
			Basal	1–2 months	3–4 months	5–6 months	7–9 months	10–12 months	2 years	4 years	6 years			
1 (relapse)	Amphotericin B lipid complex, 3 mg/kg daily, for 5 days, with a final dose at 11th day	Liposomal amphotericin B, 200 mg from 1st day to 10th day, with a final dose of 200 mg at 13th day	1:400	1:400	1:100	–	1:200	1:800	1:200	1:200	1:200	1:200	1:200	1:100
2 (relapse)	Liposomal amphotericin B, 50 mg at 1st day, 150 mg from 2nd to 4th day, and 200 mg from 5th to 7th day	Liposomal amphotericin B, 3 mg/kg daily, for 5 days, with a final dose at 11th day	1:400	1:200	–	1:800	–	–	–	–	–	1:6,400	1:6,400	<1:100
3 (resistance)	3 cycles of meglumine antimoniato, 20 mg/kg daily, for 3 weeks, every 3 months	Liposomal amphotericin B, 3 mg/kg daily, for 5 days, with a final dose at 11th day	1:400	1:400	1:1,600	1:800	–	–	–	–	–	1:800	1:400	1:100
4 (resistance)	1 cycle of meglumine antimoniato, 20 mg/kg daily, for 5 weeks	Liposomal amphotericin B, 50 mg at 1st and 2nd day, 250 mg from 3rd to 6th day, with a final dose of 250 mg at 13th day	1:400	1:400	–	1:400	1:800	1:400	1:800	1:400	1:400	–	–	<1:100

Patient no. 1 started second treatment 16 months after the first treatment; patient no. 2 started second treatment 4 years after the first treatment; patient no. 3 and no. 4 started second treatment 24 months after the first treatment

subjects to a bone marrow aspirate and/or biopsy to detect a possible, criptic, *L. infantum* infection.

The biologic significance of persistent serum IgG antibodies to *L. infantum* in patients cured and apparently healed form VL is still unclear. One explanation might be that individuals with VL do not show complete elimination of the parasite. This agrees with the opportunistic occurrence of the diseases, as observed in patients with AIDS [19–25].

We think that positive serologic results in patients treated for VL, and apparently healed, did not indicate poor therapeutic response or prognosis. In this contest, some studies have demonstrated that serological tests for VL (i.e., ELISA using rK39, rK26, and crude *Leishmania* antigen) in VL patients after clinical cure might continue to be positive after treatment of the disease and cannot be used as an indicator of an adverse therapeutic and prognostic evolution [9, 26].

Even though other studies have demonstrated the persistence of antibodies to *L. infantum* for long time, this is the first report showing a persistence of them up to 14 years. The principal limitation of our research is the few patients studied, but it is important to consider that the disease is not particularly frequent in our geographic area [2].

In conclusion, our results, confirming and extending previous studies [7–13], showed that specific antibodies to *L. infantum* might persist for many years, and decrease slowly, but steadily. The persistence of these specific antibodies, at low-medium levels, is not related to poor therapeutic response or prognosis, but an acute increase in their levels, or the persistence of high antibody levels, might be useful in identifying LV relapse or resistance to specific therapy.

Acknowledgments This study was supported by grants from MIUR (Italian University and Research Ministry), former 60% funds, to Pasquale Mansueto. No support was received from the pharmaceutical and diagnostic industry.

Conflict of interest The authors declare they have no conflict of interest.

References

- Dujardin JC, Campino L, Cañavate C, Dedet JP, Gradoni L, Soteriadou K, Mazeris A, Ozbel Y, Boelaert M (2008) Spread of vector-borne diseases and neglect of Leishmaniasis. *Europe Emerg Infect Dis* 14(7):1013–1018
- <http://www.istat.it/sanita/Health>
- Chappuis F, Sundar S, Hailu A, Ghalib H, Rijal S, Peeling RW, Alvar J, Boelaert M (2007) Visceral leishmaniasis: what are the needs for diagnosis, treatment and control? *Nat Rev Microbiol* 5(11):873–882
- Mansueto P, Vitale G, Di Lorenzo G, Rini GB, Mansueto S, Cillari E (2007) Immunopathology of leishmaniasis: an update. *Int J Immunopathol Pharmacol* 20(3):435–445
- Anam K, Afrin F, Banerjee D, Pramanik N, Guha SK, Goswami RP, Gupta PN, Saha SK, Ali N (1999) Immunoglobulin subclass distribution and diagnostic value of *Leishmania donovani* antigen-specific immunoglobulin G3 in Indian kala-azar patients. *Clin Diagn Lab Immunol* 6:231–235
- Da Matta VL, Hoshino-Shimizu S, Dietze R, Corbett CE (2000) Detection of specific antibody isotypes and subtypes before and after treatment of American visceral leishmaniasis. *J Clin Lab Anal* 14:5–12
- Cascio G (1970) Behavior of antibodies (titrated by means of the immunofluorescence test) in visceral leishmaniasis treated by antimony therapy. *Pediatrics* 78(3):497–504
- Avila JL, Rojas M, García L (1998) Persistence of elevated levels of galactosyl-alpha(1–3)galactose antibodies in sera from patients cured of visceral leishmaniasis. *J Clin Microbiol* 26(9):1842–1847
- De Almeida Silva L, Romero HD, Prata A, Costa RT, Nascimento E, Carvalho SF, Rodrigues V (2006) Immunologic tests in patients after clinical cure of visceral leishmaniasis. *Am J Trop Med Hyg* 75(4):739–743
- Hailu A (1990) Pre- and post-treatment antibody levels in visceral leishmaniasis. *Trans R Soc Trop Med Hyg* 84(5):673–675
- Londner MV, Feinsod FM, Faris R, Rosen G, el Said S, Saah AJ (1988) Persistence of human leishmanial antibodies in an endemic area of visceral leishmaniasis in El Agamy, Egypt. *Eur J Epidemiol* 4(4):473–476
- Musa AM, Khalil EA, Raheem MA, Zijlstra EE, Ibrahim ME, Elhassan IM, Mukhtar MM, El Hassan AM (2002) The natural history of Sudanese post-kala-azar dermal leishmaniasis: clinical, immunological and prognostic features. *Ann Trop Med Parasitol* 96(8):765–772
- Mokrani T, Belazzoug S, Bouzid Z, Keddari M (1988) Development of antibodies in children treated for visceral leishmaniasis. *Arch Inst Pasteur Alger* 56:101–107
- Cascio A, Colomba C, Antinori S, Orobello M, Paterson D, Titone L (2002) Pediatric visceral leishmaniasis in Western Sicily, Italy: a retrospective analysis of 111 cases. *Eur J Clin Microbiol Infect Dis* 21(4):277–282
- Pasquau F, Ena J, Sanchez R, Cuadrado JM, Amador C, Flores J, Benito C, Redondo C, Lacruz J, Abril V, Onofre J (2005) Leishmania HIV Mediterranean Co-operative Group. Leishmaniasis as an opportunistic infection in HIV-infected patients: determinants of relapse and mortality in a collaborative study of 228 episodes in a Mediterranean region. *Eur J Clin Microbiol Infect Dis* 24(6):411–418
- Leishmania/HIV co-infection, south-western Europe, 1990–1998 (1999) *Wkly Epidemiol Rec* 74:365–375
- Mansueto S, Vitale G, Miceli MD, Montaperto B, Alberti L, Quartararo P (1982) Valutazione di quattro tests (latex-agglutinazione, controimmuno-elettroforesi, emoagglutinazione indiretta ed ELISA) nella diagnostica della Leishmaniosi umana. *Acta Medit Patol Inf Trop* 1(S):75–85
- Mansueto S, Vitale G, Mocciaro C, Librizzi R, Friscia I, Usticano V, Gambino G, Reina G (1989) Laboratory diagnosis of bou-tonneuse fever by enzyme-linked immunosorbent assay. *Trans R Soc Trop Med Hyg* 83(6):855–857
- Alvar J, Aparicio P, Aseffa A, Den Boer M, Cañavate C, Dedet JP, Gradoni L, Ter Horst R, López-Vélez R, Moreno J (2008) The relationship between leishmaniasis and AIDS: the second 10 years. *Clin Microbiol Rev* 21(2):334–359
- Bern C, Jha SN, Joshi AB, Thakur GD, Bista MB (2000) Use of the recombinant K39 dipstick test and the direct agglutination test in a setting endemic for visceral leishmaniasis in Nepal. *Am J Trop Med Hyg* 63(3–4):153–157

21. Kaul P, Malla N, Kaur S, Mahajan RC, Ganguly NK (2000) Evaluation of a 200-kDa amastigote-specific antigen of *L. donovani* by enzyme-linked immunosorbent (ELISA) for the diagnosis of visceral leishmaniasis. *Trans R Soc Trop Med Hyg* 94(2):173–175
22. Singh S, Gilman-Sachs A, Chang KP, Reed SG (1995) Diagnostic and prognostic value of K39 recombinant antigen in Indian leishmaniasis. *J Parasitol* 81(6):1000–1003
23. Singh S, Kumari V, Singh N (2002) Predicting kala-azar disease manifestation in asymptomatic patients with latent *Leishmania donovani* infection by detection of antibody against recombinant k39 antigen. *Clin Diagn Lab Immunol* 9(3):568–572
24. Singh S, Sivakumar R (2003) Recent advances in the diagnosis of leishmaniasis. *J Postgrad Med* 49(1):55–66
25. Sundar S, Rai M (2002) Laboratory diagnosis of visceral leishmaniasis. *Clin Diagn Lab Immunol* 9(5):951–958
26. Houghton RL, Petrescu M, Benson DR, Skeiky YA, Scalone A, Badaró R, Reed SG, Gradoni L (1998) A cloned antigen (recombinant K39) of *Leishmania chagasi* diagnostic for visceral leishmaniasis in human immunodeficiency virus type 1 patients and a prognostic indicator for monitoring patients undergoing drug therapy. *J Infect Dis* 177(5):1339–1344
27. Cleveland WS (1993) *Visualizing data*. At & T Bell Laboratories, Murray Hill