



# Clinical and imaging features of diabetic striatopathy: report of 6 cases and literature review

Yuanyuan Xu<sup>1</sup> · Qiang Shi<sup>1</sup> · Yun Yue<sup>2</sup> · Chengxin Yan<sup>1</sup>

Received: 29 June 2022 / Accepted: 9 August 2022 / Published online: 15 August 2022  
© Fondazione Società Italiana di Neurologia 2022

## Abstract

**Objective** To explore the clinical manifestations, diagnosis, treatment, and pathogenesis of diabetic striatopathy (DS) to improve the understanding of the disease and avoid misdiagnosis or underdiagnosis.

**Methods** The clinical, laboratory, and imaging data of 6 patients (5 Asian females and 1 Asian male) with diabetic striatum were analyzed retrospectively, and the related literature was reviewed.

**Results** All 6 patients showed hyperglycemia, 5 patients presented with involuntary movement of unilateral limbs, and 1 with unilateral limb numbness. Besides, 5 patients (except case 3) underwent MRI examinations that showed hyperintensity in unilateral caudate and lentiform nucleus on T1-weighted images. And all 6 patients who underwent brain CT examinations showed hyperdensity or isodensity in unilateral caudate and lentiform nucleus. None had a family history of similar abnormal movements. After blood glucose control and symptomatic support treatment, the symptoms of all patients improved to various degrees, and reexaminations showed that the lesions gradually disappeared.

**Conclusion** Diabetic striatal disease is a rare complication of diabetes mellitus, the result of a combination of different pathogenesis. It is characterized by hyperglycemia, hemichorea, and contralateral striatal T1WI hyperintensity or CT hyperdensity. Both ketosis and nonketotic hyperglycemic hemichorea have typical imaging manifestations. The prognosis is excellent when this disease is detected early, and the lesions can be gradually absorbed and dissipated with glyceemic control.

**Keywords** Diabetic striatopathy · Hyperglycemia · Hemichorea · Magnetic resonance image · Computed tomography

## Introduction

Diabetic striatopathy (DS) is one of the rare and life-threatening complications of diabetes mellitus [1]. It has been usually described in diabetic patients with poor glycaemic control, especially in elderly Asian females with type 2 diabetes mellitus. The onset of the disease presents multiple neurological dysfunctions, especially involuntary movements, including hemiballism and hemichorea. The

typical neuroimaging features of the contralateral striatum are hyperdensity on CT scans and hyperintensity on T1-weighted MR images [2, 3]. In clinical practice, DS has various manifestations. Therefore, it is less recognizable and easily misdiagnosed or underdiagnosed. In this study, the clinical, laboratory, and imaging data of 6 DS patients were retrospectively analyzed, and the related literature was reviewed to improve the understanding of DS.

## Case presentations

### Case 1

A 72-year-old woman diagnosed with type 2 diabetes mellitus 1 year ago and managed with insulin, in addition to a history of hypertension and coronary heart disease, presented with involuntary movements involving her left arm and left leg, and the movements had not spread to her trunk and other limbs, or to face. Laboratory examinations showed

Chengxin Yan and Yun Yue were co-corresponding authors of this work.

✉ Chengxin Yan  
ychx6117@163.com

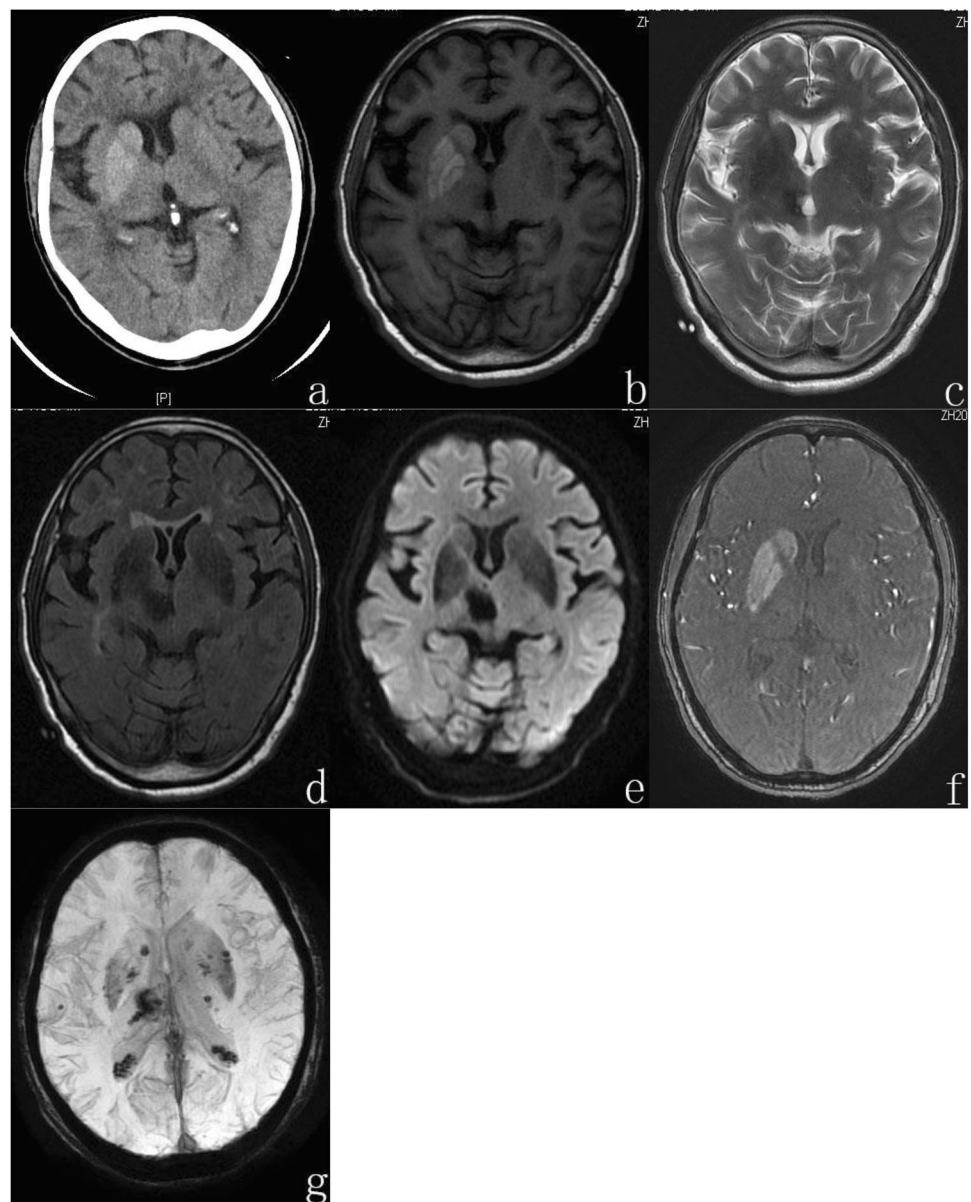
<sup>1</sup> Department of Medical Imaging, The Second Affiliated Hospital of Shandong First Medical University, Taian 271000, Shandong, China

<sup>2</sup> Department of Hyperbaric Oxygen, The Second Affiliated Hospital of Shandong First Medical University, Taian 271000, Shandong, China

blood glucose 24.0 mmol/L, urinary ketone bodies (++) , HbA1c 20.07%, serum osmolality 305 mOsm/L, urine glucose (++) , leukocyte count  $14.35 \times 10^9$ , and proportion of neutrophils 80%, with normal renal, liver, and thyroid function tests. The serum ceruloplasmin was normal and no KF ring was found in the cornea. On clinical examination, body temperature was 36.6 °C, pulse rate was 101 beats/min, respiratory rate was 18 breaths/min, and blood pressure was 171/111 mmHg. On neurological examination, she had brief involuntary movements of the left upper limb; this was accompanied by brief non-rhythmic repetitive movements at the left leg. The examinations of dysarthria, postural instability ataxia, and myoclonus are negative. The muscle strength examination of the limbs was not conducted due to the patient's noncooperation; the muscle tone was

slightly low. As for radiological images on admission, head CT showed that the right caudate and lenticular nucleus were hyperdensity with a value of about 56 Hu (Fig. 1a), and chest CT showed pulmonary inflammation. After all the examination, the patient was given a subcutaneous injection of insulin to control blood glucose and therapies related to maintaining electrolyte balance and controlling blood pressure. On day 3, CT reexamination showed hyperdensity in the right caudate and lentiform nucleus, with a similar extent as before. Pulmonary inflammation was also obviously reduced. MRI was performed, and the right caudate and lentiform nucleus showed hyperintensity on T1-weighted images, hypointensity on T2-weighted images, hypointensity on fluid-attenuation inversion recovery (FLAIR) sequences, hyperintensity on MRA source images, hypointensity on

**Fig. 1** Imaging examinations of case 1. Computed tomography (CT) of the brain on July 30, 2020 (a) and magnetic resonance imaging (MRI) of the brain on August 2, 2020 (b–e) and August 6, 2020 (f, g). (a) The unenhanced axial CT images showed hyperdensity in the right caudate and lentiform nucleus, and the CT values was about 56 Hu. (b) The right caudate and lentiform nucleus showed hyperintensity on T1-weighted images. (c) The right caudate and lentiform nucleus indicated hypointensity on T2-weighted images. (d) The right caudate and lentiform nucleus with hypointensity on fluid-attenuation inversion recovery (FLAIR) sequences. (e) The right caudate and lentiform nucleus showed hyperintensity by diffusion weighted imaging (DWI), and the ADC value of the abnormal lesion center was  $0.641 \times 10^{-3} \text{ mm}^2/\text{s}$ . (f) The right caudate and lentiform nucleus with hypointensity on MRA source images. (g) The bilateral basal ganglia showed isointensity with punctate hypointensity on susceptibility weighted imaging (SWI)



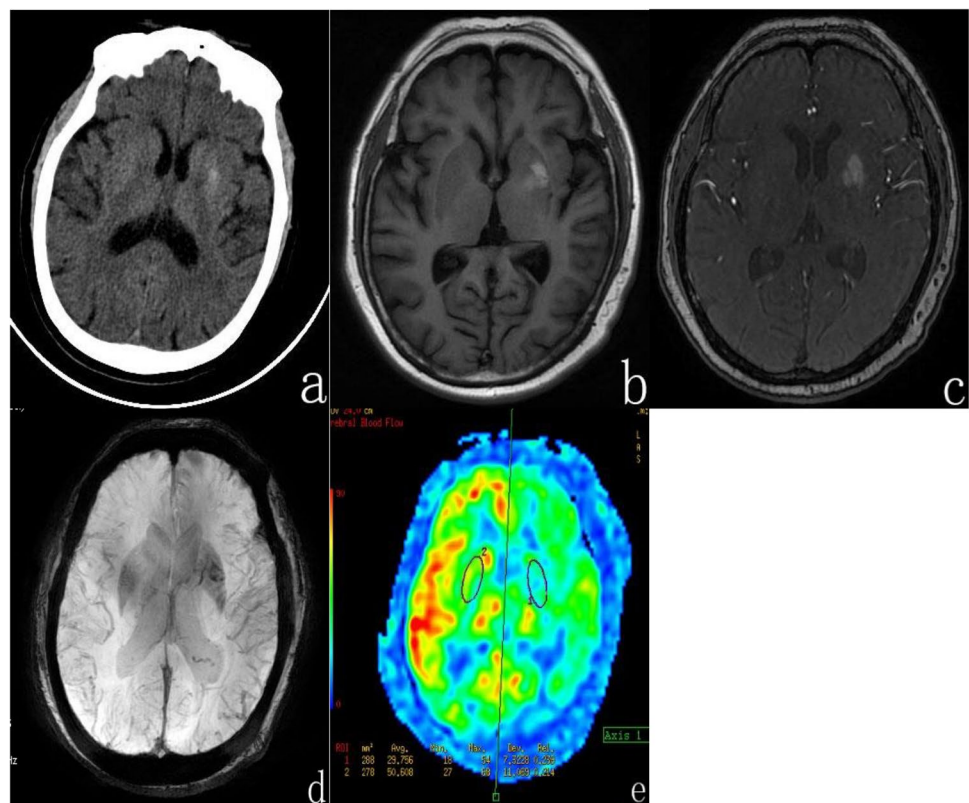
diffusion-weighted imaging (DWI), and the ADC value of the abnormal lesion center was  $0.641 \times 10^{-3} \text{ mm}^2/\text{s}$ . Moreover, it also revealed isointensity with punctate hypointensity on SWI in the bilateral basal ganglia (Fig. 1b–g). Based on the above presentation, a diagnosis of diabetic striatopathy associated with ketotic hyperglycemia was made. On the 6th day, the patient's condition improved, blood pressure and blood glucose were well controlled, muscle strength of the limbs was back to normal, and consciousness was clear. The patient has completely recovered from hemichorea.

## Case 2

A 74-year-old woman presented to us with a 5-day history of involuntary movements, which were characterized by involuntary, brief, irregular dancing of the right limb without obvious inducement. The patient had been diagnosed with type 2 diabetes mellitus 12 years ago. After the diagnosis, insulin injection and oral hypoglycemic agents were used for hypoglycemic treatment. The patient stopped taking oral hypoglycemic agents and monitored blood glucose irregularly. Records revealed that fasting blood glucose was about 11–14 mmol/L; 2 h postprandial blood glucose was as high as 19 mmol/L. She also suffered from blurred vision in the right eye. She did not complain about any

other symptoms such as obvious hand and foot numbness, intermittent claudication, and foam urine. The patient also has a history of coronary heart disease and cerebral infarction for over 10 years. On laboratory examinations at admission, blood glucose was 15.93 mmol/L, HbA1c 10.40%, urine glucose (+++), and urinary ketone bodies (-). The unenhanced axial CT images showed hyperdensity in the left lentiform nucleus with a CT value of about 43 Hu (Fig. 2a). Brain MRI showed hyperintensity on T1-weighted images (Fig. 2b), hypointensity on T2-weighted images, T2-FLAIR images, and DWI scans. MRA source images (Fig. 2c) also revealed hyperintensity in the left lentiform nucleus as compared to the right. SWI showed isointensity in bilateral basal ganglia with punctate hypointensity in the left basal ganglia; ASL showed hypoperfusion in the left basal ganglia (Fig. 2d,e). On the third day of admission, urine biochemical examination of urine microalbuminuria/creatinine was 300.70 mg/g, and urine microalbumin 21.77 mg/L, suggesting diabetic nephropathy. CT examination suggested a high-density shadow in the left basal ganglia area, with a CT value of about 40–45HU. The patient received active hypoglycemic treatment, lipid-lowering and platelet control treatment, and symptomatic treatment such as nourishing nerves and improving sleep. After 10 days, the patient's blood glucose was well controlled and her condition gradually improved.

**Fig. 2** Imaging examinations of case 2. Computed tomography (CT) of the brain on October 08, 2021 (a) and magnetic resonance imaging (MRI) of the brain on October 05, 2021 (b,c), and October 10, 2021 (d, e). (a) The unenhanced axial CT images showed hyperdensity in the left lentiform nucleus, and the CT values was about 43 Hu. (b) The left lentiform nucleus showed hyperintensity on T1-weighted images. (c) The left lentiform nucleus indicated hyperintensity on MRA source images. (d) SWI demonstrated isointensity in bilateral basal ganglia with punctate hypointensity in the left basal ganglia. (e) Magnetic resonance arterial spin labeling(ASL) showed hypoperfusion in the left basal ganglia with the CBF value of 29.456 mL/(100 g × min), while the CBF values of contralateral region was 50.608 mL/(100 g × min)





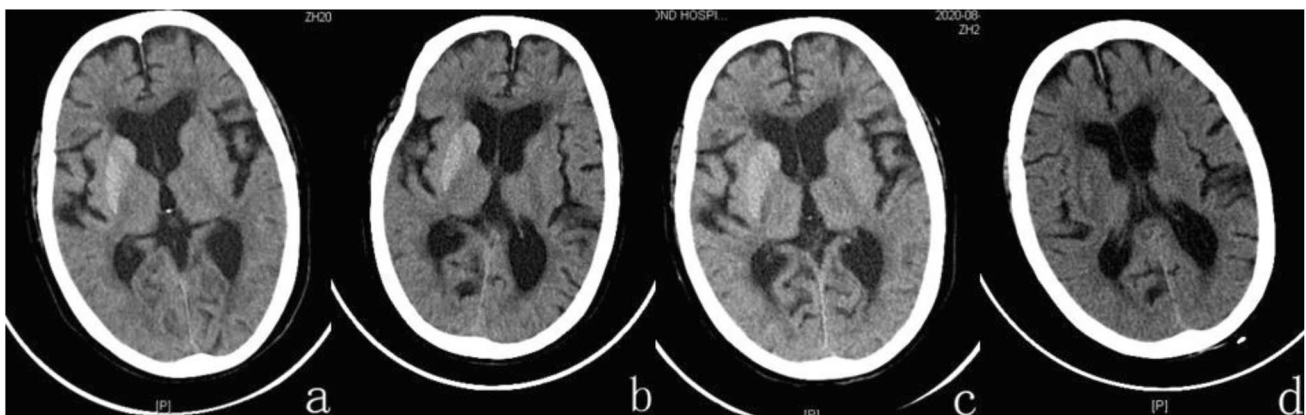
### Case 3

A 76-year-old female presented with symptoms of salivation, left-sided limb weakness, accompanied by the tightly closed left eye 5 days before, but had no obvious cause. She also complained about discomfort in the left head and neck, verbal reduction, and decreased left limb movement with intermittent episodes of about 20 min, which could improve spontaneously in a few minutes without any treatments, no limb twitching, no impaired consciousness, no panic, chest tightness, or chest pain, and still left-sided limb weakness after the episodes. The patient had a history of coronary artery disease, pulmonary embolism, hypertension, and ulcerative colitis; she was also allergic to penicillin. Laboratory examinations showed that random blood glucose was 17.55 mmol/L, HbA1c 20.10%, blood sodium 129 mmol/L, blood chloride 94 mmol/L, and D-dimer 2.34 mg/L. MRI was not performed on this patient due to the history of coronary stenting. The right caudate and lentiform nucleus showed hyperdensity with a CT value of about 59 Hu on the CT scan (Fig. 3a). Combined with the brain CT examination, high blood glucose and symptoms of paroxysmal dystonia, the patient was considered to have a high possibility of DS. During hospitalization, the patient developed left-sided orofacial and eyelid spasms and recurrent fever. She was treated with insulin intravenous hypoglycemic therapy, and rehydration support therapy to correct hyponatremia and hypochloremia with symptomatic treatment including antibiotics, diazepam, phenobarbital, and sodium valproate. During hospitalization, two-repeat cranial CT examinations showed a gradually decreased hyperdensity in the right caudate and lentiform nucleus (Fig. 3b,c), with a CT value of approximately 33 Hu in the right basal ganglia region at discharge (Fig. 3d). The patient's condition improved at the

time of discharge, with significant recovery of speech and limb function, more flexible movement of the left upper limb, and better muscle strength in all limbs.

### Case 4

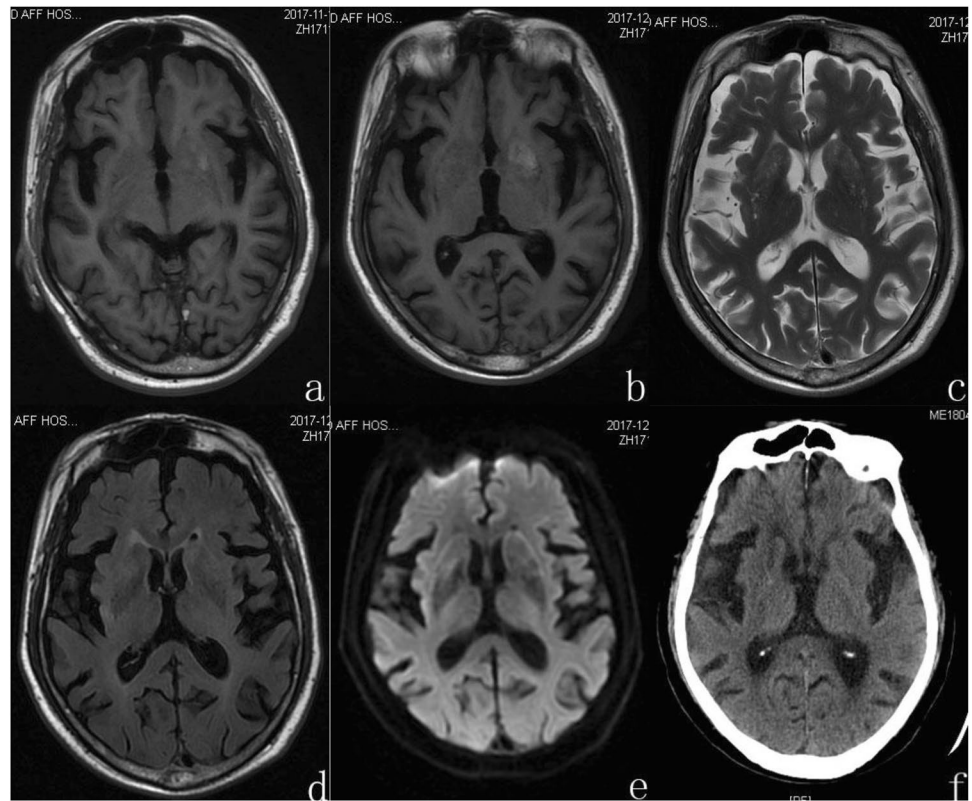
An 80-year-old male presented due to sudden unconsciousness with the right limb convulsions and fever. The abnormal movement involved both upper- and lower-limbs and were continuous. CT examination showed isodensity in the left caudate and lentiform nucleus and the CT value was about 33 Hu. T1-weighted images (Fig. 4a) demonstrated a region of hyperintensity in the left caudate and lentiform nucleus, which was slightly hyperintensity on DWI images, and the ADC value of the abnormal lesion center was  $0.739 \times 10^{-3} \text{mm}^2/\text{s}$ . Chest CT suggested pneumonia and the number of cells in cerebrospinal fluid was normal. After the patient was diagnosed with viral encephalitis, status epilepticus, and pneumonia, he received antiviral, anti-infection, and anti-epilepsy treatment. He developed series of symptoms, such as paroxysmal involuntary movement of the right limb and labial twitch, within 18 days of discharge. Cerebrospinal fluid examination showed anti-leucine-rich glioma-inactivated 1 (LGI1) IgG positive; Pandy test was weakly positive; acid-fast stain, ink dyeing, and fungal culture were negative. Autoantibodies such as anti-SSA, anti-SSB antibodies, and anti-Sm antibodies were negative. Erythrocyte sedimentation rate (ESR), thyroid function, liver and kidney function, and tumor markers were normal. Random blood glucose was 9.7 mmol/L, HbA1c 9.0%, urine glucose (+ +), and urinary ketone body (-), considered as convulsion caused by anti LGI1 autoimmune encephalitis initially. MRI showed that the left caudate and lentiform nucleus showed hyperintensity on T1-weighted images, but the range was extended



**Fig. 3** Fig. 3. Imaging examinations of case 3. Computed tomography (CT) of the brain on August 13, 14 and 20, 2020 (a–c) and September 05, 2020 (d). (a–c) The unenhanced axial CT revealed hyperdensity in the right caudate and lentiform nucleus, and the CT value of the

abnormal lesion center was about 59Hu, 54Hu, 51Hu. (d) The disappearance of the hyperdensity the right caudate and lentiform nucleus on CT scans, and the CT value of the abnormal lesion center was about 33 Hu

**Fig. 4** Imaging examinations of case 4. Magnetic resonance imaging (MRI) of the brain on November 14, 2017 (a) and December 01, 2017 (b–e), and computed tomography (CT) of the brain on April 01, 2018 (f). (a) The left caudate and lentiform nucleus showed hyperintensity on T1-weighted images on November 14, 2017. (b) The left caudate and lentiform nucleus showed hyperintensity on T1-weighted images on December 01, 2017, but the range was extended. (c–e) The left caudate and lentiform nucleus showed isointensity on T2-weighted images, slightly hyperintensity on T2-FLAIR images, slightly hyperintensity on DWI images. (f) The unenhanced axial CT images showed isodensity in the left caudate and lentiform nucleus with the CT value of about 30 Hu



than before, isointensity on T2-weighted images, slightly hyperintensity on T2-FLAIR images, slightly hyperintensity on DWI images with the ADC value of the abnormal lesion center of  $0.667 \times 10^{-3} \text{ mm}^2/\text{s}$  (Fig. 4b–e), and hyperintensity on MRA source images. The patient was managed with phenytoin sodium, insulin, and antibiotic, then his blood glucose level remained normal and the hemichorea was controlled. Repeated CT showed isodensity in the left caudate and lentiform nucleus with a CT value of about 30 Hu (Fig. 4f). His clinical manifestations, laboratory examination results, and imaging changes strongly suggested DS, but other causes of chorea such as autoimmune encephalitis could not be ruled out.

### Case 5

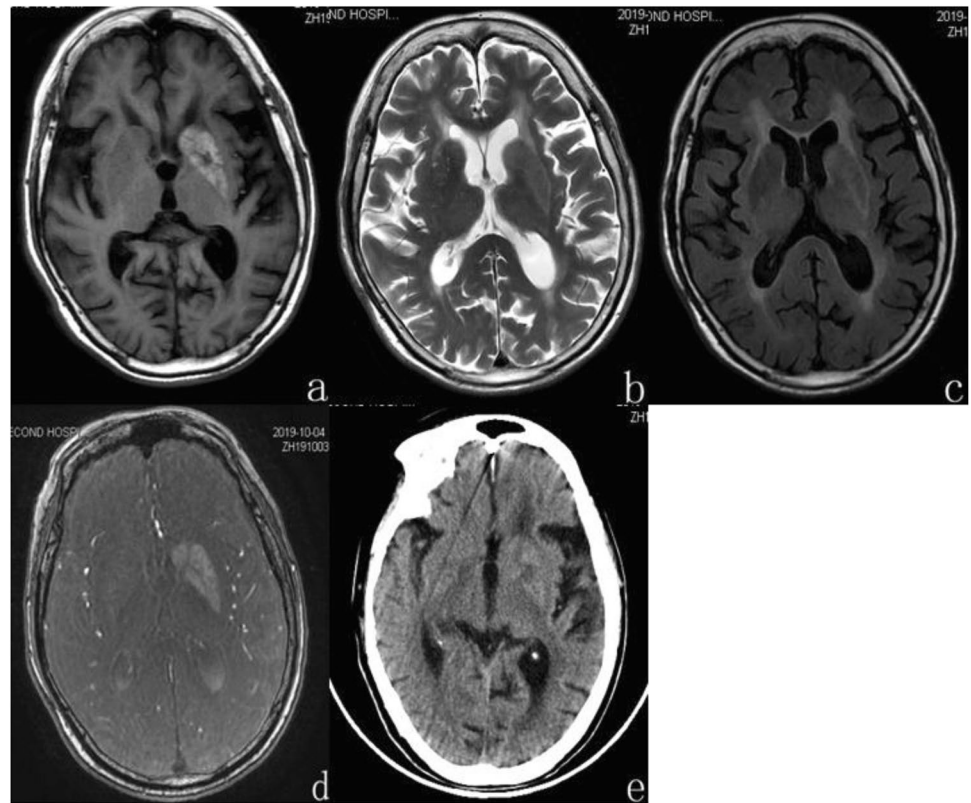
A 90-year-old woman with 30-year history of type 2 diabetes mellitus admitted to the hospital due to paroxysmal involuntary choreic movements of her right upper limb without obvious inducement 2 months ago, accompanied by involuntary shaking of the right eye and right corner of the mouth. Involuntary movements occurred intermittently and occasionally at first, then the frequency increased gradually, and worsened when emotional tension occurs. There was no additional extrapyramidal sign, especially no rigidity or bradykinesia. The patient had a 40-year history of hypertension, treated with reserpine, and a 30-year history

of coronary heart disease, untreated. Laboratory examination the next day revealed that fasting blood glucose was 8.39 mmol/L, HbA1c 9.9%, urine glucose (+ +), no abnormality in other biochemical examinations. Brain MRI demonstrated that the left caudate and lentiform nucleus showed hyperintensity on T1-weighted images (Fig. 5a), hypointensity on T2-weighted images, slightly hyperintensity on T2-FLAIR images, and hyperintensity on MRA source images (Fig. 5b–d). There was no obvious diffusion limitation on diffusion-weighted imaging (DWI), and the ADC value of the abnormal lesion center was  $0.994 \times 10^{-3} \text{ mm}^2/\text{s}$ . The patient underwent dietary restrictions to treat diabetes, added hypoglycemic drugs if necessary, combined with antihypertensive and lipid-lowering therapy. The involuntary movement of her right upper limb reduced significantly after these treatments. On the third day of admission, cranial CT showed slightly hyperdensity in the left caudate and lentiform nucleus with a CT value of about 37 Hu (Fig. 5e). On the sixth day of admission, the patient's involuntary facial twitch was completely mitigated and the symptoms of the right limb were significantly relieved.

### Case 6

A 73-year-old woman with a history of type 2 diabetes mellitus for 7–8 years and hypertension for 10 years was hospitalized with right hemiballism for 10 days and had no limb weakness,

**Fig. 5** Imaging examinations of case 5. Magnetic resonance imaging (MRI) of the brain on October 4, 2019 (a–d) and computed tomography (CT) of the brain on October 5, 2019 (e). (a) The left caudate and lentiform nucleus showed hyperintensity on T1-weighted images. (b–d) The left caudate and lentiform nucleus showed hypointensity on T2-weighted images, slightly hyperintensity on T2-FLAIR images, hyperintensity on MRA source images. (e) The unenhanced axial CT images showed slightly hyperdensity in the left caudate and lentiform nucleus with the CT value of about 37Hu



facial spasm, nystagmus, or other cerebellar signs. Neurological examination was normal except for the abnormal movements. Brain MRI showed hyperintensity on T1-weighted images, hypointensity on T2-weighted images, T2-FLAIR (Fig. 6a–c), and DWI scans in the left caudate and lentiform nucleus. Brain CT showed hyperdensity in the left caudate and lentiform nucleus (Fig. 6d). Chest CT showed pulmonary inflammation. Laboratory examination on the next day showed that blood glucose was 15.02 mmol/L, HbA1c 10.70%, urine glucose (++) . Combined with the medical history, clinical manifestations, and auxiliary examination results, intracranial hemorrhage was tentatively diagnosed. After 5 days of antihypertensive and hypoglycemic treatments, the involuntary movements of the patient's right limb were significantly relieved. Excluding acute intracerebral hemorrhage, combined with clinical and radiographic findings, the patient was diagnosed with DS finally. At the time of discharge, the patient's choreic movements and the symptoms of the lungs were significantly improved. CT reexamination showed that the density and range of lesions in the left basal ganglia decreased (Fig. 6e).

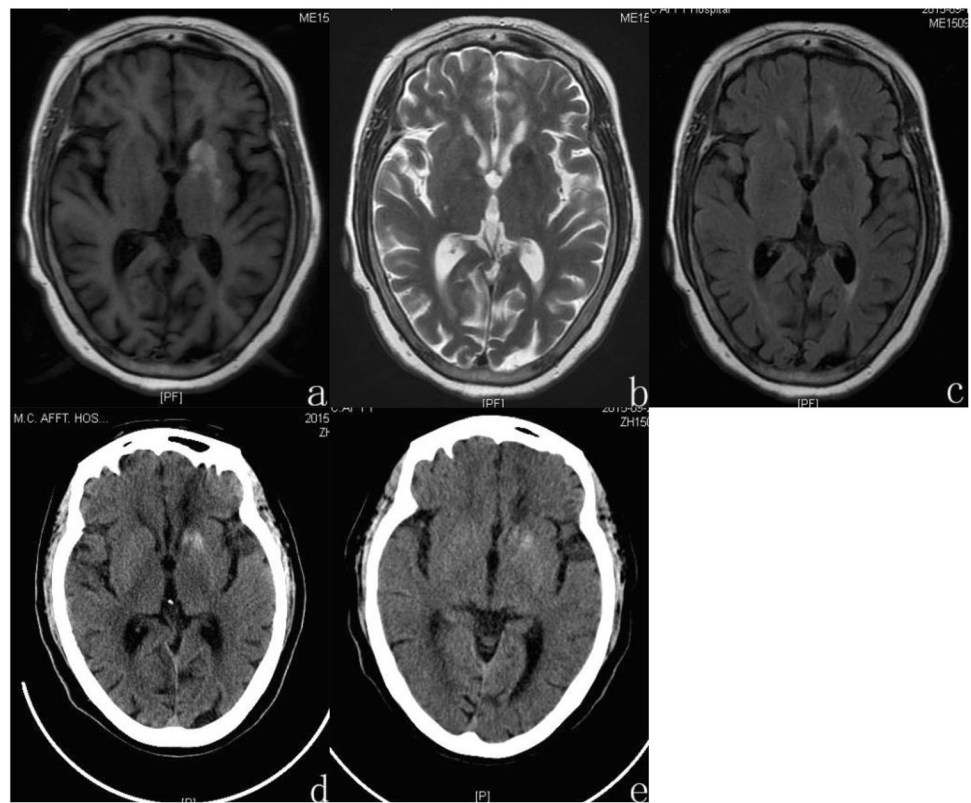
## Discussion

Neurological complications of diabetes mellitus mainly include stroke, peripheral neuropathy, and seizures [4]. Studies have shown that DS occurs mostly in elderly Asian

women with type 2 diabetes mellitus who have poor glycaemic control and are rare in type 1 diabetes mellitus and DKA [3, 5–13], and even rarer in type 3C diabetes [14]. According to a meta-analysis, the mean age of DS patients was 71 years [15], and in the present cases, one male and five female; the mean age of the six patients were  $77.5 \pm 6.75$  years (72–90 years), which was generally consistent with previous reports [15]. All six patients had type 2 diabetes mellitus and all presented with elevated blood glucose (8.39–24.0 mmol/L) and HbA1c (9.0–20.40%) on admission, which was generally consistent with reports (Table 1) [3]. Non-ketotic hyperglycemia, unilateral limb choreographic dyskinesia, and striatal abnormalities on neuroimaging are typical signs of DS. Previous studies have found that chorea associated with hyperglycemia occurs mostly unilaterally and rarely bilaterally; a few may occur in hypoglycemic states or after correction of hyperglycemia [1, 16–18], and a few DS cases reported no chorea [18–20] or had nonchoreic and nonballistic movements [7, 12, 14, 18, 21, 22]. The imaging manifestation may also be unremarkable [16, 18, 23]. Dubey et al. [18] studied 59 diabetic patients with acute dyskinesia and found that 44.1% of the patients had abnormal striatal signals, while the majority of the patients (55.9%) did not have abnormal striatal signals, and the proportion of male patients in this study was higher (52.5%), which was different from previous studies. In this study, 41 (69.5%)



**Fig. 6** Imaging examinations of case 6. Magnetic resonance imaging (MRI) of the brain on September 19, 2015 and computed tomography (CT) of the brain on September 19, 2015 and September 28, 2015. **(a–c)** The left caudate and lentiform nucleus showed hyperintensity on T1-weighted images, hypointensity on T2-weighted images, hypointensity on T2-FLAIR images. **(d)** The left caudate and lentiform nucleus revealed hyperdensity on CT scan. **(e)** CT reexamination showed the density and range of lesions in the left basal ganglia decreased



had choreic or ballistic movements and 18 (30.5%) had nonchoreic or nonballistic movements; the latter include myoclonus, dystonia, facial spasm, restless leg syndrome, tremors, and Parkinsonism. As the number of reports about DS increases, so does the number of manifestations of DS [12]. Due to the relative rarity of DS, it is highly susceptible to misdiagnosis or missed diagnosis, especially when the clinical and imaging manifestations are atypical, and the actual incidence may be higher than 0.0001% [3]. Ketotic hyperglycaemic hemichorea is a very rare complication, mostly diagnosed in young type 1 diabetic patients [9, 12], but there are still fewer reports about DS in elderly type 2 diabetic patients; in the present study, patient 1 is an elderly female with type 2 diabetes mellitus, and there are only three previous reports involving fore cases of type 2 diabetes mellitus in the elderly [9, 13, 24].

The pathophysiological basis of DS is unclear. Chorea can also occur after hypoglycemia or blood glucose correction, which suggests that long-term hyperglycemia may cause pathological changes in the striatum. However, the development of dance symptoms cannot be determined whether they are related to acute or chronic injury [25]. Hyperglycemia causes metabolic disorder [26], destroys the blood–brain barrier, leads to the insufficient blood supply, acidosis, and brain edema in the basal ganglia, and then metabolic disorder in the basal ganglia, resulting in dance symptoms.

At present, several hypotheses have been proposed at home and abroad to elucidate the pathogenesis of DS. (1) Microvascular disease theory. Yoshinori et al. [27] found obvious patchy necrosis and edema, reactive astrocytosis, and small vessel disease with macrophage, lymphocyte infiltration, and erythrocyte extravasation in the affected basal ganglia through biopsy. Among them, small vessel disease was characterized by obliteration of small artery lumen, strikingly thickening of all three layers of the wall, hyaline change, and remarkable proliferation of small blood vessels, which were similar to diabetic retinopathy. In this study, patient 2 had diabetic retinopathy and diabetic nephropathy, combined with previous studies [18, 28], showed that there was correlation between striatal lesions and microangiopathy. (2) Infection and autoimmune inflammatory response theory. Battisti and Wang [29, 30] found that autoimmune inflammatory reaction was involved in DS in some cases. Such patients had a history of respiratory or urinary system infection before illness, and IgG level was increased in cerebrospinal fluid. In addition, studies found that there was a small amount of lymphocytic infiltration around the blood vessels of the lesions in the basal ganglia [27]. All these indicate that inflammatory lesions caused by central nervous system infection may be involved in the pathogenesis. Ghosh et al. [10] reported a case of new-onset diabetes with COVID-19 infection and chorea in a patient who was found to be positive for urinary ketone

**Table 1** Demographic data of six patients

Patient	Sex/age	blood glucose mmol/L	HbA1c%	Glu	Urinary ketone	Side affected	Location	CT value(Hu)	T1WI	T2WI	T2-FLAIR	ADC (affected side/contralat- eral) × 10 <sup>-3</sup> mm <sup>2</sup> /S	MRA source images
1	F/72	24.0	20.07	++	++	R	CN+GP+P	56	Hyperinten- sity	Hypointen- sity	Hypointen- sity	0.641/0.780	Hyperintensity
2	F/74	15.93	10.40	4+	-	L	GP+P	43	Hyperinten- sity	Hypointen- sity	Hypointen- sity	0.697/0.742	Hyperintensity
3	F/76	17.55	20.10	++	-	R	CN+GP+P	59	-	-	-	-	-
4	M/80	9.70	9.0	++	-	L	CN+GP+P	33	Hyperinten- sity	Isointensity	Slightly hyperinten- sity	0.739/0.812	Hyperintensity
5	F/90	8.39	9.90	++	-	L	CN+GP+P	37	Hyperinten- sity	Hypointen- sity	Slightly hyperinten- sity	0.994/0.813	Hyperintensity
6	F/73	15.02	10.70	++	-	L	CN+GP+P	42	Hyperinten- sity	Hypointen- sity	Hypointen- sity	0.675/0.719	Hyperintensity

*Abbreviation:* F, female; M, male; CN, caudate nucleus; GP, globus pallidus; P, putamen; L, left; R, right

and associated with acidosis after admission to hospital; MRI T1WI showed typical hyperintensity in the contralateral striatum, and the final diagnosis was DS. Firstly, SARS-CoV-2 infection can cause transient or permanent hyperglycemia in people with previously normal blood glucose levels through a variety of mechanisms. In addition, SARS-CoV-2 infection can induce DKA and damage striatum by interfering with cell metabolism and inducing immune cell aggregation. In the end, SARS-CoV-2 infection and DKA can cooperate to cause dancing symptoms. Infection can not only affect blood glucose metabolism, but also promote the emergence of chorea. This case also suggests that DS induced by DKA may be the result of multiple mechanisms. The cerebrospinal fluid examination of patient 4 showed that LGII IgG was positive and Pandy test was weakly positive, which was considered to be convulsion caused by anti LGII autoimmune encephalitis. In addition, in this group of cases, 3 patients were accompanied by pulmonary infection at admission. Combined with previous studies, the role of inflammation in the pathogenesis of DS cannot be ruled out. (3) Ischemic injury theory. In the present study, ASL scan of patient 2 showed hypoperfusion in the left striatum. Some scholars performed SPECT examination on patients with DS [17], and the results showed that the lesions were ischemic, and the above supported the ischemic injury theory.

The DS imaging presentations were characteristic, i.e., T1WI hyperintensity and CT hyperdensity focus in the contralateral basal ganglia of the affected limb at the early onset, and T2WI and DWI signals are not characteristic and can be hyper-, iso-, hypo-, or mixed intensity. With the effective control of hyperglycemia, the lesions can be gradually absorbed and dissipated [29, 31], and such reversible imaging changes have not been seen in other metabolic or structural lesions in the basal ganglia region. The pathophysiological basis for the imaging manifestations of DS has not been conclusively established, and various hypotheses such as speckled hemorrhages, ischemic lesions, glial cell proliferation, reversible calcium salts deposition, and Wallerian degeneration have been proposed [32]. The ranges of abnormalities on CT and MRI in each of the five patients in present study were not identical, indicating that CT hyperdensity and T1WI hyperintensity may be caused by different pathophysiological mechanisms, suggesting that DS is unlikely to be due to a single cause. It has been suggested that the persistent hyperglycemic state leads to the dysfunction of blood–brain barrier, and leakage of red blood cells from the capillaries in the deep gray matter, forming speckled hemorrhages [30]. The CT examination of our 6 patients all showed hyperdensity in the affected area with CT value of 33–59Hu, and the SWI examination of patient 2 showed patchy low signal of lentiform nucleus, and the MRA source images showed hyperintensity of basal ganglia in 5 patients, and it was consistent with the range of hyperintensity on



T1WI. According to the changes of MRI in different periods of cerebral hemorrhage, all patients showed hyperintense on T1WI and variable signal in T2WI, which indicated that the hemorrhage was in subacute stage and deoxyhemoglobin was transformed into methemoglobin; the latter was a paramagnetic substance, which made T1WI significantly high signal. The imaging features of the present patients were consistent with the autopsy findings of Yoshinori, Mestre, et al. [27, 33], supporting the hemorrhage hypothesis. The hemorrhage was limited to caudate and lentiform nucleus, and did not involve the internal capsule, and there was no edema or occupying effect, unlike conventional intracerebral hemorrhage. DW-MRI is sensitive to changes in the diffusion of water molecules. ADC maps indicated that the diffusion of molecules is restricted by structures such as cell membranes, and reflected the microstructure of the cellular environment. The ADC values of the abnormal lesion centers gradually increased with glycemic control and improvement of clinical symptoms, which was consistent with the view of some scholars that the apparent diffusion coefficient (ADC) of DWI can be used to determine the area of involvement and prognosis of DS patients [32, 34]. Shan et al. [35] biopsied lesions in the basal ganglia region of DS patients and found obese astrocyte aggregates. It was suggested that the ADC values of the lesions were lower than those of the contralateral side due to obese astrocyte aggregates and cytotoxic edema caused by abnormal oxygen metabolism in the basal ganglia area in the early stage of the disease, while their intracytoplasmic protein hydration layer caused T1WI high signal changes, while the ADC values of the affected side gradually increased with the absorption of the lesions and increased local water molecular activity.

MRI and CT are the most common imaging tests for DS, but they have different sensitivities to DS. Chua et al. [3] compared the brain MRI and CT findings of 176 patients with DS, and found that the sensitivity of the two was 95.33% and 78.86%, respectively. In addition, MRI is more accurate than CT in detecting the changes of lesions in DS patients. In this study, the brain MRI and CT examination of the patients at the same period showed the same lesion location, but in terms of scope, the MRI showed a relatively larger range, and it was easier to show a clear edge. The above shows that MRI has more advantages than CT in detecting DS [3, 18].

The clinical manifestations of some patients were not consistent with the imaging findings, for example, bilateral involuntary movement with unilateral striatum lesions or unilateral involuntary movement with bilateral striatum lesions or unilateral involuntary movement with ipsilateral striatum disease; the mechanism of this condition is not clear [25]. Some patients had no lesions in the striatum, and a study using MRS in patients with DS showed a lower NAA/CR ratio in the diseased striatum, indicating neuronal loss or

damage [25]. Despite its normal MRI appearance, its function was impaired [25], which may be one of the reasons why there is no obvious correlation between the differences in imaging findings and the severity and duration of chorea in DS patients. Although DS is a reversible disease, in the study of Ghosh et al. [21], the striatum on the affected side was atrophied without abnormal signal, which indicates the diversity of imaging findings of DS; it is suggested that striatal atrophy may be the final trend of imaging abnormalities in DS, especially those without active treatment [36].

There were several limitations to the present study. First, the number of cases was relatively small. Second, combined with clinical manifestations and imaging examinations, we cannot rule out the possibility of other diseases, or dance symptoms were the result of DS and other factors, especially when dance symptoms are not completely resolved after glycemic correction; other disease-related effects cannot be ruled out [6, 11, 25]. For example, case 4 was accompanied by epilepsy, and anti-LGI1 encephalitis cannot be ruled out. In addition, most patients were not followed up in time after discharge; it is impossible to know the recovery degree and duration of the disease and final evolution of imaging performance.

## Conclusion

DS has a good prognosis, and chorea symptoms can be relieved by controlling blood glucose at the beginning of the disease course, and dopamine receptor antagonists can be added in severe patients. In recent years, there are more and more atypical cases of DS, which make the differential diagnosis more difficult. After controlling the blood glucose, the clinical symptoms are relieved or disappeared. The above indicates the importance of rapid blood glucose measurement in patients with acute to subacute paroxysmal dyskinesia, regardless of their past blood glucose status; it is of great significance to detect blood glucose in time for early detection, treatment, and differential diagnosis of the disease. Timely brain imaging examination and active control of blood sugar can avoid misdiagnosis and delayed treatment.

**Author contribution** YX put together the material of the cases and wrote the first draft of the manuscript, and analyzed the data; QS supplied the CT and the MRI image information and was responsible for revising the manuscript; YY participated in writing of the manuscript and supervised the reporting process of the case; CY designed the study and finalized the manuscript, resources, and project administration. All authors revised and approved the final manuscript.

**Funding** This work was supported by the Science and Technology Innovative Development Foundation of Taian (2020NS249).

**Data availability** The processed data required to reproduce, and these findings cannot be shared at this time as the data also forms part of an ongoing study.

## Declarations

**Ethical approval** All procedures performed in studies involving human participants were in accordance with the ethical standards of the institutional and/or national research committee and with the 1964 Helsinki Declaration and its later amendments or comparable ethical standards.

**Consent to participate** Informed consent was obtained from all individual participants included in the study. The patient did not have any discomfort during the examination.

**Consent for publication** Written informed consent was obtained from the individual's legal guardian/next of kin for the publication of any potentially identifiable images or data included in this article.

**Conflict of interest** The authors declare no competing interests.

## References

- Lin CJ, Huang P (2017) Delayed onset diabetic striatopathy: hemichorea-hemiballism one month after a hyperglycemic episode. *Am J Emerg Med* 35(7):1036.e3–1036.e4. <https://doi.org/10.1016/j.ajem.2017.02.018>
- Maia M, Moreira AP, Gonçalves AI, Espírito Santo J, Araújo J (2021) Hemichorea-hemiballism as a manifestation of hyperglycemia. *Cureus* 13(11):e19330–e19330. <https://doi.org/10.7759/cureus.19330>
- Chua CB, Sun CK, Hsu CW, Tai YC, Liang CY, Tsai IT (2020) “Diabetic striatopathy”: clinical presentations, controversy, pathogenesis, treatments, and outcomes. *Sci Rep* 10(1):1594. <https://doi.org/10.1038/s41598-020-58555-w>
- Wang W, Tang X, Feng H, Sun F, Liu L, Rajah GB, Yu F (2020) Clinical manifestation of non-ketotic hyperglycemia chorea: a case report and literature review. *Medicine (Baltimore)* 99(22):e19801. <https://doi.org/10.1097/MD.00000000000019801>
- Faundez T, Klee P, Hanquinet S, Schwitzgebel V, Burkhard PR, Korff CM (2016) Diabetic striatopathy in childhood: a case report. *Pediatrics* 137(4):e20143761–e20143761. <https://doi.org/10.1542/peds.2014-3761>
- Lin JB, Sng AA, Wang FS, Tan AP, Han VX (2020) Acute hemichorea in a young type 1 diabetic. *Int J Neurosci* 130(7):743–745. <https://doi.org/10.1080/00207454.2019.1702540>
- Safan AS, Sharma O, Almasri M, D'Souza AI, Suliman O (2022) Is diabetic striatopathy the culprit of seizures in a patient with ketotic hyperglycemia-induced hemichorea-hemiballismus? *BMC Neurol* 22(1):133–133. <https://doi.org/10.1186/s12883-022-02659-5>
- Mikulenka P, Stetkarova I (2020) Hemichorea in ketotic hyperglycemia with hyperdense striatum mimicking hemorrhagic transformation in a patient using apixaban. *Neuro Endocrinol Lett* 41(4):162–165
- Das L, Pal R, Dutta P, Bhansali A (2017) “Diabetic striatopathy” and ketoacidosis: report of two cases and review of literature. *Diabetes Res Clin Pract* 128:1–5. <https://doi.org/10.1016/j.diabres.2017.03.008>
- Ghosh R, Dubey S, Roy D, Ray A, Pandit A, Ray BK, Benito-León J (2021) Choreo-ballistic movements heralding COVID-19 induced diabetic ketoacidosis. *Diabetes Metab Syndr* 15(3):913–917. <https://doi.org/10.1016/j.dsx.2021.04.010>
- Hashimoto K, Ito Y, Tanahashi H, Hayashi M, Yamakita N, Yasuda K (2012) Hyperglycemic chorea-ballism or acute exacerbation of Huntington's chorea? Huntington's disease unmasked by diabetic ketoacidosis in type 1 diabetes mellitus. *J Clin Endocrinol Metab* 97(9):3016–3020. <https://doi.org/10.1210/jc.2012-1190>
- Chatterjee S, Ghosh R, Kumari R, Ojha UK, Benito-León J, Dubey S (2021) Faciobrachial myoclonus as the presenting manifestation of diabetic keto-acidosis. *Tremor and Other Hyperkinetic Movements* 11(1):1–5. <https://doi.org/10.5334/tohm.605>
- Yassin AM, Shroff S, Patel SD, Paker AM, Berman MA, Jackson GR (2014) Hemichorea in a patient with diabetic ketoacidosis. *J Neurol Sci* 342(1–2):189–191. <https://doi.org/10.1016/j.jns.2014.04.038>
- Ghosh R, Roy D, Chatterjee S, Dubey S, Swaika BC, Mandal A, Benito-León J (2021) Hemifacial spasm as the presenting manifestation of type 3c diabetes mellitus. *Tremor Other Hyperkinet Mov (N Y)* 26(11):14. <https://doi.org/10.5334/tohm.611>
- Oh SH, Lee KY, Im JH, Lee MS (2002) Chorea associated with non-ketotic hyperglycemia and hyperintensity basal ganglia lesion on T1-weighted brain MRI study: a meta-analysis of 53 cases including four present cases. *J Neurol Sci* 200(1–2):57–62. [https://doi.org/10.1016/s0022-510x\(02\)00133-8](https://doi.org/10.1016/s0022-510x(02)00133-8)
- Matsushima E, Shiota H, Watanabe K, Otsuka Y, Yamana M, Yamaguchi S, Egashira F, Kamei S, Ishihara H (2019) Hemichorea after hypoglycemic episodes with negative MRI findings in an elderly woman with poorly controlled type 2 diabetes mellitus: a case report. *BMC Neurol* 19(1):131. <https://doi.org/10.1186/s12883-019-1334-2>
- Cho HS, Hong CT, Chan L (2018) Hemichorea after hyperglycemia correction: a case report and a short review of hyperglycemia-related hemichorea at the euglycemic state. *Medicine (Baltimore)* 97(10):e0076. <https://doi.org/10.1097/MD.00000000000010076>
- Dubey S, Chatterjee S, Ghosh R, Louis ED, Hazra A, Sengupta S, Das S, Banerjee A, Pandit A, Ray BK, Benito-León J (2022) Acute onset movement disorders in diabetes mellitus: a clinical series of 59 patients. *Eur J Neurol* 29(8):2241–2248
- Chua CB, Chen HC, Su HY, Tsai IT, Sun CK (2019) Images of the month 1: diabetic striatopathy without hemichorea/hemiballism. *Clin Med (Lond)* 19(5):412–413. <https://doi.org/10.7861/clinmed.2019-0129>
- Sato H, Hamano M, Fushimi E, Takahashi T, Horikawa Y, Horiguchi S (2017) Diabetic striatopathy manifesting as severe consciousness disturbance with no involuntary movements. *Diabet Med* 34(12):1795–1799. <https://doi.org/10.1111/dme.13526>
- Chatterjee S, Ghosh R, Ojha UK, Diksha BP, Benito-León J, Dubey S (2021) Recurrent facial focal seizures with chronic striatopathy and caudate atrophy—a double whammy in an elderly woman with diabetes mellitus. *Neurohospitalist* 12(1):147–150. <https://doi.org/10.1177/19418744211035370>
- Ghosh R, Roy D, Das S (2022) Benito-León J (2022) Hemifacial spasm followed by predominantly unilateral upper limb monochorea unmasking type-2 diabetes mellitus. *Neurologia* 37(3):239–242. <https://doi.org/10.1016/j.nrleng.2021.12.004>
- Chang X, Hong W, Yu H, Yao Y (2017) Chorea associated with nonketotic hyperglycemia: a case report with atypical imaging changes. *Medicine (Baltimore)* 96(45):e8602. <https://doi.org/10.1097/MD.00000000000008602>
- Xu J, Xu CL, Ma YG, Dong QL (2021) Ketotic hemichorea: a report of two cases and literature review. *Chin J Neurol* 54:822–825. <https://doi.org/10.3760/cma.j.cn113694-20201130-00929>
- Dubey S, Biswas P, Ghosh R, Chatterjee S, Ray BK, Benito-León J (2022) Neuroimaging of diabetic striatopathy: more questions than answers. *Eur Neurol*. <https://doi.org/10.1159/000524936>

26. Kumar Vadi S, Mehta S, Kumar R, Tandyala N, Singh H, Mittal BR (2020) Severe contralateral striatal hypometabolism in a case of diabetic nonketotic hyperglycemic hemichorea on 18F-FDG PET/CT brain. *Clin Nucl Med* 45(2):e117–e119. <https://doi.org/10.1097/RLU.0000000000002844>
27. Abe Y, Yamamoto T, Soeda T, Kumagai T, Tanno Y, Kubo J, Ishihara T, Katayama S (2009) Diabetic striatal disease: clinical presentation, neuroimaging, and pathology. *Intern Med* 48(13):1135–1141. <https://doi.org/10.2169/internalmedicine.48.1996>
28. Lizarraga KJ, Chunga N, Yannuzzi NA, Flynn HW Jr, Singer C, Lang AE (2020) The retina as a window to the basal ganglia: systematic review of the potential link between retinopathy and hyperkinetic disorders in diabetes. *Parkinsonism Relat Disord* 80:194–198. <https://doi.org/10.1016/j.parkreldis.2020.10.025>
29. Battisti C, Forte F, Rubenni E, Dotti MT, Bartali A, Gennari P, Federico A, Cerase A (2009) Two cases of hemichorea-hemiballism with nonketotic hyperglycemia: a new point of view. *Neurol Sci* 30(3):179–183. <https://doi.org/10.1007/s10072-009-0039-5>
30. Wang DM, Su S, Lin ZZ, Lai LY, Wu YM, Wang SN (2020) Recurrent hemichorea in a patient with diabetes and anti-phospholipid syndrome: a case report. *Chin Med J (Engl)* 133(6):753–755. <https://doi.org/10.1097/CM9.0000000000000698>
31. Yu F, Steven A, Birnbaum L, Altmeyer W (2017) T2\*-based MR imaging of hyperglycemia-induced hemichorea-hemiballism. *J Neuroradiol* 44(1):24–30. <https://doi.org/10.1016/j.neurad.2016.09.005>
32. Zheng W, Chen L, Chen JH, Lin X, Tang Y, Lin XJ, Wu J, Lin ZM, Lin JY (2020) Hemichorea associated with non-ketotic hyperglycemia: a case report and literature review. *Front Neurol* 11:96. <https://doi.org/10.3389/fneur.2020.00096>
33. Mestre TA, Ferreira JJ, Pimentel J (2007) Putaminal petechial haemorrhage as the cause of non-ketotic hyperglycaemic chorea: a neuropathological case correlated with MRI findings. *J Neurol Neurosurg Psychiatry* 78(5):549–550. <https://doi.org/10.1136/jnnp.2006.105387>
34. Cherian A, Thomas B, Baheti NN, Chemmanam T, Kesavadas C (2009) Concepts and controversies in nonketotic hyperglycemia-induced hemichorea: further evidence from susceptibility-weighted MR imaging. *J Magn Reson Imaging* 29(3):699–703. <https://doi.org/10.1002/jmri.21672>
35. Shan DE (2004) Hemichorea-hemiballism associated with hyperintense putamen on T1-weighted MR images: an update and a hypothesis. *Acta Neurol Taiwan* 13:170–177
36. Lucassen EB, Delfyett WT, Stahl MC (2017) Persistent hemichorea and caudate atrophy in untreated diabetic striatopathy: a case report. *Case Rep Neurol* 9(3):299–303. <https://doi.org/10.1159/000484201>

**Publisher's note** Springer Nature remains neutral with regard to jurisdictional claims in published maps and institutional affiliations.

Springer Nature or its licensor holds exclusive rights to this article under a publishing agreement with the author(s) or other rightsholder(s); author self-archiving of the accepted manuscript version of this article is solely governed by the terms of such publishing agreement and applicable law.