

## A rare endoscopic finding: acquired double pylorus

Mehmet Arhan · Erkin Oztas · Mehmet Ibis ·  
Semih Sezgin · Yasemin Ozin

Published online: 11 June 2009

© The Author(s) 2009. This article is published with open access at Springerlink.com

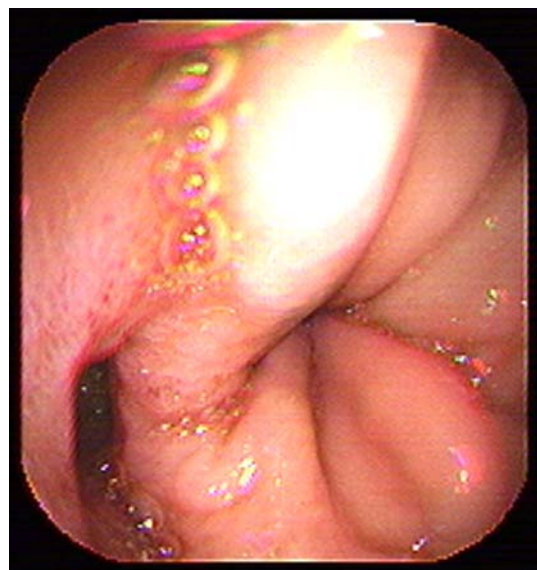
To the Editors,

A double pylorus is a relatively unusual endoscopic finding that has been reported in 0.001–0.4% of upper gastrointestinal endoscopies [1]. It can be either congenital or acquired. In most cases, it is a complication of peptic ulcer resulting from intramural penetration of the ulcer [2].

An 85-year-old female was admitted to our hospital with symptoms of hematemesis and melena. The patient was still using multiple medications for hypertension and coronary heart disease. Physical examinations revealed hypovolemic findings at time of admission to our hospital, cold sweating, tachycardia (pulse rate 124 beats per minute), and systolic blood pressure of 90 mmHg. Rectal digital examinations revealed melena. Complete blood count revealed hemoglobin level and hematocrit value of 5.8 g/dL and 17.9%, respectively. The endoscopic view from the antrum represented a gastroduodenal fistula located on the lesser curve of the antrum and near the anatomic pylorus. The endoscope could be passed through both of the ducts, from the antrum to the duodenal bulb (Figs. 1 and 2). Further endoscopic examination showed a deep duodenal ulcer (about 1.5 cm in diameter) on the anterior wall of the duodenal bulb (Fig. 3). Penetration to the antrum could be clearly demonstrated. There was coffee-ground appearance, representing blood in stomach, and multiple ulcers with various diameters on gastric mucosa, including the fundus and proximal part of the corpus. Active bleeding was not observed during endoscopic examination. Therefore, we did not perform any

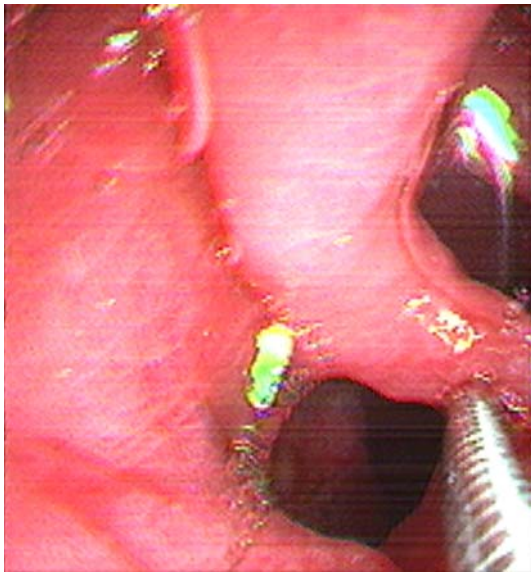
therapeutic procedures. The patient was hospitalized and oral alimentionation stopped, and we administered intravenous proton pump inhibitor medication. Rebleeding did not occur during the 7 days of follow-up period and the patient was discharged.

Double pylorus is a rare anomaly found in less than 0.4% of upper endoscopies [1, 2]. It is seen twice as often in males when compared with females [2]. Frequently, it is a complication of peptic ulcer disease, resulting from penetration of the peptic ulcer and the creation of a fistula between the duodenal bulb and the prepyloric antrum. Occasionally it may be congenital or secondary to gastric carcinoma [3, 4]. The location of the second duct is commonly in the lesser curvature of the gastric antrum, near the anatomic pylorus. Similarly, our patient's endoscopic

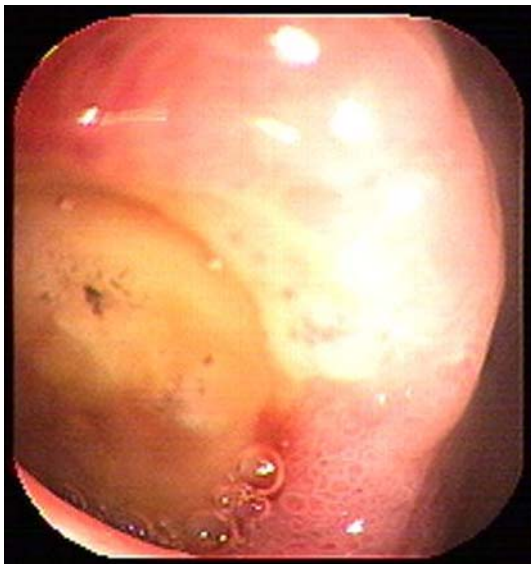


**Fig. 1** Second channel near pylorus

M. Arhan (✉) · E. Oztas · M. Ibis · S. Sezgin · Y. Ozin  
Department of Gastroenterology, Türkiye Yüksek İhtisas  
Hospital, Yunus Emre Caddesi, Yigitler sokak,  
9/3, Ankara, Turkey  
e-mail: mehmetarhan@gmail.com



**Fig. 2** Exploration of second channel with biopsy forceps



**Fig. 3** Duodenal ulcer on the anterior wall of the duodenal bulb

findings indicated that the second duct was acquired and originated from the ulcer located in duodenal bulb, penetrating the prepyloric antrum.

In most cases, as in our patient, this abnormality itself tends to be clinically silent [5]. It is mostly found incidentally by endoscopic or X-ray examination [6]. In our case, the presenting symptom was gastrointestinal bleeding from the gastric ulcers, a condition rarely reported in the literature [7, 8]. A long history of treatment with drugs including corticosteroids and nonsteroidal anti-inflammatory drugs (NSAIDs) may also prohibit healing, contributing to fistula

formation [2]. Our patient's previous medication included salicylic acid.

Treatment with anti-ulcer medication must be rapidly performed [9]. The majority of patients respond well to conservative treatment for peptic ulcers, regardless of whether the fistula remains open or is spontaneously closed [10]. In general, surgical intervention is not a choice of treatment [6], although it should be considered for patients with refractory symptoms, recurrent ulcers, and other complications, even in those taking strong anti-ulcer medication [5]. Spontaneous fusion of both ducts (real pylorus and pseudopylorus) only occurs in a small percentage of patients [2]. Endoscopic treatment is also feasible using a biliary sphincterotomy [5].

In conclusion, we would like to share an unusual case presenting with gastric ulcer bleeding who had a fistula originating from the duodenal bulb ulcer coincidentally seen during endoscopy.

**Open Access** This article is distributed under the terms of the Creative Commons Attribution Noncommercial License which permits any noncommercial use, distribution, and reproduction in any medium, provided the original author(s) and source are credited.

## References

1. Wiseman SM, Tan D, Hill HC (2005) Double pylorus: an unusual endoscopic finding. *Endoscopy* 37:277
2. Hu TH, Tsai TL, Hsu CC, Lu SN, Hsiao M, Changchien CS (2001) Clinical characteristics of double pylorus. *Gastrointest Endosc* 54(4):464–470
3. Mylonas A, Papaziogas B, Paraskevas G, Fragos E, Gigis P, Papaziogas T (2002) Congenital double pyloric ostium in the adult. *EcoHealth* 16:1639
4. Matsuyama E, Nagashima R, Watanabe S, Takahashi T (2001) Endoscopic hemostasis for hemorrhage from gastric cancer complicated by double-channel pylorus. *Gastrointest Endosc* 53:679
5. Graham SM, Lin F, Flowers JL (1994) Symptomatic double pylorus: successful treatment with a biliary sphincterotomy. *Surg Endosc* 8:792–793
6. McGrew W, Spear M, Sutton W, Dunn GD (1984) Acquired double pylorus. *South Med J* 77(9):1167–1170
7. Akazawa Y, Mizuta Y, Osabe M, Nakamura T, Morikawa S, Isomoto H et al (2005) A case of double pylorus caused by recurrent gastric ulcers: a long-term endoscopic observation. *Dig Dis Sci* 50:2125–2128
8. Almeida N, Romãozinho JM, Ferreira M, Amaro P, Tomé L, Gouveia H et al (2008) Double pylorus with bleeding gastric ulcer - a rare event. *Rev Esp Enferm Dig* 100(9):600–601
9. Tseng CW, Tsai JJ, Lin HJ (2008) Double pylorus: an unusual complication of peptic ulcer disease (with video). *Clin Gastroenterol Hepatol* 6(10):e38
10. Hu TH, Tai DI, Changchien CS, Chen TY, Chang WC (1995) Double pylorus: report of a longitudinal follow-up in two refractory cases with underlying diseases. *Am J Gastroenterol* 90:815–818