


Radiation Dose Aspects of Hepatic Artery Infusion Chemotherapy in Uveal Melanoma Patients with Liver Metastases

Sebastian Zensen¹  · Marcel K. Opitz¹ · Johannes M. Ludwig¹ · Johannes Haubold¹ · Heike Richly² · Jens T. Siveke^{3,4} · Jens M. Theysohn¹ · Michael Forsting¹ · Denise Bos¹ · Benedikt M. Schaarschmidt¹

Received: 9 January 2022 / Accepted: 19 March 2022 / Published online: 18 April 2022
© The Author(s) 2022

Abstract

Purpose In uveal melanoma patients, liver metastases can be treated by hepatic artery infusion chemotherapy (HAIC). During this procedure, melphalan or, less frequently, fotemustine is infused into the hepatic artery or the hepatic lobe arteries in regularly repeated interventions to achieve local tumor control. The aim of this study was to investigate the radiation exposure of HAIC.

Material and methods In this retrospective study, dose data from 841 procedures in 140 patients (mean age 65.3 ± 9.9 years, 74 female) who underwent HAIC between 06/2017 and 10/2021 at one of three different angiography systems were analyzed.

Results In the overall population, dose area product (DAP) (median (IQR)) was $1773 \text{ cGy}\cdot\text{cm}^2$ (884–3688). DAP was significantly higher in the first intervention, where a complete diagnostic workup of the vasculature was performed, than in follow-up interventions: $5765 \text{ cGy}\cdot\text{cm}^2$ (3160–8804) versus $1502 \text{ cGy}\cdot\text{cm}^2$ (807–2712) ($p < 0.0001$). DAP also increased significantly

with the number of infusion positions (median, (IQR)): one position $1301 \text{ cGy}\cdot\text{cm}^2$ (633–2717), two positions $1985 \text{ cGy}\cdot\text{cm}^2$ (1118–4074), three positions $6407 \text{ cGy}\cdot\text{cm}^2$ (2616–11590) ($p < 0.0001$).

Conclusion In uveal melanoma patients with liver metastases undergoing HAIC, radiation exposure is significantly higher both at the first intervention compared to follow-up interventions, but also with increasing number of infusion positions.

Level of evidence: 3

Introduction

Uveal melanoma (UM) is the most common primary malignancy of the eye and accounts for approximately 5% of all melanomas [1, 2]. Despite generally aggressive local tumor therapy, approximately 50% of all patients develop metastases, which are located most frequently in the liver [3–5]. Due to diffuse metastatic spread in this organ, liver-directed therapies such as transarterial chemoembolization (TACE), radioembolization (RE), or hepatic artery infusion chemotherapy (HAIC) are the primary treatment options [6, 7]. Particularly, repeated HAIC is a well-tolerated procedure, which has been shown to prolong progression-free survival with less severe hematologic adverse events compared to intravenous chemotherapy [8]. Due to the necessity to repeat this intervention regularly, radiation exposure should be diminished for the interventional radiologist and the patient alike [9].

✉ Sebastian Zensen
sebastian.zensen@uk-essen.de

¹ Institute of Diagnostic and Interventional Radiology and Neuroradiology, University Hospital Essen, Hufelandstraße 55, 45147 Essen, Germany

² Department of Medical Oncology, West German Cancer Center, University of Duisburg-Essen, Essen, Germany

³ Bridge Institute of Experimental Tumor Therapy, West German Cancer Center, University Medicine Essen, Essen, Germany

⁴ Division of Solid Tumor Translational Oncology, German Cancer Research Center (DKFZ) and German Cancer Consortium (DKTK), Partner Site Essen, Heidelberg, Germany

To our knowledge, data on radiation exposure of HAIC in patients with hepatic metastatic UM are limited [10]. This shortcoming shall be addressed by this study.

Material and Methods

Patient Cohort

Between June 2017 and October 2021, dose data of patients who underwent HAIC at our center were included in this retrospective study. Ethical approval was granted by the local ethics committee, and the requirement to obtain informed consent was waived (21-10256-BO).

Angiography Systems

All procedures were performed at one of three different angiography systems: the biplane angiography systems Artis Q biplane (Siemens Healthineers, Erlangen, Germany), Allura Xper FD20/10 system (Philips Healthcare, Eindhoven, The Netherlands), or the monoplane angiography system Artis zee MP (Siemens Healthineers, Erlangen, Germany). All systems are equipped with automatically controlled dose rate systems. All examinations were performed in monoplanar mode. Characteristic tube voltage was 70 kV. During all examinations, pulsed fluoroscopy was used. The pulse rate was chosen at the discretion of the interventional radiologist.

Hepatic Artery Infusion Chemotherapy Procedure

Standard HAIC was performed as described by Heusner et al. via a transfemoral access [7]. Coil embolization for flow distribution or vessels supplying extrahepatic organs, such as a prominent right gastric artery, was performed to avoid extrahepatic spread of the chemotherapeutic agent. To ensure a homogenous distribution of the chemotherapeutic agent, one (proper hepatic artery), two (mostly right and left hepatic artery), or three infusion positions (mostly right hepatic artery, lateral and medial left hepatic artery) were used. For follow-up interventions, the previous infusion positions were used. The chemotherapeutic agent was dissolved in 50 ml and applied by an automated injector, under intermittent position control by fluoroscopy. All patients started with 40 mg of melphalan, which was increased to a maximum of 50 mg, or the chemotherapeutic agent was switched to fotemustine in case of progression. Usually, HAIC was repeated every 6–8 weeks in our department.

Dose assessment

Dose measurements were extracted from the Digital Imaging and Communications in Medicine (DICOM) header and from the Radiation Dose Structured Report stored in the Picture Archiving and Communication System (PACS). Radiation exposure was determined in terms of dose area product (DAP).

Statistics and Data Analysis

Statistical analysis was performed using GraphPad Prism 5.01 (GraphPad Software, San Diego, USA). To determine normal distribution, Kolmogorov–Smirnov, Shapiro–Wilk, and D’Agostino–Pearson test was applied. Normally distributed data are reported as mean \pm standard deviation (SD), non-normally distributed data as median and interquartile range (IQR). Mann–Whitney U test was used for comparison of DAP between first HAIC and follow-up interventions and between HAIC with and without coil embolization. Kruskal–Wallis test with Dunn–Bonferroni post hoc test was performed for the comparison of DAP of HAIC as a function of the number of infusion positions. A p -value ≤ 0.05 was considered statistically significant.

Results

Patient Cohort

In our retrospective study, 841 HAICs performed between June 2017 and October 2021 in 140 patients could be included for evaluation. Mean age at first HAIC was 65.3 ± 9.9 years (range 39–85 years). 52.9% (74/140) of patients were female. The median number of HAICs per patient during the study period was four interventions (IQR 3–8).

Radiation Exposure and Comparison of First and Follow-Up Intervention

In the analyzed cohort, median radiation exposure of HAIC in terms of DAP was $1773 \text{ cGy}\cdot\text{cm}^2$ (IQR $884\text{--}3688 \text{ cGy}\cdot\text{cm}^2$) (Table 1). Median DAP was significantly higher at first HAIC by a factor of 3.8 (median $5765 \text{ cGy}\cdot\text{cm}^2$, IQR $3160\text{--}8804 \text{ cGy}\cdot\text{cm}^2$, 131/841 HAICs) compared with follow-up interventions (median $1502 \text{ cGy}\cdot\text{cm}^2$, IQR $807\text{--}2712 \text{ cGy}\cdot\text{cm}^2$, 710/841 HAICs) ($p < 0.0001$) (Fig. 1). In HAICs with coil embolization, the median DAP ($6054 \text{ cGy}\cdot\text{cm}^2$, IQR $861\text{--}3354 \text{ cGy}\cdot\text{cm}^2$, 32/841 HAICs) was significantly higher by a factor of 3.5 than in interventions without coil embolization ($1730 \text{ cGy}\cdot\text{cm}^2$, IQR $2770\text{--}12,960 \text{ cGy}\cdot\text{cm}^2$, 809/841

Table 1 Radiation exposure in terms of dose area product (DAP) of hepatic artery infusion chemotherapy (HAIC)

HAIC type	n	DAP [cGy·cm ²]		
		25th percentile	Median	75th percentile
Total	841	884	1773	3688
First intervention	131	3160	5765	8804
Follow-up intervention	710	807	1502	2712
with coil embolization	32	2770	6054	12,960
without coil embolization	809	861	1730	3354
1 position	358	633	1301	2717
2 positions	454	1118	1985	4074
3 positions	29	2616	6407	11,590

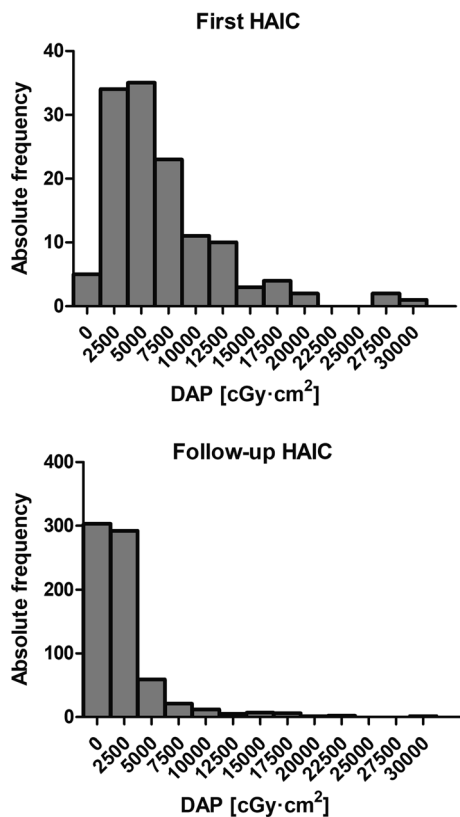


Fig. 1 Histograms of the dose area product (DAP) of the first and follow-up hepatic artery infusion chemotherapies (HAIC). The x-axis shows the bin centers. In each histogram, one data point above 50,000 cGy·cm² is not depicted in the graph

HAICs) ($p < 0.0001$), with 56.3% (18/32) of all coil embolizations performed prior to the first HAIC (Fig. 2). Radiation exposure of HAIC was significantly increased by the number of infusion positions ($p < 0.0001$) (median, IQR): one position 1301 cGy·cm² (633–2717 cGy·cm², 358/841 HAICs), two positions 1985 cGy·cm² (1118–4074 cGy·cm², 454/841 HAICs), three positions 6407 cGy·cm² (2616–11,590 cGy·cm², 29/841 HAICs) (Fig. 3). Thus, median DAP was increased by approximately 53% for 2 positions and by approximately 493% for

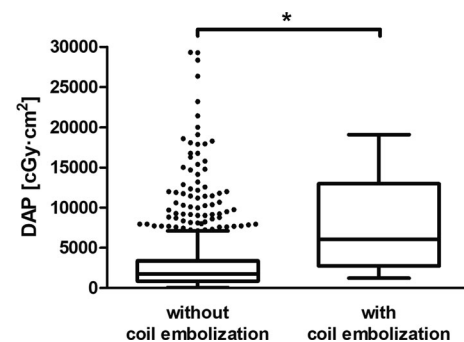


Fig. 2 Dose area product (DAP) of hepatic artery infusion chemotherapy (HAIC) with and without coil embolization. Points show outliers outside the Tukey whiskers. Two outliers above 50,000 cGy·cm² are not depicted in the graph for the group without coil embolization. Asterisk indicates statistically significant difference

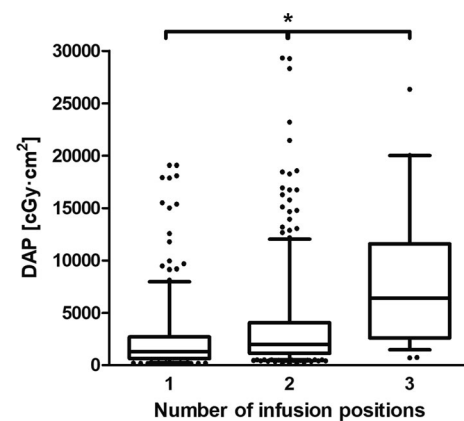


Fig. 3 Dose area product (DAP) of hepatic artery infusion chemotherapy (HAIC) as a function of the number of infusion positions. Points show outliers outside the Tukey whiskers. For 1 and 3 infusion positions, one outlier each above 50,000 cGy·cm² is not depicted in the graph. Asterisk indicates statistically significant difference

3 positions compared with HAIC with only 1 infusion position.

Discussion

HAIC is an important treatment option for patients with liver metastases from uveal melanoma. Here, further standardization might lead to a further reduction of radiation exposure for patients and interventional radiologists alike. The results of our study can be subsumed in two key points. First, radiation exposure is significantly increased for the initial intervention compared with follow-up interventions. Second, interventions with coil embolization and interventions with multiple infusion positions are associated with a higher radiation exposure.

For the palliative treatment of liver metastases in UM patients, HAIC is considered a valuable treatment option [1, 11]. As regular repetitions of this intervention are a necessity, dose optimization deserves special consideration and might be beneficial for the patient, the interventional radiologist, and his team alike [12–15].

Our study showed that radiation exposure was significantly higher in the first HAICs than in follow-up interventions, as complete visualization of the liver vasculature was performed with multiple contrast injector DSA series of the arteries supplying the liver. Furthermore, especially additional coil embolization during HAIC resulted in significantly higher radiation exposure. As most coil embolizations were performed during the first HAIC, the disproportionate share of coil embolizations might also contribute to their higher radiation exposure.

Depending on the individual vascular anatomy, it might be necessary to perform HAIC not only in one but in multiple liver arteries to achieve an equal distribution of the chemotherapeutic agent in both liver lobes. However, an increase in infusion positions results in repeated changes of the catheter positions during HAIC. Consecutively, additional radiation exposure is necessary. Here, a second infusion position resulted approximately in a 53% increase in radiation exposure, whereas a third infusion position increased radiation exposure to approximately five times compared to HAICs with one infusion position.

The limitations of our study are its retrospective and single-center study design. However, this preliminary data might serve as an important guide to improve radiation exposure during HAIC.

In conclusion, in uveal melanoma patients with liver metastases, radiation exposure is significantly increased for the first intervention compared with follow-up interventions, for interventions with coil embolization, and for interventions with multiple infusion positions.

Funding Open Access funding enabled and organized by Projekt DEAL. This study was not supported by any funding.

Declarations

Conflict of interest S. Zensen was supported as Junior Clinician Scientist, and D. Bos and J. Haubold were supported as Clinician Scientists and received research grants under the University Medicine Essen Academy (UMEA) program funded by the German Research Foundation (DFG; Grant FU356/12-1) and the Faculty of Medicine, University of Duisburg-Essen. Benedikt M. Schaarschmidt is supported by a research grant from PharmaCept, outside the submitted work.

Ethical Approval All procedures performed in studies involving human participants were in accordance with the ethical standards of the institutional and/or national research committee and with the 1964 Helsinki declaration and its later amendments or comparable ethical standards. For this type of study, formal consent is not required.

Informed Consent This study has obtained IRB approval from the Faculty of Medicine, University of Duisburg-Essen, and the need for informed consent was waived.

Consent for Publication For this type of study, consent for publication is not required.

Open Access This article is licensed under a Creative Commons Attribution 4.0 International License, which permits use, sharing, adaptation, distribution and reproduction in any medium or format, as long as you give appropriate credit to the original author(s) and the source, provide a link to the Creative Commons licence, and indicate if changes were made. The images or other third party material in this article are included in the article's Creative Commons licence, unless indicated otherwise in a credit line to the material. If material is not included in the article's Creative Commons licence and your intended use is not permitted by statutory regulation or exceeds the permitted use, you will need to obtain permission directly from the copyright holder. To view a copy of this licence, visit <http://creativecommons.org/licenses/by/4.0/>.

References

1. Rowcroft A, Loveday BPT, Thomson BNJ, et al. Systematic review of liver directed therapy for uveal melanoma hepatic metastases. *HPB*. 2020;22(4):497–505. <https://doi.org/10.1016/j.hpb.2019.11.002>.
2. Singh AD, Turell ME, Topham AK. Uveal melanoma: trends in incidence, treatment, and survival. *Ophthalmology*. 2011;118(9):1881–5. <https://doi.org/10.1016/j.ophtha.2011.01.040>.
3. Rietschel P, Panageas KS, Hanlon C, et al. Variates of survival in metastatic uveal melanoma. *J Clin Oncol*. 2005;23(31):8076–80. <https://doi.org/10.1200/JCO.2005.02.6534>.
4. Damato BE, Coupland SE. Differences in uveal melanomas between men and women from the British Isles. *Eye*. 2012;26(2):292–9. <https://doi.org/10.1038/eye.2011.272>.
5. Diener-West M, Reynolds SM, Agugliaro DJ et al. (2005) Development of metastatic disease after enrollment in the COMS trials for treatment of choroidal melanoma: Collaborative Ocular Melanoma Study Group Report No 26. *Arch Ophthalmol* 123(12):1639–1643. <https://doi.org/10.1001/archophth.123.12.1639>
6. Schelhorn J, Richly H, Ruhlmann M, et al. A single-center experience in radioembolization as salvage therapy of hepatic metastases of uveal melanoma. *Acta Radiol Open*.

- 2015;4(4):2047981615570417. <https://doi.org/10.1177/2047981615570417>.
7. Heusner T-A, Antoch G, Wittkowski-Sterczewski A, et al. Transarterial hepatic chemoperfusion of uveal melanoma metastases: survival and response to treatment. *Fortschritte auf dem Gebiete der Röntgenstrahlen und der Nuklearmedizin*. 2011;183(12):1151–60. <https://doi.org/10.1055/s-0031-1281743>.
 8. Leyvraz S, Piperno-Neumann S, Suciú S, et al. Hepatic intra-arterial versus intravenous fotemustine in patients with liver metastases from uveal melanoma (EORTC 18021): a multicentric randomized trial. *Ann Oncol*. 2014;25(3):742–6. <https://doi.org/10.1093/annonc/mdt585>.
 9. Miller DL, Vañó E, Bartal G, et al. Occupational radiation protection in interventional radiology: a joint guideline of the Cardiovascular and Interventional Radiology Society of Europe and the Society of Interventional Radiology. *Cardiovasc Intervent Radiol*. 2010;33(2):230–9. <https://doi.org/10.1007/s00270-009-9756-7>.
 10. Hui Y, Hai-Lei LU, Jia-Huan Z, et al. Comparison of radiation dose between hepatic artery infusion chemotherapy and transarterial chemoembolization for liver cancer. *J Intervent Med*. 2021. <https://doi.org/10.1016/j.jimed.2021.08.004>.
 11. Boone BA, Perkins S, Bandi R, et al. Hepatic artery infusion of melphalan in patients with liver metastases from ocular melanoma. *J Surg Oncol*. 2018;117(5):940–6. <https://doi.org/10.1002/jso.24984>.
 12. Miller DL. Overview of contemporary interventional fluoroscopy procedures. *Health Phys*. 2008;95(5):638–44. <https://doi.org/10.1097/01.hp.0000326341.86359.0b>.
 13. Stecker MS, Balter S, Towbin RB, et al. Guidelines for patient radiation dose management. *J Vasc Intervent Radiol*. 2009;20(7 Suppl):S263–73. <https://doi.org/10.1016/j.jvir.2009.04.037>.
 14. Alkhorayef M, Al-Mohammed HI, Mayhoub FH, et al. Staff radiation dose and estimated risk in an interventional radiology department. *Radiat Phys Chem*. 2021;178: 108999. <https://doi.org/10.1016/j.radphyschem.2020.108999>.
 15. König AM, Etzel R, Thomas RP et al. (2019) Persönliche Strahlenschutzmittel und Dosimetrie des medizinischen Personals in der interventionellen Radiologie: Aktueller Status und neue Entwicklungen (Personal Radiation Protection and Corresponding Dosimetry in Interventional Radiology: An Overview and Future Developments). *RoFo: Fortschritte auf dem Gebiete der Röntgenstrahlen und der Nuklearmedizin* 191(6): 512–521. <https://doi.org/10.1055/a-0800-0113>
- Publisher's Note** Springer Nature remains neutral with regard to jurisdictional claims in published maps and institutional affiliations.