


Microwave Ablation for Resolution of Persistent Biloma Following Hepatectomy and Cholecystectomy: Case Report

Alan Yang¹  · Matthew Mitchell¹ · John Di Capua² · Avik Som² · Junjian Huang³ · Ralph Weissleder⁴ · Sanjeeva Kalva² · Raul Uppot²

Received: 21 September 2021 / Accepted: 24 October 2021 / Published online: 5 November 2021

© Springer Science+Business Media, LLC, part of Springer Nature and the Cardiovascular and Interventional Radiological Society of Europe (CIRSE) 2021

To the Editor,

The authors present a case of a patient who, after receiving a partial, non-segmental hepatectomy and cholecystectomy, developed a biloma which persisted for ~2 years and was finally cured with microwave ablation (MWA) following several ineffective attempts to treat with drainage catheterization, embolization, and biliary stenting (Fig. 1).

A 43-year-old male with a previous history of ulcerative colitis and primary sclerosing cholangitis presented to the operating room in March 2018 for right partial hepatectomy, open cholecystectomy, and portal lymphadenectomy for recently diagnosed cholangiocarcinoma. On postoperative day 9 the patient was found to have a fluid collection (4.3 cm × 9.1 cm) along the hepatectomy resection margin. A 12 Fr multipurpose (MP) catheter was placed into the collection with aspiration of 600 cc of purulent fluid. Because of continued drainage over several months, the patient was transferred to the authors' institution.

Upon admission, the 12 Fr MP drainage catheter had persistent bilious output of ~100-150 cc/day. Three 7 Fr plastic stents were placed via ERCP in the hope of diverting flow. The patient received several selective

abscess drain studies with an attempt to define the biliary leakage site over the next 7 months. Initially these demonstrated a single bile duct emptying into the cavity, but re-imaging revealed at least four separate leaking ducts—an unusual presentation (Fig. 2). In October 2018, several selective percutaneous onyx embolizations of the injured biliary ducts were performed. Despite decreased output initially, over time the patient continued to experience biliary leakage.

Thus, in January 2020 a CT-guided percutaneous MWA of the prior hepatectomy resection margin was performed to stricture the leaking biliary ducts. A 2.45 GHz 16-gauge 15 cm antenna applicator (HS-AMICA-Gen, H.S. Hospital Service S.p.A., Rome, Italy) was advanced into the region of the leaking bile ducts. One thermal ablation was performed using 60 watts × 5 min; we chose energy settings based on antenna spacing and expected thermal volumes. Subsequently, the antenna was advanced into the inferior bile duct, and another thermal ablation was performed for 20 watts × 3 min. No liver separation via hydrosissection or other methods was necessary. Post-procedural CT did not reveal any immediate complications. A 10 Fr catheter was left in the resection bed.

During the month following the MWA, drainage injections showed a small persistent fluid collection along the hepatectomy margin, and the patient reported drainage of ~50-60 cc/day. No further tube injections took place in the ensuing ~4 months due to the COVID-19 pandemic. During this intervening time, the patient reported a decrease in the volume of bilious leakage. Three months after the ablation, there was scant serous output, and the drainage catheter was capped a month later. 4.5 months after the ablation, drain injection and CT showed expected retraction of the ablation zone and decreased biloma size

✉ Alan Yang
alan_yang@hms.harvard.edu

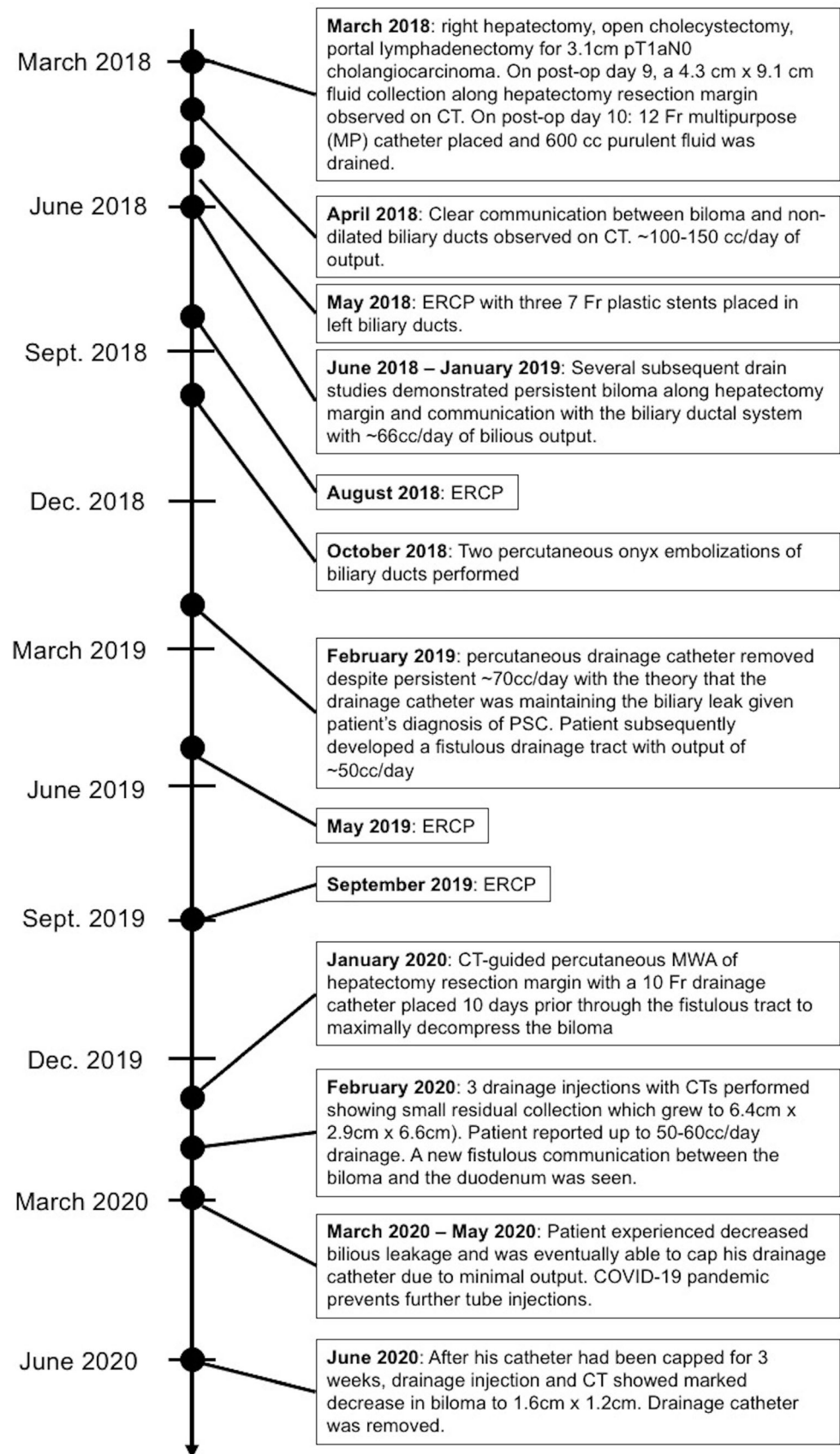
¹ Harvard Medical School, 524 Quincy House Mail Center, 58 Plympton Street, Cambridge, MA 02138, USA

² Department of Radiology, Massachusetts General Hospital, Boston, USA

³ University of Alabama at Birmingham, Birmingham, USA

⁴ Center for Systems Biology, Massachusetts General Hospital, Boston, USA

Fig. 1 Timeline of the 43-year-old male whose recalcitrant 2-year-long biloma was successfully treated with MWA following several unsuccessful attempts at drainage catheterization, ERCP, and onyx embolization



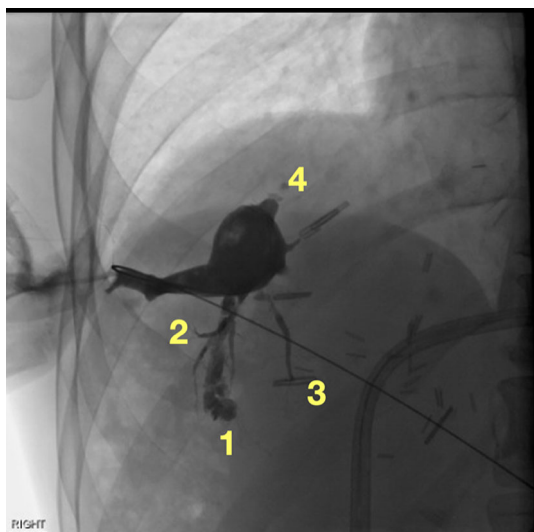


Fig. 2 CT image showing four separate leaking ducts along hepatectomy margin

(1.6 cm × 1.2 cm). The percutaneous drainage catheter was removed. 21 months after the ablation, the patient has undergone another 5 MRCPs, 2 MRIs, and 4 CTs with no evidence of recurring biliary leakage.

This case represents an uncommon attempt to treat a biloma with MWA. Several treatment options exist for persistent biliary leakage from isolated bile ducts. Ductal packing with onyx or glues has been attempted with mixed results [1, 2]. More recently, ethanol injections have been

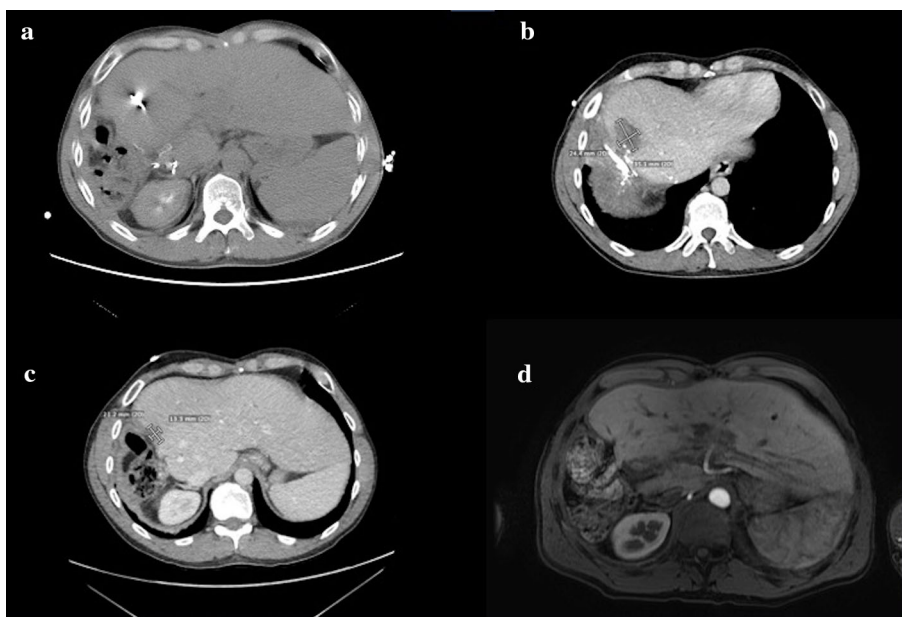
advocated to sclerose biliary ducts [3]. Finally, ablative methods such as RFA and MWA have been used to ablate hepatic tumors and surrounding hepatic parenchyma [4]. Based on the timeline of treatments, the authors believe that MWA was successful in treating this patient as the microwave ablation cavity slowly healed over several months. The initial persistent biliary leakage immediately following MWA could have been due to residual untreated smaller ducts which sclerosed over time with hepatic healing. Regardless, a decrease in biloma size was only noted after the MWA procedure (Fig. 3), and no other treatments were given during that time.

Funding This study was not supported by any funding.

Declarations

Conflict of interest Avik Som is Chief Medical Officer and board member of CareSignal Health, Inc. Raul Uppot receives funding from the American College of Radiology Innovation Grant. Raul Uppot is a consultant for Boston Scientific and Philips Healthcare. Raul Uppot holds collaboration agreements with Case Western, Luxonic, Intrado, Microsoft. Sanjeeva Kalva is a consultant for Boston Scientific, Medtronic, Penumbra, Okami Medical, US Vascular, Koo Foundation, and Dova pharmaceuticals. Sanjeeva Kalva receives royalties from Springer, Thieme, Elsevier. Sanjeeva Kalva provides research support to NIH, BD, and Black Swan. Sanjeeva Kalva has ownership in Althea Health, CA; stocks in Moderna, Inovia pharmaceuticals, Ardelyx Inc, Biogen Inc, Clover Health Investment Corp, and Infinity pharmaceuticals. Ralph Weissleder is a consultant for Moderna, Tarveda, Lumicell, Seer, Earli, Aikili Biosystems, and Accure Health.

Fig. 3 **a** Microwave ablation procedural CT in January 2020. **b** CT obtained in February 2020. **c** CT obtained in June 2020 demonstrating contracture of the ablation zone. **d** MRI from November 2020 demonstrating resolution



Consent for Publication For this type of study consent for publication is not required.

Ethical Approval For this type of study formal consent is not required.

Informed Consent The study was HIPAA compliant and approved by the Institutional Review Board with waiver of patient consent. For this type of study informed consent is not required.

References

1. Uller W, Müller-Wille R, Loss M, Hammer S, Schleder S, Goessmann H, et al. Percutaneous management of postoperative bile leaks with an ethylene vinyl alcohol copolymer (Onyx). *RöFo - Fortschritte auf dem Gebiet der Röntgenstrahlen und der Bildgebungsverfahren*. 2013;185(12):1182–7. <https://doi.org/10.1055/s-0033-1350153>.
2. Vu DN, Strub WM, Nguyen PM. Biliary duct ablation with n-butyl cyanoacrylate. *J Vasc Interv Radiol*. 2006;17(1):63–9.
3. Sasaki M, Hori T, Furuyama H, Machimoto T, Hata T, Kadokawa Y, et al. Postoperative biliary leak treated with chemical bile duct ablation using absolute ethanol: a report of two cases. *Am J Case Rep*. 2017;18:871–7.
4. Sartori S, Tombesi P, Di Vece F. Radiofrequency, microwave, and laser ablation of liver tumors: time to move toward a tailored ablation technique? *Hepatology Res*. 2015;1(2):52.

Publisher's Note Springer Nature remains neutral with regard to jurisdictional claims in published maps and institutional affiliations.