Eur J Nucl Med Mol Imaging (2011) 38:1957
DOI 10.1007/s00259-011-1795-z

IMAGE OF THE MONTH

Abnormal pelvic uptake on post-therapeutic radioiodine (^{131}I) whole-body scan

Desiree Deandreis · Jean Lumbroso · Abir Al Ghuzlan · Eric Baudin · Martin Schlumberger · Sophie Leboulleux

Received: 18 February 2011 / Accepted: 7 March 2011 / Published online: 2 April 2011

A 36-year-old woman was referred after total thyroidectomy with central neck dissection to the Institut Gustave Roussy for radioactive iodine (^{131}I) ablation after recombinant human thyrotropin (rhTSH) stimulation for a pT2 N0 minimally invasive follicular thyroid carcinoma. The whole-body scan (WBS) performed 3 days after the administration of radioiodine (3.7 GBq) showed thyroid bed uptake due to normal thyroid remnant and an uptake focus in the left pelvic region (a, arrow). Stimulated thyroglobulin (TG) was 10 ng/ml in the absence of TG antibodies. The pelvic ^{131}I uptake was correlated to an ovarian cystic mass of 37 mm, as shown on ultrasonography (US) (b). The cyst was removed and histology showed a mature teratoma with a normal thyroid tissue component (c, arrow).

Ectopic uptake of ^{131}I not due to thyroid cancer metastases has been described in several sites, the most frequent being breast, thymus and gastrointestinal tract [1, 2]. This might cause misleading interpretations of images, even if actually the use of SPECT/CT should help for the interpretation of such images.

^{131}I uptake in extrathyroidal tissue can be due to the expression of NaI (sodium-iodide) symporter or to tracer excretion artefact, but in some cases the cause is still not clear [1, 3]. In the pelvic region, ^{131}I uptake has been reported in cases of dermoid cysts containing thyroid tissue, but also in benign pathological conditions without thyroid tissue component such as cystadenofibromas or leiomyoma [1, 4, 5]. The presence of pelvic ^{131}I uptake on post-ablation WBS should raise the hypothesis of a gynaecological pathological condition and be further explored.

D. Deandreis (✉) · J. Lumbroso · A. Al Ghuzlan · E. Baudin · M. Schlumberger · S. Leboulleux
Institut Gustave Roussy,
Villejuif, France
e-mail: desiree.deandreis@igr.fr

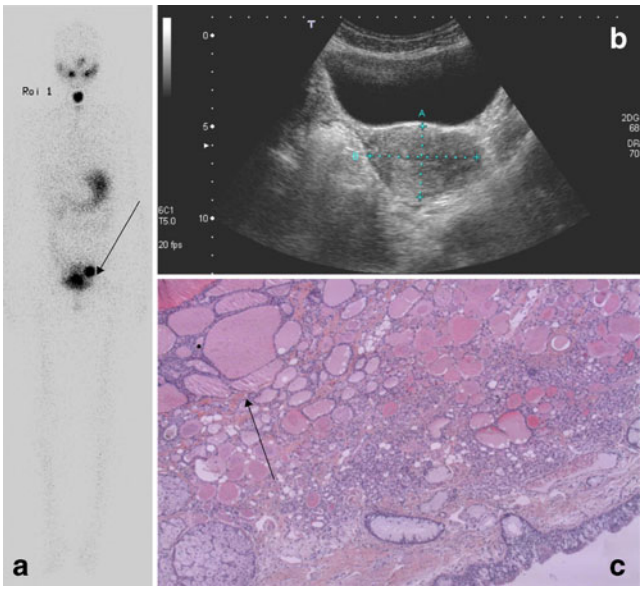

Conflicts of interest None.

References

1. Bakheet SM, Hammami MM, Powe J. False-positive radioiodine uptake in the abdomen and the pelvis: radioiodine retention in the kidneys and review of the literature. Clin Nucl Med 1996;21(12):932–7.
2. Vermiglio F, Baudin E, Travagli JP, Caillou B, Fragu P, Ricard M, et al. Iodine concentration by the thymus in thyroid carcinoma. J Nucl Med 1996;37:1830–1.
3. Bruno R, Giannasio P, Ronga G, Baudin E, Travagli JP, Russo D, et al. Sodium iodide symporter expression and radioiodine distribution in extrathyroidal tissues. J Endocrinol Invest 2004;27(11):1010–4.
4. Turker O, Dogan I, Kumanlioglu K. Radioiodine accumulation in a large adnexal cystadenofibroma. Thyroid 2010;20(5):561–2.
5. Hirata K, Shiga T, Kubota KC, Okamoto S, Kamibayashi T, Tamaki N. Radioiodine therapy for thyroid cancer depicted uterine leiomyoma. Clin Nucl Med 2009;34(3):180–1.