

Drug-Induced Leukoencephalopathy: MR Follow-Up After Corticosteroid Therapy

Case **50**

Teresa Popolizio, Nicola Sforza,
and Rosario Francesco Balzano

- 42-year-old patient with Crohn's disease.
- Early MR follow-up after steroid therapy.

Early Follow-Up After Steroid Therapy

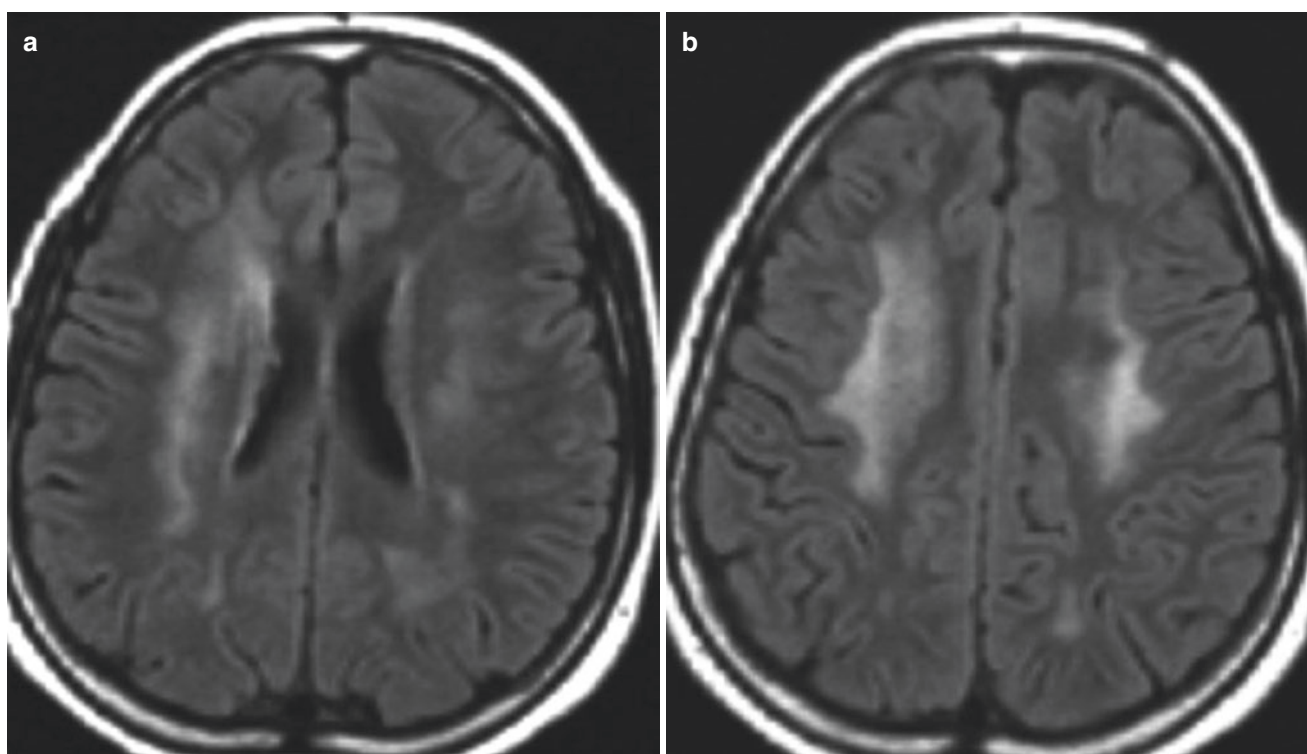


Fig. 50.1 (a, b) MR FLAIR sequences show diffuse bilateral hyperintensity of the periventricular white matter

T. Popolizio (✉) · N. Sforza
Department of Neuroradiology, Fondazione IRCCS “Casa Sollievo
della Sofferenza”, San Giovanni Rotondo, FG, Italy

R. F. Balzano
Department of Radiology, University of Foggia, Foggia, FG, Italy