

RESEARCH

Open Access



Endoscope Assisted Microvascular Decompression: Are the Advantages Still Worthy Towards More?

Ashraf Mohamed Farid*  and Sherif Elsayed ElKheshin

Abstract

Background: Microvascular decompression is the definitive treatment of various neuralgias affecting cranial nerves. The compression on a cranial nerve could be at the root entry zone, especially the trigeminal nerve. Endoscope-assisted microsurgery may help avoid missing a hidden vascular structure.

Study design: Retrospective clinical case series.

Patient and methods: Twenty-five patients with facial pain and five patients with hemifacial spasm constituted this study. FIESTA MRI was the pre-operative neuroimaging modality. Retrosigmoid craniectomy was done for all patients. Microscope was initially used for exploration and arachnoid dissection around the nerve. The endoscope was applied thereafter for exploration and confirmation of the proper insertion of the Teflon.

Results: Using the endoscope, cerebellar retraction was reduced by 0.5 to 0.8 cm in 90% of patients. Root entry zone and entry of the nerve through the corresponding skull base foramen was clearly visualized by the endoscope. Endoscope enabled a wider area of exploration and panoramic view, which could not be obtained by the microscope. Patients with trigeminal neuralgia had a median pre-operative VAS of 9, while it was only 1 in early post-operative and 0 in 6-month post-operatively. Patients with HFS were completely recovered.

Conclusion: The advantages of microvascular decompression are still worthy. Complications are minimal, and the view is much more panoramic. The different viewing angles and ability to directly reach corners is an absolute endoscopic advantage. Therefore, avoidance of missing vascular structures and incomplete recovery can be assured.

Keywords: MVD, Endoscope-assisted microneurosurgery

Introduction

Microvascular decompression (MVD) is considered as the definitive treatment modality for vascular compression on cranial nerves. The usual site of vascular compression is at the root entry zone [1, 2]. Missing vascular structure was reported and resulted in incomplete relief of symptoms following surgery [3]. Endoscope-assisted microsurgery for various lesions in the cerebellopontine angle resulted in optimization of the surgical procedures, especially in MVD where it resulted in the identification of the entire course of the cranial nerve and avoidance of any missing

vascular structure [4]. The endoscope is useful in minimizing the cerebellar retraction compared with the microscope. It enables wider areas of exploration especially behind bony ridges. With the endoscope, a true close up view and better identification of the course of the vessel could be achieved [5]. We aim to demonstrate the advantages given by the endoscope over the microscope regarding surgery for neurovascular compression syndromes.

Patients and methods

Patient population

This study was applied to 30 patients (31–62 years) in the department of neurosurgery, Tanta University Hospitals

* Correspondence: Aschraffarid@gmail.com
Neurosurgery Department, Tanta University, Tanta, Egypt

in the period from January 2017 to January 2019. Those patients were operated upon using endoscope-assisted microvascular decompression for trigeminal neuralgia in 25 patients, while the same procedure was applied to five patients suffering from hemifacial spasm. The main symptom was facial pain (measured by visual analogue scale); VAS ranged from 7 to 10 (Table 1). Patients underwent MVD procedure had no response to at least 3 medications or percutaneous procedures for the treatment of trigeminal neuralgia. Dose escalation of carbamazepine was performed in all patients starting from total daily 600 mg up to 2400 mg as long it is tolerated by the patient. A second medication, Gabapentin was used as add on starting with 200 mg daily to be escalated to a maximum of 3600/day. Lamotrigine was considered as the third add on drug. All 25 patients failed to keep improved on combined medications [6, 7].

Patients with hemifacial spasm had a typical involuntary continuous contraction of the facial muscles. Patients who have symptoms secondary to neoplasms or multiple sclerosis were excluded. Patient's rights regarding confidentiality was assured. All patients were consented based upon the conclusion of the study of Kondziolka et al. [8] This study has been approved by the research ethics, Faculty of Medicine, Tanta University (approval code: 33295/8/19), obtained on August 2019. In addition, being a retrospective study, consents for participation and for publication were not applicable. Additionally, the co-author has no competing interest to report.

Imaging

Pre-operative brain MRI was requested, focusing on (FI-ESTA) "fast imaging employing steady state acquisition" to demonstrate vascular compression on the cranial nerves.

Table 1 Patient population in whom MVD was performed for TN

		<i>N</i> = 25
Age	Min-max	31-60
	Average	49.64
Gender	Female	19
	Male	6
Pain distribution	V1	2
	V2	5
	V3	10
	V1, V2	3
	V1, V2, V3	2
	V2, V3	3
Preoperative VAS	Min-max	7-10
	Median (IQR)	9

Anaesthetic precautions were taken, aiming at optimum relaxation of the cerebellum. Propofol was the suitable drug. The park-bench position was applied to all patients.

Surgical technique

Retrosegmental craniectomy was applied to all patients. Curvilinear skin incision was applied, beginning 1–2 cm medial to the mastoid tip then upwards of about 4–5 cm. Muscles were carefully dissected till reaching the lateral occipital bone and the mastoid groove. Craniectomy was fashioned as a rounded 2–3 cm diameter, located between the superior nuchal line and mastoid bone. The dura was opened in a curvilinear way protecting the cerebellum behind it. CSF was allowed to egress from cisterna magna for optimum relaxation of the cerebellum. The distance between the petrous bone and the petrosal surface of the cerebellum was initially measured. The operating microscope was then introduced and directed towards the tentorium cerebelli to explore the upper complex, then reoriented to explore the middle and lower complexes. The distance between petrous bone and the petrosal surface of the cerebellum was measured again after the retraction of the cerebellum (Table 4). The retraction of the cerebellum was intermittent with an average time 2 min, using a wet cottonoid on its petrosal surface and a non-traumatic suction tube. Arachnoid dissection between the nerve and the artery was carefully done utilizing the magnification power of the operating microscope. Patients in whom MVD was done for HFS, intraoperative monitoring was used to assure facial nerve preservation. The endoscope (Karl Storz® Germany) was then introduced. A full inspection of the upper, middle, and lower complexes was done using 0° lens. The endoscopic inspection included the entire course of the nerve and confirmation of the proper position of the Teflon piece (Tables 2 and 3). Vascular compression was released which was found, affecting both the trigeminal and facial nerves. Finally, a piece of Teflon was used to isolate the nerve from the offending vessel(s) (Figs. 2 and 4c).

Post-operative care and follow-up

Following the assessment of the conscious level, ICU admission was considered for all patients. Postoperative evaluation of pain was done using the visual analogue scale and compared with the preoperative record. After discharge, regular follow-up visits were planned with the patient.

Results

Trigeminal neuralgia

Through the microscope, it was difficult to explore the trigeminal root entry zone without addition of about 3–

Table 2 Operative data of patients with TN

		All patients (25)
Timing till surgery (months)	Min-max	1-5
	Median	3
Compressing vessels (TN)	AICA	22
	Venous	3
Role of the endoscope	Assisting microscope	25
	Main role	0
Post-operative complications	Hypoesthesia	2
	Cerebellar hemorrhage	1
Postoperative VAS (24 h)	Min-max	1-6
	Median (IQR)	1
Postoperative VAS (6 months)	Min-max	0-5
	Median (IQR)	0

5 mm cerebellar retraction more than the range mentioned in Table 4 and re-orientation of the microscope more medially (Fig. 1b). Through the endoscope, it was possible also to explore the entry of the trigeminal nerve into Meckel's cave (Figs. 2a, b and 5). The endoscope, thus, could confirm that there is no missed vascular structure. There is a difference in the median of VAS for patients with TN pre-operatively (IQR = 9) and both early and late post-operative median VAS (IQR = 1 and 0), respectively. Only two patients had post-operative facial hypoesthesia (Table 2). One patient did not recover well. Immediate CT revealed cerebellar hematoma necessitated urgent evacuation and the patient recovered well.

Hemifacial spasm

On the other hand, through the microscope, it was also difficult to explore the site of entry of the facial nerve to the internal acoustic meatus. Part of the AICA loop was hidden underneath the suprameatal tubercle (Fig. 3c, d). Using the endoscope, it was possible also to explore at the internal acoustic meatus and entry of the facial nerve (Fig. 4a, b). Using intraoperative monitoring, no train or burst activity could result from vascular decompression around the facial nerve. All patients with hemifacial spasm had intact facial function postoperatively. The endoscope also was applied to confirm the proper position of the Teflon piece and full isolation of the nerve (Fig. 4c)

Table 3 Operative data of patients underwent MVD for treatment of HFS

		No	%
Offending vessel (HFS)	Anterior inferior cerebellar artery (AICA)	5	100
Surgical steps	Arachnoid dissection then Teflon separation	5	100
Role of the endoscope	Assisting microscope.	5	100

Table 4 Difference between the range of distance of cerebellar retraction through microscope and endoscope in all patients (TN and HFS)

	Microscope	Endoscope
Cerebellar retraction (cm)	2-2.5	1.5-1.7
Total	30	27

Discussion

Trigeminal neuralgia and hemifacial spasm are clinical syndromes, interfering with patients daily activity. Although pain could be remediable with medical therapy, 20-23% of patients fails to hold permanent relief. MVD is the treatment of choice in these particular cases [6].

Radiological evaluation

Thirty patients included in this study were subjected to FISTA MRI which revealed a single vessel in all of them. However, in three patients there were double veins seen by both microscopic and endoscopic inspection, constituting an accuracy level of 90%. Chen et al. 2011 [9] and El Refaee et al. 2013 [10] documented that 1.5 T, 3D MRI has positive predictive value of 86.6-91.5% while the accuracy of detection of vessels is variable and differs according to the vessel to be detected. Samii et al. 2002 [11], R. O. Sanchez et al. 2005 [12], and Rath et al. 1996 [13] found vascular compression that was not detected in MRI in 23.4% of their patients. This means a direct intraoperative visualization remains the highest confirmatory procedure.

Operative findings

In our study, the SCA was the compressing vessel in patients who had trigeminal neuralgia (22/25) (Table 2). Venous compression was found in 3/25 (Fig. 1b). AICA was the compressing vessel in all patients with HFS (100%) (Figs. 3c, d and 4a, b). Samii et al. 2002 [11] reported that not only the AICA was the main offending vessel (79%) but also PICA, vertebral artery, venous compression, and multiple vessels.

The role of the microscope

Samii et al. 2002 [11] reported 7/145 patients underwent redo surgery attributable to a possibility of missed vessels, scarring, and a new vessel that compressed the nerve after the first surgery. Klun [14] found that 30% of his patients who underwent re-exploration had missed

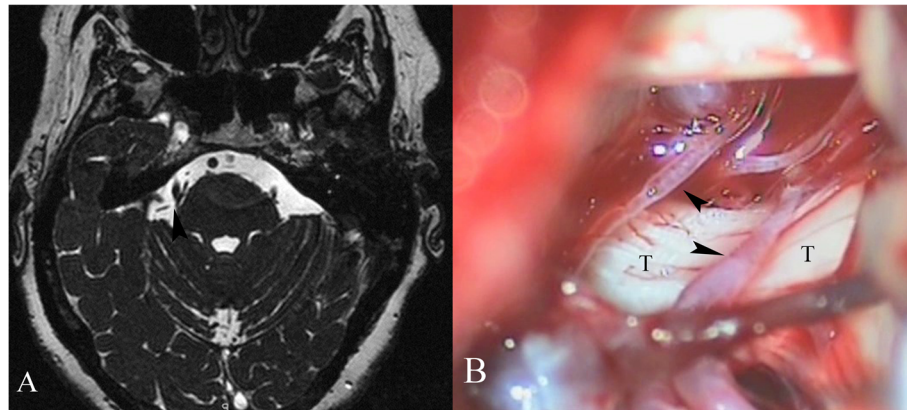


Fig. 1 **a** FIESTA showing vascular compression at the root of the right trigeminal nerve. **b** Microscopic view (right side): T, trigeminal nerve, arrowheads point to vascular compression

vessels at the first surgery. Jarrahy et al. 2002 [3] found that 27% of their patients had missed vessels-nerve conflicts. We believe that the likeliness of missing vessels might be attributable to inadequate exploration of the entire course of the nerve. Akkaya et al. 2019 [15] reported that 30.2% of his patients were not pain free following pure microscopic MVD. They highlighted that the surgical technique is an important factor affecting post-operative pain relief after MVD. They focused on a possibility of missing a venous conflict if the entire course of the nerve is not carefully examined during surgery.

Moreover, Sindou and Acevedo 2001 [16], clarified that the branches of SCA may be located between the medial side of the trigeminal root and anterolateral pons. Consequently, it may not be recognized through the microscope. Missing venous tributary could also emanate from the inadequate retraction of the cerebellum. Sauvain et al. 2001 [1] reported that full exploration,

especially at the origin of the facial nerve could not be achieved through the operating microscope because of its course underneath the flocculus. The meatal segment of AICA is also hidden at the site of the internal acoustic meatus.

Although we did not find any missed vascular compression after introduction of the endoscope, we could confirm that no missing vascular conflict with the endoscope so as to optimize our outcome. The recent study of Akkaya et al. 2019 [15] supported our idea. Our results showed that there is a difference between endoscopic and microscopic views for both TN (Figs. 1b, 2, and 5) and HFS (Figs. 3c, d and 4). Similarly, in our study, endoscope was superior to microscope in exploration, especially at the site of entry of the nerve at the meatus (Figs. 3c, d and 4).

In our study, microscopic cerebellar retraction in a range 2–2.5 cm was enough to expose the target nerve but not to visualize all the structures around especially

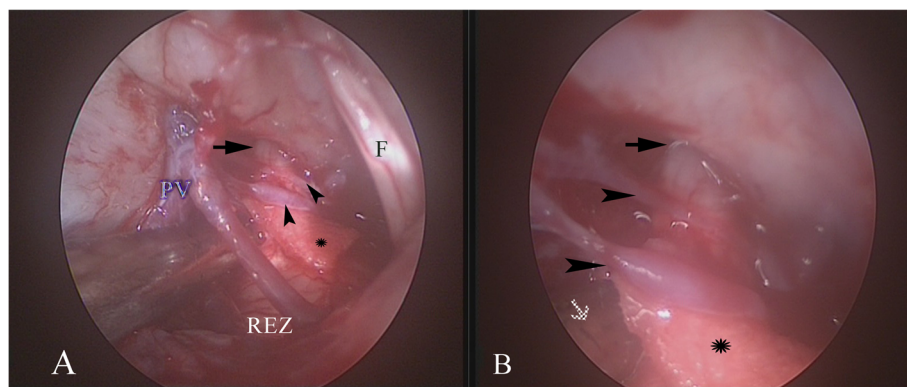


Fig. 2 Endoscopic view of MVD for trigeminal neuralgia (right side). **a** PV, petrosal vein. REZ, root entry zone. Arrowheads point to vascular compression separated by a piece of Teflon. F., facial nerve. Arrow points to the entry of the trigeminal nerve into the Meckel's cave. **b** Close up view, arrow points to the entry of the trigeminal nerve into the Meckel's cave. Arrowheads point to the vascular compression. Asterix, Teflon piece. White arrow brain stem

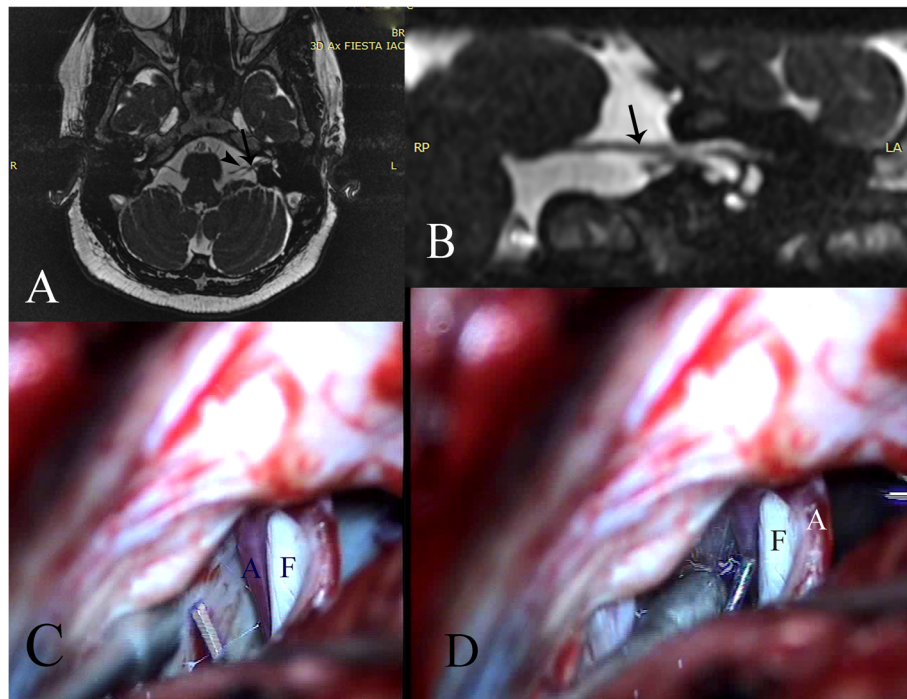


Fig. 3 **a** FIESTA showing vascular compression on the facial nerve (left side). *Arrow* points to the facial nerve, *arrowhead* points to the vascular loop. **b** Processed image where *arrow* points to the vascular loop. **c, d** Microscopic view showing the vascular loop compressing the facial nerve (left side) and is hidden under the suprameatal tubercle. F., facial nerve. A., AICA

the REZ. Instead of going in more retraction which we believe it would be hazardous, we adopted the use of endoscopic inspection for which a minimal retraction ranged from 1.5 to 1.7 cm was enough to visualize structures related to the nerve all around.

In addition to the above-mentioned points, the operating microscope needed to be re-oriented more medially and the operating table needed to be rotated to decrease the distance need for cerebellar retraction. Jonathan and Burchiel, 2017 [17] reported that the offending vessels were adjacent to the entry zone near the brain stem and anterior to the trigeminal nerve. The compressing veins are located at the point of entry into the Meckel’s cave. Therefore, in our work, the endoscope was better than the microscope for visualization of the vessels that are

closer to the entry zone and those located anterior to the nerve and at the Meckel’s cave. Unlike microscopic procedures, endoscopic exploration was done with a minimal average 1.5–1.7 cm retraction. Similarly, the endoscope was better for exploration of the facial nerve, specially at the region of internal acoustic meatus.

The role of endoscopic assistance

In our study, with the use of the endoscope, the range of distance between the petrous bone and the petrosal surface of the cerebellum was approximately 1.5–1.7 cm in 27/30 patients with both TN and HFS (Table 4). Figure 2a, b demonstrates the endoscopic two close up views, showing the region of entry of the trigeminal nerve at the Meckel’s cave and the REZ. Figure 5a,b shows

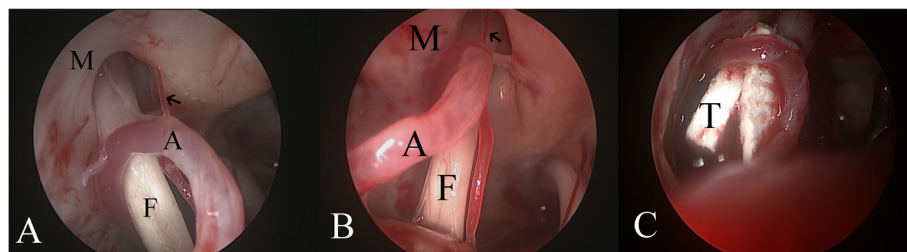


Fig. 4 (a–c) Endoscopic view showing AICA compressing the facial nerve (left side). M., Meatus. A., AICA. F., Facial nerve. T., Teflon. *Arrow* points to the Labyrinthine artery

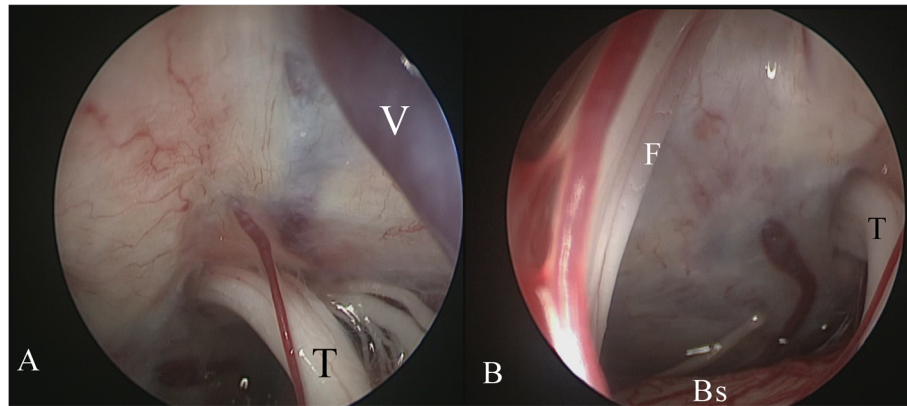


Fig. 5 (a and b) Endoscopic view showing the trigeminal nerve (left side). T, Trigeminal nerve. V, Vein. Bs, brain stem. F., Facial nerve

exploration of the trigeminal nerve in a patient suffering with HFS, confirming that no associated vascular compression on the nerve either at the REZ or the distal portion. The previously mentioned full endoscopic explorations were applied without the need for excessive cerebellar retraction.

Throughout the entire 30 surgeries included in this study, we believe that intraoperative microscopic inspection is not much helpful to visualize vascular structures immediately behind the REZ which need a direct penetrating visualization tool with different viewing angles and rotation ability, typically the endoscope. The microscope alone could visualize all the vessels directly without messing any of them; however, the endoscope was superior in determination of the course of the vessel all around the nerve and confirmation of proper insertion if the Teflon isolate the nerve all around (Figs. 2, 4, and 5).

Rak et al. 2004 [18] could utilize the endoscope for exploration and assisting the operating microscope in visualization and described that as visualization-assisted. He cauterized and divided the trigeminal vein by the endoscope in (6/17–35%) of their patients as it was difficult by the microscope. He described those steps as procedure-assisted. But they did not use the endoscope totally.

On the other hand, Grotenhuis 2001 [19] reported that MVD could be totally done through the endoscope, at the same time, he emphasized the use of microscope preliminarily after retrosigmoid craniectomy and then assessment of adequacy of the procedure using the endoscope. Abdeen et al. 2016 [20] recommended the use of endoscope with microscope in CPA region. The addition of the endoscope enables a wider and more accurate exploration of the REZ. Moreover, lenses with different angles explored different areas. Through the endoscope, confirmation of the proper positioning of the Teflon could be done. However, they reported that through the endoscope, there is a risk of nerve and

vessel injury. The endoscopic image clarity might be reduced, together with the need of easily handled holder for the endoscope. In our work, Figs. 2 and 4c show the Teflon inserted between the nerve and the compressing vessel. We believe the use of the endoscope as a primary role needs a learning curve and availability of lenses with different angles.

Complications

Samii et al. 2002 [11], through pure microscopic MVD, reported that the most common complication was hearing loss in 8.3%, vertigo in 9.6%, and incomplete facial palsy in 2.7%. They attributed that cauterization near the nerve may be the cause. Mclaughlin et al. 1999 [21] reported that 30 of 4400 patients, operated upon along 30 years, had postoperative cerebellar contusion or hemorrhage attributable to retraction. In our work, one of our patients had post-operative cerebellar hemorrhage necessitated urgent evacuation and immediate recovery without sequelae. In patients with HFS, we used intraoperative facial nerve monitoring and therefore, we did not have facial deficit post-operatively. Teo et al. [22] had 2 patients with hearing affection, 9 patients had trigeminal sensory dysfunction, and lastly, wound infection in a patient. Kevin and Kim, 1997 [23] reported a mortality rate after pure microscopic MVD of 1.4%, transient deficits affecting cranial nerves of 4%, lasting up to 6 months and sensory loss of 25%.

In our opinion, factors that lessen the risk of cerebellar injury on top of retraction are the amount of drained CSF, use of propofol during anesthesia, and the duration of retraction. The presence of REZ vessels raises the risk of injury due to excessive retraction over a long time. Mclaughlin et al. 1999 [21] attributed that the cerebellar hemorrhage was the consequence of avulsion of the veins during retraction.

Akinori, 1997 [24] emphasized that the duration of cerebellar retraction of more than 5 min is potentially

hazardous to the hearing function, which occurred in 7.1% in patients who had TN and in 9.1% of patients who had HFS. They based their findings upon intraoperative neuromonitoring. They attributed the unsatisfactory results to hearing loss and partial improvement due to missed vessel identification (7.1 TN and 2.6 HFS). They advised 2 min rest in-between and cerebellar retraction is advised to be perpendicular to the long axis of the cranial nerve. In our work, we primed the role of endoscopic assistance to obviate any undue or hazardous cerebellar retraction.

Conclusion

The advantages of microvascular decompression are still worthy. Cerebellar retraction in less than a pure microscopical intervention. Complications are minimal, view is exceptionally panoramic and focally in depth. Therefore, the endoscope can see what the microscope cannot see; therefore, avoidance of missing vascular compression and non-optimum outcome can be assured.

Abbreviations

CPA: Cerebellopontine angle; FIESTA: Fast imaging employing steady-state acquisition; HFS: Hemifacial spasm; MVD: Microvascular decompression; REZ: Root entry zone; TN: Trigeminal neuralgia

Acknowledgements

The authors appreciate all of the department members of Neurosurgery, Tanta University Hospital, for their help in doing this work.

Authors' contributions

Both authors equally took part in surgical procedures, data gathering, analysis, and writing. Both authors read and approved the final manuscript.

Funding

No funding for that study.

Availability of data and materials

Data are available from the corresponding author on request.

Ethics approval and consent to participate

This study has been approved by the research ethics, Faculty of Medicine, Tanta University (approval code: 33295/8/19), obtained on August, 2019. In addition, being a retrospective study, consents for participation and for publication were not applicable, so the ethics committee waived the consent to participate.

Consent for publication

Not applicable. Figures has no personal information about the patients.

Competing interests

The authors declare that they have no competing interests.

Received: 13 October 2019 Accepted: 17 December 2019

Published online: 03 January 2020

References

1. Sauvain MO, Magistris MR, de Tribolet N. Microvascular decompression of the facial nerve. *Operative Technique in Neurosurgery*. 2001;4(3):127–36.
2. Sepahi AN, Tew JM Jr. Microvascular decompression for treatment of glossopharyngeal neuralgia. *Operative Technique in Neurosurgery*. 2001; 4(3):137–41.
3. Jarrahy R, Eby JB, Cha ST, Shahinian HK. Fully endoscopic vascular decompression of the trigeminal nerve. *Minim Invasive Neurosurg*. 2002; 45:32–5.

4. Lovely TJ, Jannetta PJ. Microvascular decompression for trigeminal neuralgia: surgical technique and long-term results. *Neurosurg Clin N Am*. 1997;8:11–29.
5. Perneczky A, Fries G. Endoscope-assisted brain surgery: Part 1—Evolution, basic concept, and current techniques. *Neurosurgery*. 1998;42:219–25.
6. Greenberg MS. Medical therapy for trigeminal neuralgia. In: *Handbook of Neurosurgery*, Greenberg MS, Thieme Medical Publisher, New York, 2010; 482
7. Mahajan C. Therapeutic Options for Trigeminal Neuralgia. In: Rath GP, editor. *Handbook of trigeminal neuralgia*. Singapore: Springer Nature Singapore Pte Ltd; 2019. p. 46. <https://doi.org/10.1007/978-981-13-2333-1>.
8. Kondziolka DS, Pirris S, Lunsford L. Improving the informed consent process for surgery. *Neurosurg*. 2006;58:1184–9.
9. Chen DQ, Quan J, Guha A, Tymianski M, Mikulis D, Hodaie M. Three-dimensional in vivo modeling of vestibular schwannomas and surrounding cranial nerves with diffusion imaging tractography. *Neurosurgery*. 2011;68:1077–83.
10. El Refaee E, Langner S, Baldauf J, Matthes M, Kirsch M and Schroeder HWS: value of 3-dimensional high-resolution magnetic resonance imaging in detecting the offending vessel in hemifacial spasm: comparison with intraoperative high definition endoscopic visualization. *Neurosurgery*. 2013;73:58–67.
11. Samii M, Günther T, Iaconetta G, Muehling M, Vorkapic P, Samii A. Microvascular decompression to treat hemifacial spasm: long-term results for a consecutive series of 143 patients. *Neurosurgery*. 2002;50:712–9.
12. Sanchez-Mejia RO, Limbo MBA, Cheng J, Camara J, Ward MM, Nicholas BM. Recurrent or refractory trigeminal neuralgia after microvascular decompression, radiofrequency ablation, or radiosurgery. *Neurosurg Focus*. 2005;18(5):E12.
13. Rath SA, Klein HJ, Richter HP. Findings and long-term results of subsequent operations after failed microvascular decompression for trigeminal neuralgia. *Neurosurgery*. 1996;39:933–40.
14. Klun B. Microvascular decompression and partial sensory rhizotomy in the treatment of trigeminal neuralgia: Personal experience with 220 patients. *Neurosurgery*. 1992;30:49–52.
15. Akkaya E, Gokcil Z, Erbas C, Pusat S, Bengisun ZK, Erdogan E. A clinical analysis of microvascular decompression surgery with sacrifice of the superior petrosal venous complex for trigeminal neuralgia: a single-surgeon experience. *Turk Neurosurg*. 2019. <https://doi.org/10.5137/1019-5149.JTN.26555-19.3>.
16. Sindou M, Acevedo G. Microvascular decompression of the facial nerve. *Operative Technique in Neurosurgery*. 2001;4(3):110–26.
17. Jonathan PM, Burchiel KJ. Microvascular decompression for trigeminal neuralgia. In: Youmans JR, editor. *Neurological Surgery*. Philadelphia: W.B. Saunders Co; 2017. p. 1420–6.
18. Rak R, Sekhar L, Stimac D, Hech P. Endoscope-assisted microsurgery for microvascular compression syndromes. *Neurosurgery*. 2004;54:876–83.
19. Grotenhuis JA. The use of endoscope in microvascular decompression surgery. *operative technique in neurosurgery*. 2001;4(3):162–5.
20. Abdeen K, Kato Y, Kiya N, Yoshida K, Kann T. Neuroendoscopy in microvascular decompression for trigeminal neuralgia and hemifacial spasm: technical note. *Neurol Res*. 2000;22:522–6.
21. McLaughlin MR, Jannetta PJ, Clyde BL, Subach BR, Comey CH, Resnick DK. Microvascular decompression of cranial nerves: lessons learned after 4400 operations. *J Neurosurg*. 1999;90:1–8.
22. Teo CH, Nakaji P, Ralph J. Mobbs: Endoscope-assisted microvascular decompression for trigeminal neuralgia: technical case report. *Neurosurgery*. 2006;59(ONS Suppl 4):ONS-489–90.
23. Kevin MR, Kim JB. Surgical management of trigeminal neuralgia. In: Tindall GT, Cooper P, Barrow DL, editors. *The Practice of Neurosurgery*, vol. III, Chapt 202; 1997. p. 3043–64.
24. Kondo A. Follow-up results of microvascular decompression in trigeminal neuralgia and hemifacial spasm: clinical study. *Neurosurgery*. 1997;40:46–52.

Publisher's Note

Springer Nature remains neutral with regard to jurisdictional claims in published maps and institutional affiliations.