

ORIGINAL PAPER

Open Access



3D-surface scan based validated new measurement technique of femoral joint line reconstruction in total knee arthroplasty

Lars-Rene Tuecking¹, Max Ettinger¹, Dennis Nebel², Bastian Welke², Michael Schwarze², Henning Windhagen¹ and Peter Savov^{1*}

Abstract

Purpose: This study aimed to validate a new joint line measurement technique in total knee arthroplasty for separated assessment of the medial and lateral femoral joint line alteration with 3D-surface scan technology. Separate assessment of the medial and lateral joint line alteration may improve TKA alignment assessment regarding to joint line restoration in kinematic alignment and use of robotic-assisted TKA surgery.

Methods: The medial and lateral joint line difference after TKA implantation on an artificial bone model was analyzed and compared with a 3D-scan and full femoral radiographs pre- and postoperatively. Radiographic analysis included the perpendicular distance between the most distal point of the medial and lateral condyle and the reproduced preoperative lateral distal femoral angle (LDFA). For evaluation of validity and reliability, radiographs were captured initially with true anteroposterior view and subsequently with combined flexion and rotation malpositioning. Reliability of the introduced measurement technique in between three observers was tested with intraclass correlation coefficient (ICC).

Results: Radiographic measurement showed a mean difference of 0.9 mm on the medial side and 0.6 mm on the lateral side when compared to the 3D-surface scan measurement. The reliability of measurement accuracy was ≤ 1 mm in x-rays with $< 10^\circ$ flexion error regardless to malrotation in these images. The ICC test showed very good reliability for the medial joint line evaluation and good reliability for lateral joint line evaluation (ICC 0.92, ICC 0.86 respectively).

Conclusion: The new introduced joint line measurement method showed a sufficient reliability, accuracy and precision. It provides separated information about medial and lateral joint line alteration in TKA surgery in absolute values.

Level of evidence: V - Experimental Study

Keywords: Total knee arthroplasty, Femoral mechanical angle, Kinematic alignment, Joint line, Radiographic assessment

Introduction

Joint line (JL) restoration is known to be an important factor in total knee arthroplasty (TKA). Several studies have already shown that JL alteration has an impact of clinical and functional outcome [1, 3, 4, 7, 21, 25, 27,

34]. A cadaveric study showed that JL elevation of up to 5 mm could lead to significant increase of mid flexion instability [34]. Additional studies found an alteration of maximum range of motion (ROM) and biomechanics of the patella femoral joint if inaccurate restoration of the JL is apparent [7, 17].

Several studies have already been conducted to define reproducible techniques to quantify absolute JL alteration [15–17, 22, 25, 26, 33, 35]. Most frequently used

*Correspondence: peter.savov@diakovere.de

¹ Department of Orthopaedic Surgery, Medical School Hannover, Anna-von-Borries-Str. 1-7, 30625 Hannover, Germany
Full list of author information is available at the end of the article

bony landmarks within these techniques are the adductor tubercle, medial and lateral epicondyle, tip of the fibular head and the tibial tubercle [8, 9, 15, 16, 18, 26, 29, 30]. In recent studies, two principles of JL assessment in native radiographs are used most frequently. The tibial referenced method uses the distance from the tip of the fibula head to the distal femoral joint line [1, 22, 33]. The distance between the level of the adductor tubercle and the distal femoral joint line (ATJL) serves as a femoral referenced method [15, 26]. Both techniques showed good to excellent results for intra- and inter-reliability [1, 15, 16, 30]. The ATJL method provides absolute values of the JL to allow pre- to postoperative JL comparison. Nevertheless, this frequently used method does not allow a differentiation of JL alteration on the medial and lateral side.

Current measurement methods only provide separated measurement methods of the JL height alteration (ATJL height) and alteration of the JL obliquity [11, 12]. The introduced radiographic assessment method in this study combines the assessment of the alteration of the joint line obliquity as well as the absolute joint line height. In addition, the introduced method offers the ability to assess the medial and lateral JL separately. The joint line alteration in the medial and lateral compartment can be expressed in absolute values by this method. This may be particularly beneficial in studies related to kinematic alignment and assessment of knee phenotypes in TKA surgery.

Kinematic alignment aims to restore the native femoral phenotype by reconstruction of the preoperative JL obliquity in addition to the restoration of the JL height itself [19, 24, 27, 28]. The separated determination of postoperative TKA alignment combining JL obliquity and JL height measurement on the medial and lateral side allows a much more detailed postoperative joint line evaluation in knee total arthroplasty research. Complementing this, Hirschmann et al. 2019 introduced the concept of functional knee phenotypes [12] and classified knee phenotypes based on tibial and femoral bony alignment in healthy knee joints [11]. This classification particularly correlates tibial and femoral bony alignment. In these studies, a high variability of knee phenotypes was found in healthy knee joints. Thus, this led to the conclusion that the usual classification of knee joints based only on the overall limb alignment into three groups (varus, valgus, neutral) does not correctly reflect the natural variability of knee joints. Therefore, it is necessary to apply patient-specific alignment philosophies to reconstruct the natural alignment and natural knee phenotype. However, this requires new measurement methods that allow detailed postoperative assessment of the alignment and the femoral phenotype. The separate assessment of the medial and lateral joint line allows a

much more detailed assessment of the postoperative alignment and might be used to combine the assessment of knee phenotypes in line with JL alteration. Additionally, robotic-assisted surgery is used more frequently in knee arthroplasty. Several studies could already show an increased accuracy in TKA alignment with an increased control of femoral bone cuts of the medial and lateral condyles in TKA procedures [2, 31]. Hence, a JL assessment method with separated measurement of the medial and lateral JL might also be beneficial in this context.

This study introduced a new JL measurement technique on long leg radiographs with separated absolute values for medial and lateral joint line alteration. It leads to an accurate evaluation of the success of modern alignment philosophies and precision of robotic assisted TKA.

This study is the first to introduce a JL measurement technique which combines the assessment of JL obliquity and JL height, and offers a separated medial and lateral JL assessment. This technique offers the possibility of a very precise analysis of the postoperative femoral alignment, which has a special value in studies of kinematic alignment or, in the future, in accuracy studies of robotic assisted TKA.

Thus, the purpose of this study is twofold. First of all, this study was performed to validate the measurement technique by the use of a modern 3D-scan technology. Further, the resistance of the new JL measurement technique to typical rotation and extension errors in long leg radiographs was investigated. It was hypothesized that the newly introduced JL measurement is accurate about one mm in the assessment of medial and lateral JL and is resistant to slight misplacement within radiographic imaging.

Material and methods

A femoral artificial bone (SKU: 1103-1, Sawbones Europe, Sweden) was used as a testing model in this radiographic validation study.

Implant positioning

A cruciate retaining femoral component (Size 5, Stryker Triathlon; Stryker, USA) was positioned with kinematic alignment technique using the standard instruments [14]. The medial and lateral bone cuts were symmetrical to reproduce the native anatomy of the femoral model with the implanted femoral component.

Radiographic assessment

Radiographic assessment was conducted pre- and postoperatively with the same test protocol and set-up (see Fig. 1). Simulation of X-ray malpositioning included 5° and 10° flexion error in a.p. views and additional rotational error with 5° internal and 5° external rotation

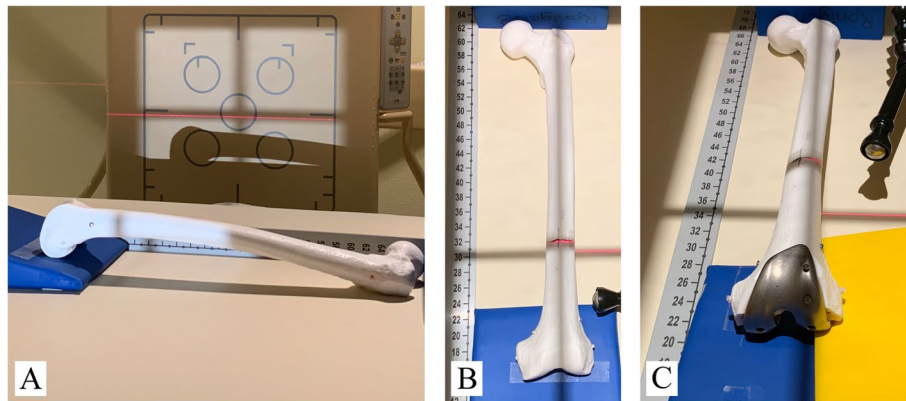


Fig. 1 Experimental setup of radiographic imaging with validation and setup of different error conditions. Flexion error validation in true lateral view **(a)**. A.p. view preoperative with 5° flexion error **(b)**. A.p. view postoperative with internal rotation error **(c)**. Laser is used to verify bone position on X-ray table. Calibration bar and calibration ball for internal validation of distance measurement in PACS software

were added to each neutral a.p. view (see Table 2). The set-up of the flexion error was validated by true lateral views (Fig. 2) and consecutive measurement within the PACS software. A goniometer was used to reproduce and verify internal and external rotation of 5°. The use of radio translucent positioning devices fixed to the X-ray table on defined positions as well as the use of optical positioning aids ensured repeatability of the setup and comparability of pre- and postoperative X-rays. Although the used X-ray machine (DigitalDiagnost Dual Detector, Philips, Netherlands) already provides calibrated images, a calibration ball and

calibration scales were added to every image to confirm the distance calibration.

3D-scan assessment

3D-surface scans were taken pre- and postoperatively. Initially, the testing model was sprayed with matting spray (3D Scanning Mattierungsspray FabConstruct L500, Fabistron GmbH, Zerst, Germany) in order to increase the contrast and to avoid scan artefacts. The artificial bone was then placed on a turntable (HP 3D Automatic Turntable Pro, HP Deutschland GmbH, Böblingen, Germany) of the associated 3D-scanner system (HP


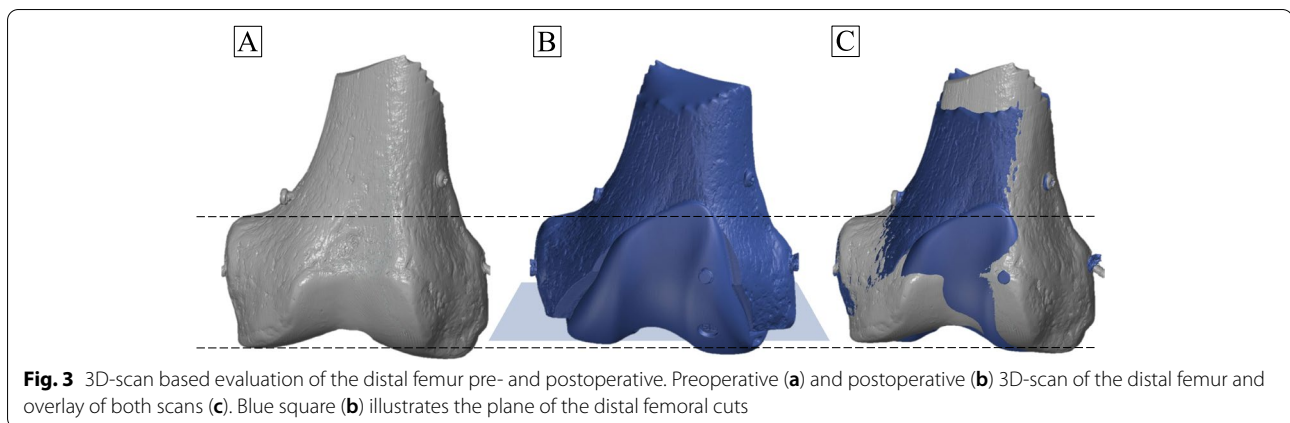


Fig. 2 Experimental setup of radiographic imaging for flexion error. Different flexion error setups with 0° flexion error **(a)**, 5° flexion error **(b)** and 10° flexion error **(c)**. Scale bar used for angle measurement and calibration



3D Structured Light Scanner Pro S3, HP Deutschland GmbH, Böblingen, Germany). After the first 360° scan (increments of 30 degree) the model was repositioned for another scan to detect the whole surface, including the distal joint surface of the femur. The single scan frames were recorded by the scan software (HP 3D Scan Pro 5.6.0.2037 Rev. I (17.01.2019), HP Deutschland GmbH, Böblingen, Germany), which was also used to align the frames and merge them into a 3D object. This resulted in triangulated surface models with around 3.7 million faces and an average edge length of 0.12 mm (Fig. 3). For the 3D analysis the pre- and postoperatively 3D objects were imported into GOM Inspect (GOM Inspect 2019 (2019 Hotfix 3, Rev. 121,775, Build 2019–10–10), GOM GmbH, Braunschweig, Germany). Initially, the two objects were superimposed in GOM by 3-point alignment of reference points and subsequent local best-fit of the unaffected bone surface. Afterwards, a plane perpendicular to the distal femoral bone cuts from the postoperative 3D-object was created. The created plane was used to create a 2D silhouette of the objects. The most distal points on the medial and lateral side of the femur were then selected, as well as the medial adductor tubercle. All measurements were repeated three times by one engineer. The mean value was used for further statistical analysis.

Radiological analysis

For radiological analysis Carestream PACS software V.11 (Carestream, Philips, Netherlands) was used. The preoperative assessment included measurement of the lateral distal femur angle (LDFA) and the perpendicular distance between the medial adductor tubercle and the distal femoral joint line (ATJL, preoperative joint line height) as described before [32]. The preoperative LDFA and ATJL of the reference radiograph (true a.p., neutral rotation) were then reproduced in each postoperative radiograph. Within the postoperative radiograph the perpendicular distance between the most distal point of the medial and

lateral condyle and the reproduced preoperative LDFA (preoperative joint line) served as measurement of the medial joint line difference (mJLD) and lateral joint line difference (lJLD) as shown in Fig. 4. Three independent observers (orthopedic surgeons) carried out the radiological analysis.

Statistical analysis

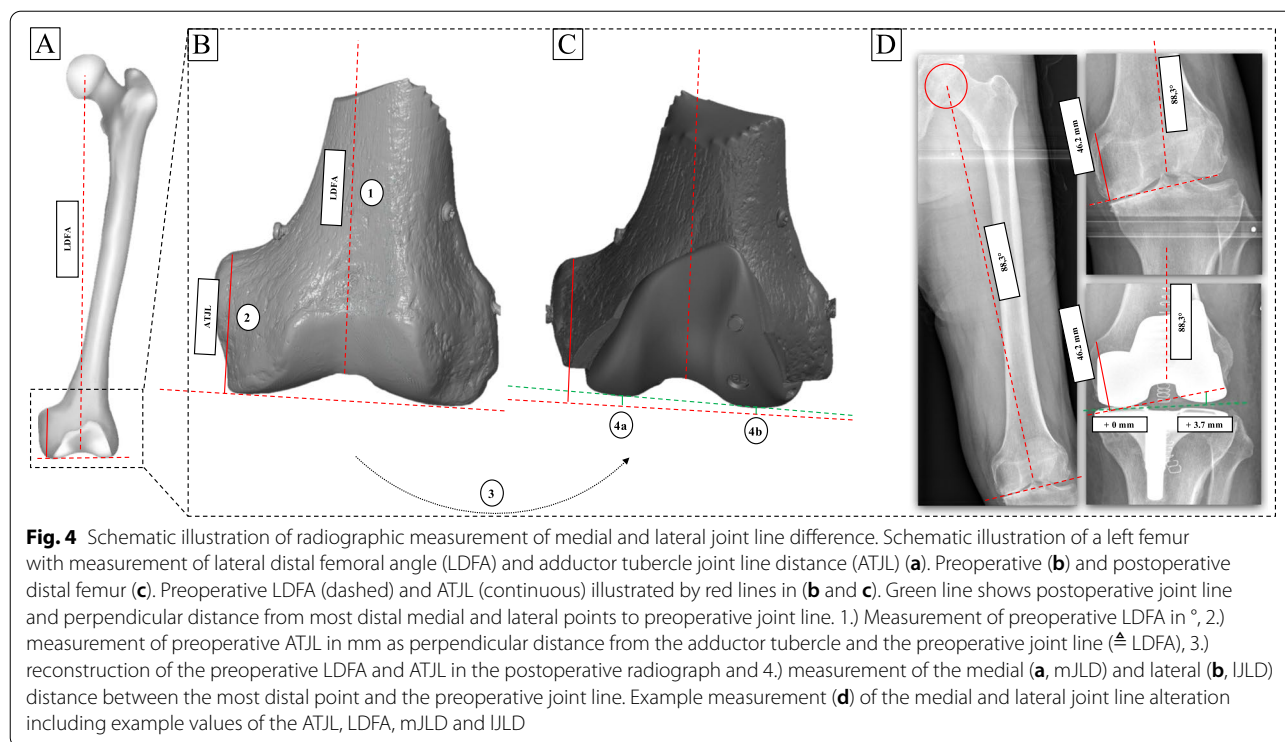
Statistical analysis was performed using the software SPSS v25 (IBM, Armonk, NY, USA) and Microsoft Excel (Microsoft, Washington, USA). Descriptive results are given as mean value, standard deviation, median and minimum and maximum values (Table 1). Accuracy of radiographs with rotation and flexion error were calculated as difference to the reference radiograph (neutral, true a.p.; Table 2). Inter-observer reliability was calculated with the intraclass correlation coefficient (ICC). An ICC value > 0.8 was defined as good reliability, values > 0.9 as very good reliability.

Results

The radiographic measurement technique showed a total mean difference of 0.9 mm on the medial side and 0.60 mm on the lateral side compared to the 3D-surface scan (Table 1). A further proximalisation of the joint line was apparent at both sides when compared to the 3D-surface scan technique.

Radiographic malpositioning influenced the medial and lateral JL evaluation with a range of difference of -0.4 mm to 2.5 mm (medial side) from the reference radiograph, and -0.8 mm to 2.5 mm on the lateral side (Table 3, Fig. 5). The highest deviation from the reference radiograph was found for 10° flexion error with 5° external rotation (medial: 2.5 mm and lateral: 2.5 mm). The difference from the reference radiograph did not exceed ≤ 1 mm on the medial or lateral side if flexion error was kept ≤ 10° (Fig. 5).

Preoperative LDFA ($91.6^\circ \pm 0.2^\circ$) changed by 2.1° to the postoperative LDFA ($93.7^\circ \pm 0.3^\circ$), see Table 2. When



assessing the influence of the malpositioning, the LDFFA difference to the reference were mostly kept $< 1^\circ$ with one exception (postoperative LDFFA with 0° flexion and 5° internal malrotation), which at the same time showed the largest difference to the reference (1.2°).

Within the ATJL assessment, the difference to the neutral radiograph ranged from -0.4 mm to 0.6 mm (preoperative) and from 0.01 mm to 2.3 mm (postoperative). The maximum differences to the neutral positioning were found in the group of 10° flexion and 5° external malpositioning with 0.6 mm (preoperative) and 2.3 mm (preoperative).

Table 1 Comparison of radiographic and 3D-surface scan measurements: JL difference pre- to postoperative

	Mean	SD	Median	Max	Min
Radiographic analysis^a					
Medial JL difference (mm)	-2.2	± 0.1	-2.2	-2.0	-2.3
Lateral JL difference (mm)	-0.4	± 0.3	-0.6	0.5	-0.6
3D Structured Light Scanner analysis					
Medial JL difference (mm)	-1.3	± 0.1	-1.2	-1.2	-1.4
Lateral JL difference (mm)	0.2	± 0.1	0.2	0.3	0.1
Difference in between techniques					
Medial JL difference (mm)	-0.9		-1.0		
Lateral JL difference (mm)	-0.6		-0.8		

LDFFA Lateral distal femoral angle, JL Joint line, SD standard deviation, Max Maximum, Min Minimum, $^\circ 0^\circ$ Flexion without rotation error (reference measurement), negative sign expresses 'proximalisation'

The reliability of the medial joint line difference measurement was proven very good with an ICC of 0.92 and of the lateral joint line a good reliability with an ICC of 0.86.

Discussion

The most important finding of this study is that the newly defined JL assessment method shows a high accuracy with a deviation of ≤ 1 mm from 3D-surface scan measurement. This error is acceptable within the limits of clinical relevance. This JL assessment method provides the possibility of differentiated measurement of medial and lateral JL alteration. Additionally, the validity of this method was proven by resilience against typical malalignments in certain limits during radiograph acquisition. However, an extension deficit of 10° with a combined external malrotation lead to a high deviation of > 2 mm from the reference radiograph. Nevertheless, an external malrotation with an extension deficit of 10° is obvious to the examiner and should lead to consider repetition of the radiographs. Therefore, this limitation of the assessment method is acceptable in clinical and scientific practice.

The aim of kinematic alignment is to exactly restore the natural anatomy and the extension-flexion axis of the femur which includes the restoration of the joint line and its obliquity [6, 19, 24]. No JL assessment method

Table 2 Radiographic measurements of LDFA and ATJL with flexion and rotation error

Flexion and rotation error	Preoperative LDFA (°)	Preop. LDFA diff. to reference (°)	Postoperative LDFA (°)	Postop. LDFA diff. to reference (°)	Preoperative ATJL (mm)	ATJL diff. to reference (mm)	Postoperative ATJL (mm)	Postoperative ATJL diff. to reference (mm)
0° flexion	91.6 (± 0.2)		93.7 (± 0.3)		49.3 (± 0.1)		46.9 (± 0.4)	
0° flexion	92.4 (± 0.3)	0.9 (± 0.3)	94.9 (± 0.3)	1.2 (± 0.2)	48.9 (± 0.3)	-0.4 (± 0.3)	46.9 (± 0.2)	0.0 (± 0.3)
0° flexion	90.7 (± 0.3)	-0.9 (± 0.3)	92.8 (± 0.3)	-0.9 (± 0.1)	49.9 (± 0.9)	0.2 (± 0.2)	47.4 (± 0.1)	0.5 (± 0.4)
5° flexion	91.8 (± 0.2)	0.3 (± 0.2)	93.7 (± 0.1)	0.0 (± 0.2)	49.4 (± 0.3)	0.2 (± 0.4)	47.8 (± 0.1)	0.9 (± 0.3)
5° flexion	91.9 (± 0.1)	0.3 (± 0.1)	93.9 (± 0.1)	0.2 (± 0.1)	49.3 (± 0.6)	0.0 (± 0.6)	48.3 (± 0.2)	1.4 (± 0.2)
5° flexion	91.7 (± 0.7)	0.1 (± 0.5)	93.2 (± 0.2)	-0.5 (± 0.1)	49.8 (± 0.6)	0.5 (± 0.6)	48.1 (± 0.1)	1.2 (± 0.4)
10° flexion	92.3 (± 0.2)	0.7 (± 0.1)	93.8 (± 0.3)	0.1 (± 0.1)	49.5 (± 0.5)	0.2 (± 0.6)	49.1 (± 0.2)	2.2 (± 0.2)
10° flexion	92.1 (± 0.1)	0.5 (± 0.3)	93.5 (± 0.3)	-0.2 (± 0.3)	49.6 (± 0.6)	0.3 (± 0.7)	49.1 (± 0.3)	2.2 (± 0.2)
10° flexion	92.3 (± 0.4)	0.7 (± 0.2)	93.9 (± 0.2)	0.2 (± 0.4)	49.9 (± 0.7)	0.6 (± 0.7)	49.2 (± 0.3)	2.3 (± 0.1)

LDFA Lateral distal femoral angle, JL Joint line, med. medial, lat. lateral, diff. difference, values given in mean (± standard deviation)

Table 3 Radiographic measurements of medial and lateral JL difference with flexion and rotation error

Flexion and rotation error	Medial JL difference (mm)	Lateral JL difference (mm)
0° flexion (reference)	-2.2 (± 0.1)	-0.4 (± 0.3)
+ 5° internal rotation	-2.5 (± 0.2)	0.1 (± 0.2)
+ 5° external rotation	-2.2 (± 0.1)	-1.2 (± 0.4)
5° flexion	-1.5 (± 0.3)	0.0 (± 0.5)
+ 5° internal rotation	-1.5 (± 0.5)	0.4 (± 0.6)
+ 5° external rotation	-1.1 (± 0.1)	0.6 (± 0.6)
10° flexion	-0.8 (± 0.2)	0.6 (± 0.7)
+ 5° internal rotation	-0.8 (± 0.3)	0.3 (± 0.7)
+ 5° external rotation	0.3 (± 0.2)	2.1 (± 0.4)

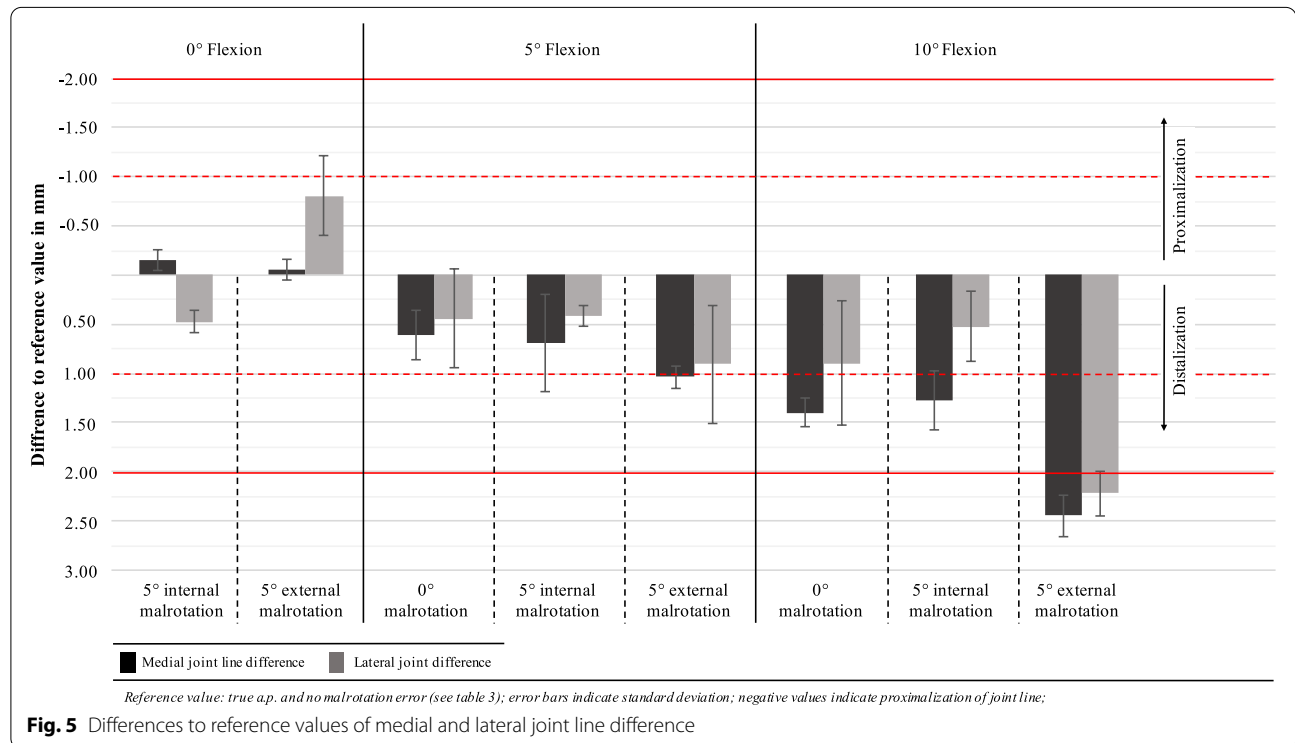
LDFA Lateral distal femoral angle, JL Joint line, med. medial, lat. lateral, diff. difference, values given in mean (± standard deviation)

has yet been described and validated, which differentiate between medial and lateral JL alteration in absolute values. With strict adherence to the kinematic alignment, a symmetrical postoperative medial and lateral JL change should be achieved. In contrast, the treatment of a valgus osteoarthritis with a correction of the overall limb alignment should show a greater distalization of the lateral JL compared to the medial JL. However, an evaluation of the intended targets cannot be made with the current available assessment methods.

Robotic-assisted knee arthroplasty has proven increased alignment accuracy and decreased bone loss [2, 23, 31]. Sires et al. could show an accuracy of bone cuts < 1 mm in 94.3% of the cases performed with an imaged-based robotic system [31]. This suggests that amongst other parameters the control of the medial and lateral JL could be improved by robotic-assisted surgery. Therefore, the analysis of medial and lateral JL alteration might be beneficial for accuracy analysis in robotic-assisted surgery.

Furthermore, there is still a lack of a standardized measurement procedure in TKA. In a systematic review by van Lieshout et al. recent studies with regards to joint line elevation after TKA were analyzed [33]. The majority of the authors rely on three different bony landmarks as a reference point to calculate the joint line height: the fibular head, the tibial tubercle and the adductor tubercle [33]. Several authors already showed that the fibular head is not a reliable bony landmark for JL assessment [9, 15, 30]. In this context, the adductor tubercle seems to show the highest reliability [15, 16, 26]. Therefore, the study group modified an existing assessment method, which is based on femoral landmarks and uses the adductor tubercle as the reference point [1, 13, 20, 32]. Based on the JL measurement technique in unicompartmental knee arthroplasty (UKA), a second reference value was added: the preoperative joint line obliquity [10]. These two factors leads to a differentiate evaluation between the two compartments of the femur.

The accuracy of the proposed method is promising with ≤ 1 mm deviation to a 3D scan. These error



values are within clinical acceptance and get close to the threshold value (1 mm) found in robotic-assisted TKA studies [31].

The ICC shows a good and very good correlation for the radiographic measurement between all examiners. These results are comparable to those, which are published for standard limb alignment on long leg x-rays (ICC = 0.7 to 0.8) [5].

A major problem in examination of radiographs is the varying quality of the images [5]. Especially, the assessment of the mechanical axis in early postoperative long leg radiographs is dependent on the limb loading [36]. In order to test the influence of malposition of patients knee on the described JL assessment method, different common flexion and rotation errors were simulated (Fig. 1 and 2). The results suggest that the limit for the evaluation of x-ray images with this technique is 10° flexion in combination with external rotation or more than 10° of flexion without rotational malpositioning. Furthermore, the difference to the reference radiograph was ≤ 1 mm in x-rays with $< 10^\circ$ flexion error regardless to malrotation in these images (Fig. 5). Thus, the new measuring method described in this study can be used in everyday clinical practice without greater concerns since an extension deficit of more than 10° can obviously be detected in the x-ray image.

This current study has several limitations. All of our findings are based on one saw bone femur model. The adductor tubercle of the saw bone model is less prominent as found in natural bones. In our opinion, the repeated identification of the adductor tubercle in the given x-rays is the most crucial step in this measurement method. This might even have influenced the values of the ICC negatively. In this study, only radiographs of the femoral sawbone taken in the supine position were used, which, of course, cannot accurately represent the appearance of the native femur in weight-bearing images. Nevertheless, it was tried to position the sawbone as natural as possible by comparison with whole-leg radiographs taken in the supine position with the same X-ray unit. Further, the focus of this study was to evaluate and validate the measurement method in comparison to 3D scan technology. Clinical data on a study cohort is missing, due to the focus of this study. Therefore, no conclusion on the clinical effect on different values of medial or lateral joint line alteration is possible.

Conclusion

The new introduced joint line measurement method showed a sufficient reliability, accuracy and precision. It provides separated information about medial and lateral joint line alteration in TKA surgery in absolute values.

Abbreviations

ATJL: Adductor tubercle to joint line distance; a.p.: Anteroposterior; diff.: Difference; Fig.: Figure; ICC: Intraclass correlation coefficient; JL: Joint line; KA: Kinematic alignment; lat.: Lateral; LDFA: Lateral distal femoral angle; IJLD: Lateral joint line difference; med.: Medial; mJLD: Medial joint line difference; ROM: Range of motion; TKA: Total knee arthroplasty.

Authors' contributions

LT, PS, ME and HW planned this study. LT and PS conducted the radiographic analysis and statistical analysis. DN, BW, MS planned and conducted the 3D-scan based analysis. LT, PS, ME and DN drafted the manuscript. All authors read and approved the final manuscript.

Funding

Open Access funding enabled and organized by Projekt DEAL.

Ethics approval and consent to participate

Ethical approval is not required due to the use of artificial bones without harm to patients, patient material or cadavers.

Competing interests

All authors declare that they have no conflict of interest.

Author details

¹ Department of Orthopaedic Surgery, Medical School Hannover, Anna-von-Borries-Str. 1-7, 30625 Hannover, Germany. ² Laboratory for Biomechanics and Biomaterials, Medical School Hannover, Anna-von-Borries-Str. 1-7, 30625 Hannover, Germany.

Received: 18 November 2020 Accepted: 20 January 2021

Published online: 25 February 2021

References

- Babazadeh S, Dowsey MM, Swan JD, Stoney JD, Choong PF (2011) Joint line position correlates with function after primary total knee replacement: a randomised controlled trial comparing conventional and computer-assisted surgery. *J Bone Joint Surg Br* 93:1223–1231
- Bell SW, Anthony I, Jones B, MacLean A, Rowe P, Blyth M (2016) Improved Accuracy of Component Positioning with Robotic-Assisted Unicompartmental Knee Arthroplasty: Data from a Prospective, Randomized Controlled Study. *J Bone Joint Surg Am* 98:627–635
- Bellemans J (2004) Restoring the joint line in revision TKA: does it matter? *Knee* 11:3–5
- Bieger R, Huch K, Kocak S, Jung S, Reichel H, Kappe T (2014) The influence of joint line restoration on the results of revision total knee arthroplasty: comparison between distance and ratio-methods. *Arch Orthop Trauma Surg* 134:537–541
- Boonen B, Kerens B, Schotanus MG, Emans P, Jong B, Kort NP (2016) Inter-observer reliability of measurements performed on digital long-leg standing radiographs and assessment of validity compared to 3D CT-scan. *Knee* 23:20–24
- Eckhoff DG, Bach JM, Spitzer VM, Reinig KD, Bagur MM, Baldini TH et al (2005) Three-dimensional mechanics, kinematics, and morphology of the knee viewed in virtual reality. *J Bone Joint Surg Am* 87(Suppl 2):71–80
- Emodi GJ, Callaghan JJ, Pedersen DR, Brown TD (1999) Posterior cruciate ligament function following total knee arthroplasty: the effect of joint line elevation. *Iowa Orthop J* 19:82–92
- Griffin FM, Math K, Scuderi GR, Insall JN, Poilvache PL (2000) Anatomy of the epicondyles of the distal femur: MRI analysis of normal knees. *J Arthroplasty* 15:354–359
- Havet E, Gabrion A, Leiber-Wackenheim F, Vernois J, Olory B, Mertl P (2007) Radiological study of the knee joint line position measured from the fibular head and proximal tibial landmarks. *SurgRadiolAnat* 29:285–289
- Herry Y, Batailler C, Lording T, Servien E, Neyret P, Lustig S (2017) Improved joint-line restitution in unicompartmental knee arthroplasty using a robotic-assisted surgical technique. *IntOrthop* 41:2265–2271
- Hirschmann MT, Moser LB, Amsler F, Behrend H, Leclercq V, Hess S (2019) Phenotyping the knee in young non-osteoarthritic knees shows a wide

- distribution of femoral and tibial coronal alignment. *Knee Surg Sports TraumatolArthrosc* 27:1385–1393
12. Hirschmann MT, Moser LB, Amsler F, Behrend H, Leclercq V, Hess S (2019) Functional knee phenotypes: a novel classification for phenotyping the coronal lower limb alignment based on the native alignment in young non-osteoarthritic patients. *Knee Surg Sports TraumatolArthrosc* 27:1394–1402
 13. Hofmann AA, Kurtin SM, Lyons S, Tanner AM, Bolognesi MP (2006) Clinical and radiographic analysis of accurate restoration of the joint line in revision total knee arthroplasty. *J Arthroplasty* 21:1154–1162
 14. Howell SM, Kuznik K, Hull ML, Siston RA (2008) Results of an initial experience with custom-fit positioning total knee arthroplasty in a series of 48 patients. *Orthopedics* 31:857–863
 15. Iacono F, Lo Presti M, Bruni D, Raspugli GF, Bignozzi S, Sharma B et al (2013) The adductor tubercle: a reliable landmark for analysing the level of the femorotibial joint line. *Knee Surg Sports TraumatolArthrosc* 21:2725–2729
 16. Iacono F, Raspugli GF, Bruni D, Filardo G, Zaffagnini S, Luetzow WF et al (2014) The adductor tubercle as an important landmark to determine the joint line level in total knee arthroplasty: from radiographs to surgical theatre. *Knee Surg Sports TraumatolArthrosc* 22:3034–3038
 17. Insall J, Goldberg V, Salvati E (1972) Recurrent dislocation and the high-riding patella. *ClinOrthopRelat Res* 88:67–69
 18. Jawhar A, Shah V, Sohoni S, Scharf HP (2013) Joint line changes after primary total knee arthroplasty: navigated versus non-navigated. *Knee Surg Sports TraumatolArthrosc* 21:2355–2362
 19. Ji HM, Han J, Jin DS, Seo H, Won YY (2016) Kinematically aligned TKA can align knee joint line to horizontal. *Knee Surg Sports TraumatolArthrosc* 24:2436–2441
 20. Ji SJ, Zhou YX, Jiang X, Cheng ZY, Wang GZ, Ding H et al (2015) Effect of Joint Line Elevation after Posterior-stabilized and Cruciate-retaining Total Knee Arthroplasty on Clinical Function and Kinematics. *Chin Med J (Engl)* 128:2866–2872
 21. Kawamura H, Bourne RB (2001) Factors affecting range of flexion after total knee arthroplasty. *J OrthopSci* 6:248–252
 22. Kayani B, Konan S, Huq SS, Tahmassebi J, Haddad FS (2019) Robotic-arm assisted total knee arthroplasty has a learning curve of seven cases for integration into the surgical workflow but no learning curve effect for accuracy of implant positioning. *Knee Surg Sports TraumatolArthrosc* 27:1132–1141
 23. Kayani B, Konan S, Pietrzak JRT, Haddad FS (2018) Iatrogenic Bone and Soft Tissue Trauma in Robotic-Arm Assisted Total Knee Arthroplasty Compared With Conventional Jig-Based Total Knee Arthroplasty: A Prospective Cohort Study and Validation of a New Classification System. *J Arthroplasty* 33:2496–2501
 24. Kim JT, Han J, Lim S, Shen QH, Won YY (2019) Kinematically Aligned TKA Aligns the Ankle Joint Line Closer to Those of the Native Ankle than Mechanically Aligned TKA in Bipedal Stance. *J Knee Surg* 32:1033–1038
 25. Liow MH, Xia Z, Wong MK, Tay KJ, Yeo SJ, Chin PL (2014) Robot-assisted total knee arthroplasty accurately restores the joint line and mechanical axis. A prospective randomised study *J Arthroplasty* 29:2373–2377
 26. Luyckx T, Beckers L, Colyn W, Vandenuecker H, Bellemans J (2014) The adductor ratio: a new tool for joint line reconstruction in revision TKA. *Knee Surg Sports TraumatolArthrosc* 22:3028–3033
 27. Luyckx T, Vandenuecker H, Ing LS, Vereecke E, Ing AV, Victor J (2018) Raising the Joint Line in TKA is Associated With Mid-flexion Laxity: A Study in Cadaver Knees. *ClinOrthopRelat Res* 476:601–611
 28. Ng CK, Chen JY, Yeh JZY, Ho JPY, Merican AM, Yeo SJ (2018) Distal Femoral Rotation Correlates With Proximal Tibial Joint Line Obliquity: A Consideration for Kinematic Total Knee Arthroplasty. *J Arthroplasty* 33:1936–1944
 29. Romero J, Seifert B, Reinhardt O, Ziegler O, Kessler O (2010) A useful radiologic method for preoperative joint-line determination in revision total knee arthroplasty. *ClinOrthopRelat Res* 468:1279–1283
 30. Servien E, Viskontas D, Giuffrè BM, Coolican MR, Parker DA (2008) Reliability of bony landmarks for restoration of the joint line in revision knee arthroplasty. *Knee Surg Sports TraumatolArthrosc* 16:263–269
 31. Sires JD, Craik JD, Wilson CJ (2019) Accuracy of Bone Resection in MAKO Total Knee Robotic-Assisted Surgery. *J Knee Surg*; <https://doi.org/10.1055/s-0039-1700570>
 32. van Lieshout WAM, Duijnisveld BJ, Koenraadt KLM, Elmans L, Kerkhoffs G, van Geenen RCI (2019) Adequate joint line restoration and good preliminary clinical outcomes after total knee arthroplasty using the Flexion First Balancer technique. *Knee* 26:794–802
 33. van Lieshout WAM, Valkering KP, Koenraadt KLM, van Etten-Jamaludin FS, Kerkhoffs G, van Geenen RCI (2019) The negative effect of joint line elevation after total knee arthroplasty on outcome. *Knee Surg Sports TraumatolArthrosc* 27:1477–1486
 34. Wyss TF, Schuster AJ, Münger P, Pfluger D, Wehrli U (2006) Does total knee joint replacement with the soft tissue balancing surgical technique maintain the natural joint line? *Arch Orthop Trauma Surg* 126:480–486
 35. Yang JH, Seo JG, Moon YW, Kim MH (2009) Joint line changes after navigation-assisted mobile-bearing TKA. *Orthopedics* 32:35–39
 36. Zahn RK, Renner L, Perka C, Hommel H (2019) Weight-bearing radiography depends on limb loading. *Knee Surg Sports TraumatolArthrosc* 27:1470–1476

Publisher's Note

Springer Nature remains neutral with regard to jurisdictional claims in published maps and institutional affiliations.

Submit your manuscript to a SpringerOpen® journal and benefit from:

- Convenient online submission
- Rigorous peer review
- Open access: articles freely available online
- High visibility within the field
- Retaining the copyright to your article

Submit your next manuscript at ► [springeropen.com](https://www.springeropen.com)