

CASE REPORT

Open Access

# Severe thrombocytopenia after trastuzumab retreatment: a case report

Maria Simona Pino\*, Catia Angiolini and Luisa Fioretto

## Abstract

**Background:** Trastuzumab prolongs survival of human epidermal growth factor receptor 2-positive breast cancer patients in both the adjuvant and metastatic settings. Currently toxicity data are not available on retreatment of metastatic breast cancer patients who relapse after adjuvant trastuzumab. We report one patient with metastatic breast cancer who developed acute thrombocytopenia after trastuzumab infusion. This patient had trastuzumab treatment in the adjuvant setting.

**Case presentation:** A 70-year-old Caucasian woman received a diagnosis of metastatic breast cancer four years after her initial diagnosis of locally advanced, hormone receptors-positive, human epidermal growth factor receptor 2-positive breast cancer. Trastuzumab retreatment was planned. Less than 24 hours after trastuzumab infusion, the patient was admitted to the hospital for the appearance of diffuse petechial hemorrhages and ecchymosis. The patient was confirmed to have a severe trastuzumab-induced thrombocytopenia. A rapid and complete recovery was observed after high-dose intravenous corticosteroids and immunoglobulin. No trastuzumab retreatment was attempted.

**Conclusion:** Among the reported cases of trastuzumab-induced thrombocytopenia, this is the first report in the literature occurring in a patient retreated with trastuzumab after adjuvant therapy.

**Keywords:** Trastuzumab, Breast cancer, Thrombocytopenia

## Background

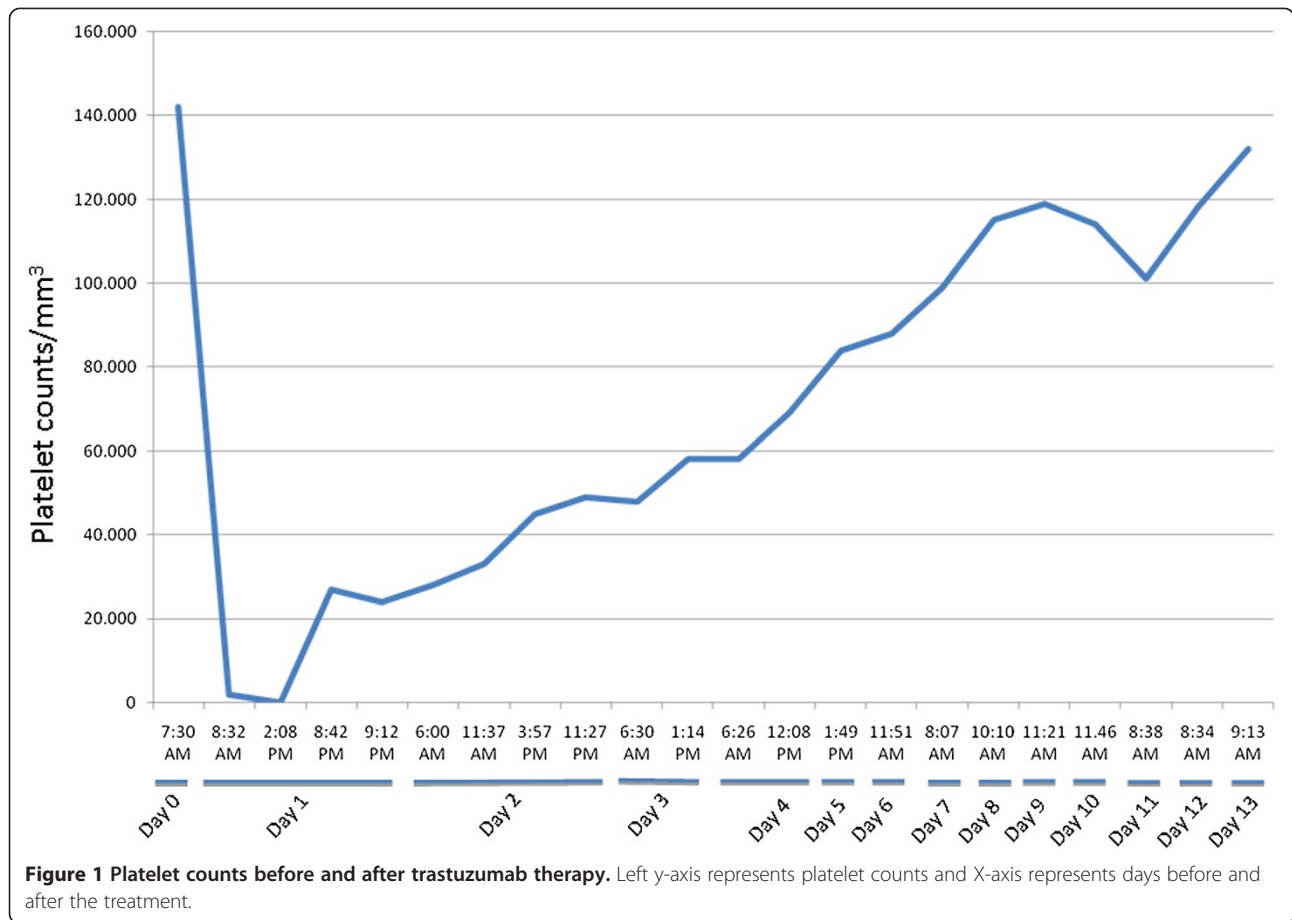
Trastuzumab is a humanized monoclonal antibody directed against the human epidermal growth factor receptor 2 (HER2). The combination of trastuzumab with chemotherapy has been shown to improve survival in both the metastatic and adjuvant settings [1-5]. Myelosuppression is rare and generally mild after trastuzumab treatment [6,7]. Nevertheless, five cases of trastuzumab-related thrombocytopenia have been reported to date [8-12]. In four cases a quick and sustained recovery of platelet count after high-dose intravenous corticosteroids and immunoglobulin was observed. Yet, a patient manifested a chronic evolution of thrombocytopenia, with refractoriness to immunosuppressive treatment. Among the reported cases of trastuzumab-induced severe thrombocytopenia, only one patient, in the adjuvant setting, did not interrupt trastuzumab. Currently, no toxicity data are available on retreatment with trastuzumab after relapse

following adjuvant trastuzumab. Here, we describe a case of acute thrombocytopenia in one patient with metastatic breast cancer, which received trastuzumab several years after its adjuvant use.

## Case presentation

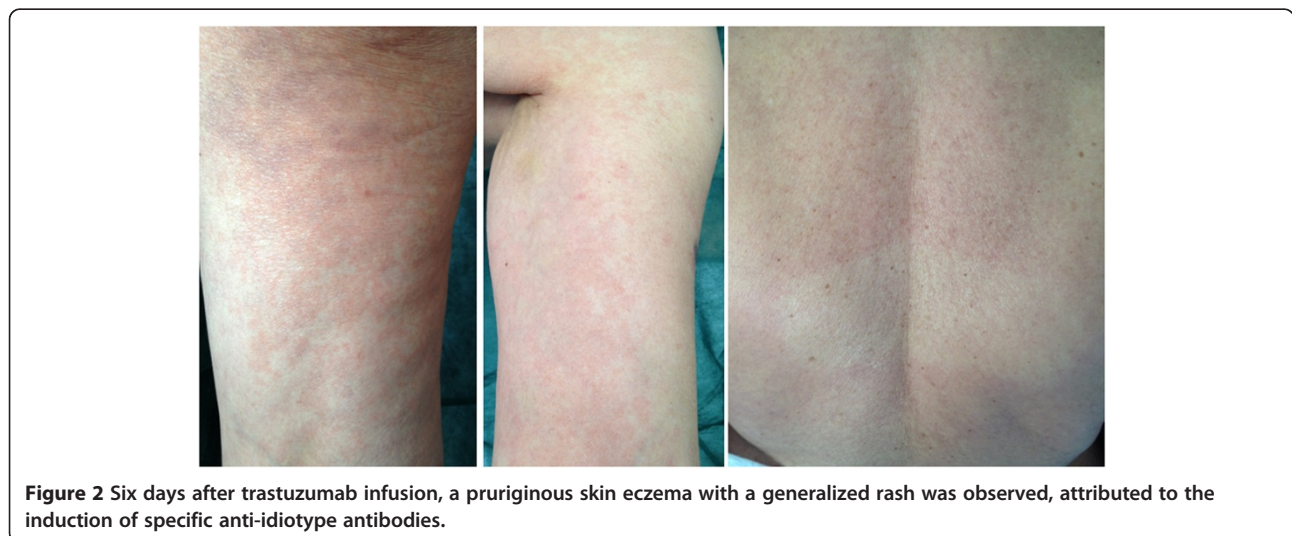A 70-year-old Caucasian woman was diagnosed with locally advanced hormone receptors-positive, HER2-positive breast cancer in 2008. She received neoadjuvant chemotherapy with a sequential anthracyclines-taxane regimen, surgery and radiotherapy. After surgery the patient received adjuvant anastrozole and trastuzumab, as per the HERceptin Adjuvant (HERA) trial [2]. Follow-up was negative until July 2012 when imaging demonstrated an extended bone relapse. A second line treatment with trastuzumab and oral vinorelbine was planned. The day of her loading dose (8 mg/kg of trastuzumab) full blood count was within normal limits Figure 1. She did not receive any heparin (either as treatment or flush), and the infusion of trastuzumab was uneventful. Less than 24 hours after the infusion, the patient turned to the

\* Correspondence: mariasimona.pino@asf.toscana.it  
Department of Oncology, Oncology Unit, Azienda Sanitaria 10 Firenze,  
Florence, Italy



emergency room for the appearance of diffuse petechial hemorrhages and ecchymosis on the lower extremities, lips and buccal mucosa. She was afebrile and cardiovascularly stable. The platelet count was 2000/mm<sup>3</sup>, with normal hemoglobin and leukocyte count, and negligible routine biochemistry and clotting. After 6 hours from

admittance, platelet count was 0/mm<sup>3</sup>. High-dose immune globulin (1 g per kilogram given intravenously in 24 hours, for 5 days), methylprednisolone (1 g per kilogram given intravenously for 7 days), and platelet transfusions were administered. The patient's prior medical history was unremarkable. Other causes of



thrombocytopenia were excluded due to her normal clotting, D-dimers, immunoglobulins, renal function, bilirubin and lactate dehydrogenase as well as lack of schistocytes on blood smear and normal activity of the disintegrin and metalloproteinase with a thrombospondin type 1 motif, member 13 (ADAMTS-13). After 12 hours from admittance the platelet count started recovering. Six days after receiving trastuzumab, a pruriginous skin eczema with generalized rashes was observed, attributed to the induction of specific anti-idiotypic antibodies Figure 2. The rash resolved spontaneously within 48 hours. The patient was discharged by day 13 with low dose oral prednisone. No trastuzumab retreatment was attempted.

## Conclusions

Diagnosis of drug-induced immune thrombocytopenia is usually made by exclusion. In our case, based on the clinical criteria and level of evidence elaborated by George and colleagues, the causative relationship was considered probable [13]. Indeed, treatment with trastuzumab preceded thrombocytopenia, recovery was completed and sustained after its discontinuation, and other causes of thrombocytopenia were excluded. We hypothesize that thrombocytopenia was related to preexisting drug-specific antibodies recognizing murine component of chimeric Fab fragment specific for platelet membrane glycoprotein IIIa. Clearance of the antibody-coated platelets by the mononuclear phagocytic system would be the ultimate cause of the severe thrombocytopenia. On the basis of our observation, trastuzumab retreatment calls for prudence.

## Consent

Written informed consent was obtained from the patient for publication of this Case Report and any accompanying images. A copy of the written consent is available for review by the Editor-in-Chief of this journal.

## Abbreviations

HER2: Human epidermal growth factor receptor 2; HERA: HERceptin adjuvant trial; ADAMTS: A disintegrin and metalloproteinase with thrombospondin motifs.

## Competing interests

The authors declare that they have no competing interests.

## Authors' contributions

Conception: MSP, CA, LF; Manuscript writing: MSP; Final approval: MSP, CA, LF; Patient's management: CA; All authors read and approved the final manuscript.

Received: 3 June 2013 Accepted: 1 October 2013

Published: 4 October 2013

## References

1. Perez EA, Romond EH, Suman VJ, Jeong JH, Davidson NE, Geyer CE Jr, Martino S, Mamounas EP, Kaufman PA, Wolmark N: **Four-year follow-up of trastuzumab plus adjuvant chemotherapy for operable human epidermal growth factor receptor 2-positive breast cancer: joint analysis of data from NCCTG N9831 and NSABP B-31.** *J Clin Oncol* 2011, **29**:3366–3373.

- Gianni L, Dafni U, Gelber RD, Azambuja E, Muehlbauer S, Goldhirsch A, Untch M, Smith I, Baselga J, Jackisch C, Cameron D, Mano M, Pedrini JL, Veronesi A, Mendiola C, Pluzanska A, Semiglazov V, Vrdoljak E, Eckart MJ, Shen Z, Skiadopoulos G, Procter M, Pritchard KI, Piccart-Gebhart MJ, Bell R, Herceptin Adjuvant (HERA) Trial Study Team: **Treatment with trastuzumab for 1 year after adjuvant chemotherapy in patients with HER2-positive early breast cancer: a 4-year follow-up of a randomised controlled trial.** *Lancet Oncol* 2011, **12**:236–244.
- Slamon D, Eiermann W, Robert N, Pienkowski T, Martin M, Press M, Mackey J, Glaspy J, Chan A, Pawlicki M, Pinter T, Valero V, Liu MC, Sauter G, von Minckwitz G, Visco F, Bee V, Buysse M, Bendahmane B, Tabah-Fisch I, Lindsay MA, Riva A, Crown J, Breast Cancer International Research Group: **Adjuvant trastuzumab in HER2-positive breast cancer.** *N Engl J Med* 2011, **365**:1273–1283.
- Joensuu H, Bono P, Kataja V, Alanko T, Kokko R, Asola R, Utraiainen T, Turpeenniemi-Hujanen T, Jyrkkio S, Møykkynen K, Helle L, Ingalsuo S, Pajunen M, Huusko M, Salminen T, Auvinen P, Leinonen H, Leinonen M, Isola J, Kellokumpu-Lehtinen PL: **Fluorouracil, epirubicin, and cyclophosphamide with either docetaxel or vinorelbine, with or without trastuzumab, as adjuvant treatments of breast cancer: final results of the FinHer Trial.** *J Clin Oncol* 2009, **27**:5685–5692.
- Slamon DJ, Leyland-Jones B, Shak S, Fuchs H, Paton V, Bajamonde A, Fleming T, Eiermann W, Wolter J, Pegram M, Baselga J, Norton L: **Use of chemotherapy plus a monoclonal antibody against HER2 for metastatic breast cancer that overexpresses HER2.** *N Engl J Med* 2001, **344**:783–792.
- Baselga J, Carbonell X, Castañeda-Soto NJ, Clemens M, Green M, Harvey V, Morales S, Barton C, Ghahramani P: **Phase II study of efficacy, safety, and pharmacokinetics of trastuzumab monotherapy administered on a 3-weekly schedule.** *J Clin Oncol* 2005, **23**:2162–2171.
- Hudis CA: **Trastuzumab-mechanism of action and use in clinical practice.** *N Engl J Med* 2007, **357**:39–51.
- Mantzourani M, Gogas H, Katsandris A, Meletis J: **Severe thrombocytopenia related to trastuzumab infusion.** *Med Sci Monit* 2011, **17**:CS85–CS87.
- Drudi F, Gianni L, Fantini M, Ravaioli A: **Trastuzumab-related thrombocytopenia: always a self-limiting complication?** *Ann Oncol* 2010, **21**:668–669.
- Jara Sánchez C, Olier Gárate C, García-Donas Jiménez J, Peñalver Párraga J: **Drug-induced thrombocytopenia induced by trastuzumab: a special challenge in a curable disease.** *Ann Oncol* 2009, **20**:1607–1608.
- Parikh O, Neave F, Palmieri C: **Severe thrombocytopenia induced by a single infusion of trastuzumab.** *Clin Breast Cancer* 2008, **8**:285–286.
- Cathomas R, Goldhirsch A, von Moos R: **Drugs-induced immune thrombocytopenia.** *N Engl J Med* 2007, **357**:1870–1871.
- George JN, Raskob GE, Shah SR, Rizvi MA, Hamilton SA, Osborne S, Vondracek T: **Drug-induced thrombocytopenia: a systematic review of published case reports.** *Ann Intern Med* 1998, **129**:886–890.

doi:10.1186/1756-0500-6-400

Cite this article as: Pino et al.: Severe thrombocytopenia after trastuzumab retreatment: a case report. *BMC Research Notes* 2013 **6**:400.

Submit your next manuscript to BioMed Central and take full advantage of:

- Convenient online submission
- Thorough peer review
- No space constraints or color figure charges
- Immediate publication on acceptance
- Inclusion in PubMed, CAS, Scopus and Google Scholar
- Research which is freely available for redistribution

Submit your manuscript at  
www.biomedcentral.com/submit

