Clin Transl Imaging (2013) 1:123–134
DOI 10.1007/s40336-013-0015-1

REVIEW ARTICLE

Diagnostic accuracy of ^{18}F-fluoride PET and PET/CT in patients with bone metastases: a systematic review and meta-analysis update

Ukihide Tateishi · Satoshi Morita · Tomio Inoue

Received: 14 November 2012 / Accepted: 1 March 2013 / Published online: 21 March 2013

Abstract This article was conducted to review the diagnostic performance of ^{18}F-fluoride PET or PET/CT compared with planar bone scintigraphy (BS) or planar BS plus SPECT with ^{99m}Tc-labeled methylene diphosphonate in evaluating patients with metastatic bone tumor, updating a previous meta-analysis on this topic. We performed an updated meta-analysis of all available studies addressing the diagnostic accuracy of ^{18}F-fluoride PET, ^{18}F-fluoride PET/CT, planar BS, and planar BS plus SPECT for detecting metastatic bone tumor. The Medline (from 1966 to November, 2012), SCOPUS, and Biological Abstracts databases were searched using a search algorithm based on combinations of the terms: (1) ^{18}F-fluoride, ^{18}F- fluoride PET, or ^{18}F-fluoride PET/CT, (2) bone scintigraphy, (3) bone metastasis, metastatic bone tumor, without language restriction. We constructed summary receiver operating characteristic curves using hierarchical regression models. Effective dose and cost-effectiveness, estimated from the data of the enrolled studies, were also compared between ^{18}F-fluoride PET or PET/CT and planar BS or planar BS plus SPECT. Comparison of all the studies with data on ^{18}F-fluoride PET or PET/CT showed sensitivity and specificity values of 91.9- and 97.1 % on patient-based analyses and 83.3 and 86.8 % on lesion-based analyses. The Az values of ^{18}F-fluoride PET or PET/CT were 0.987 on a patient basis and 0.894 on a lesion basis, whereas those of BS or BS plus SPECT were 0.867 on a patient basis and 0.854 on a lesion basis. However, ^{18}F-fluoride PET or PET/CT showed poorer estimated effective dose and average cost-effectiveness ratio when compared with the values recorded for planar BS or planar BS plus SPECT. ^{18}F-fluoride PET or PET/CT showed excellent diagnostic performance for the detection of metastatic bone tumor, but the estimated effective dose and the average cost-effectiveness ratio were poorer than the values recorded with planar BS or planar BS plus SPECT. The question of whether there is an incremental diagnostic improvement with ^{18}F-fluoride PET or PET/CT for bone metastasis should be addressed, as should the issues of radiation dose, cost-effectiveness, and potential complications against the yield of information.

Keywords ^{18}F-fluoride · PET · PET/CT · Meta-analysis · Bone metastasis · NaF

U. Tateishi (✉) · T. Inoue
Department of Radiology, Yokohama City University Graduate School of Medicine, 3-9, Fukuura, Kanazawa-ku, Yokohama, Kanagawa 236-0004, Japan
e-mail: u_tateishi@yahoo.co.jp; utateish@yokohama-cu.ac.jp

S. Morita
Department of Clinical Statistics, Yokohama City University Graduate School of Medicine, Yokohama, Japan

Introduction

Bone metastases

The presence of bone metastases is an important prognostic factor in patients with cancer because bone is a common site of distant metastases in patients with advanced stage disease. Bone metastases cause much of the morbidity and disability in patients with cancer despite recent advances in treatment regimens. Proper evaluation of bone metastases and early detection of occult bone metastases are essential for correct treatment decisions and improved outcome.

Imaging diagnosis

The extent of physiological impairment associated with bone metastases does not necessarily correlate with the

degree of morphological changes identified by imaging; that is, some patients with extensive bone metastases may be asymptomatic, whereas others with focal bone destruction evident on roentgenogram may have significant physiological impairment. The roentgenogram is useful for detection of focal lesions with bone destruction or fracture; however, it is inadequate for screening for diffuse bone metastases in clinical practice [1]. In patients presenting an increased risk of focal metastases on physical examination, particularly those with poor performance status, additional studies are usually required. The CT scan is more sensitive and specific than the roentgenogram for the detection of focal bone metastases [1]. It is used mainly for the early recognition of bone metastases with destruction or asymptomatic fracture in at-risk individuals, thereby precluding the necessity for surgical procedure to treat for activity of daily living and to identify unexplained bone lesion.

Bone scintigraphy (BS) using ^{99m}Tc-labeled methylene diphosphonate (^{99m}Tc-MDP) and magnetic resonance imaging (MRI) plays an important role in detecting occult bone metastases that are missed by physical examination. However, the sensitivity of BS alone is not satisfactory because of the technique's limited spatial resolution [1]. Single-photon emission computed tomography (SPECT) helps to clarify equivocal cases identified on BS. It has been proposed that in patients with poor performance status, BS has a lower sensitivity for detecting bone metastases when compared with whole-body MRI with diffusion-weighted sequences. Although the diagnostic accuracy of whole-body MRI with diffusion-weighted sequences is desirable to detect metastatic bone tumor, this technique is available only for limited clinical studies to detect occult bone metastases [2].

^{18}F-FDG PET/CT

Fluorine-18-fluorodeoxyglucose (^{18}F-FDG) positron emission tomography (PET) has been shown to be substantially more accurate than conventional imaging for assessing bone metastases in advanced cancer [1]. Although PET has proved to be an effective tool in the management of advanced cancer, it provides limited information on morphological abnormalities in bone. The presence of four different types of bone metastasis: lytic/lucent, blastic/sclerotic, mixed, and without any morphological abnormalities, often complicates the assessment of bone metastases. Accurately co-registered functional and morphological data sets are generated by integrated PET/CT imaging systems, and these combined functional and morphological systems have given promising results in terms of diagnosis of skeletal metastases. However, despite the increasing use of integrated PET/CT in the management of advanced cancer, the clinical utility of combined assessment of ^{18}F-FDG avidity and morphological changes in bone metastases of advanced cancer has not been fully elucidated.

^{18}F-FDG PET/MRI

The recent introduction of integrated whole-body PET/MRI has given us a new metabolic-anatomical imaging technique for application in clinical practice [3–5]. PET/MRI seems to be highly accurate in detecting bone metastases for which MRI has traditionally been favored. By adding functional MRI to PET data, PET/MRI may further improve diagnostic accuracy in the differentiation between malignant and benign lesions. This hypothesis will have to be assessed in future studies through comparison with the results of conventional imaging. With regard to large bone metastases, PET/MRI does not seem to offer a considerable benefit over PET/CT, although it provides a new whole-body staging method [3]. Small bone metastases or bone marrow metastases can be easily detected by integrated whole-body PET/MRI [5]. Involvement of bone marrow in patients with hematological malignancies will also be assessed in future studies.

^{18}F-fluoride definition

^{18}F-fluoride is a molecular imaging agent used to identify new bone formation. In this environment, the deposition of ^{18}F-fluoride as fluoroapatite in blastic and lytic/lucent lesions, which is due to the fact that ^{18}F-fluoride ion exchanges with hydroxyl groups in hydroxyapatite crystal, reflects increased blood flow and bone turnover [6]. This tracer was approved by the U.S. Food and Drug Administration (FDA) in 1972. However, it was subsequently listed in the Orange Book for continued drug products by the FDA. ^{18}F-fluoride is manufactured and distributed by authorized user prescription under state pharmacy laws. The combination of ^{18}F-fluoride and PET/CT allows cross-sectional functional and anatomical imaging for diagnosis of bone metastases, because PET/CT can include the entire body from the top of the head to the toes.

Possible clinical indications

^{18}F-fluoride PET or PET/CT can be widely used to identify skeletal lesions other than metastases, and can localize and determine the extent of disease. There are many possible indications for ^{18}F-fluoride PET or PET/CT because sufficient information exists to recommend the following situations: back pain and otherwise unexplained bone pain, child abuse, osteomyelitis, trauma, inflammatory and degenerative arthritis, avascular necrosis, osteonecrosis of the mandible, condylar hyperplasia, metabolic bone

disease, Paget disease, bone graft viability, complications of prosthetic joints, reflex sympathetic dystrophy or complex regional pain syndrome I and II, evaluation of the distribution of osteoblastic activity before administration of therapeutic radiopharmaceuticals for bone pain, atherosclerosis, and hyperostosis and osseous involvement of meningioma [6–25].

^{18}F-fluoride PET or PET/CT in the detection of bone metastases

^{18}F-fluoride PET has shown favorable overall accuracy in the detection of bone metastases using pathology as the reference standard [26]. It has been suggested that ^{18}F-fluoride PET might be more accurate than BS in identifying bone metastases because it is considered to have greater spatial resolution [26–30]. The increasing use of integrated PET/CT reveals that this modality is useful for the purpose of detecting bone metastases, because it can provide information on ^{18}F-fluoride avidity and morphological changes in lesions [26–30]. Therefore, when compared with conventional imaging, ^{18}F-fluoride PET or PET/CT is considered to show a more accurate diagnostic performance in detecting bone metastases. However, results of previous studies have limited external validity: several studies were inconclusive because they had small sample sizes, compared various combinations of imaging modalities, and used a variety of methods for determining the diagnostic performance of ^{18}F-fluoride PET or PET/CT.

Procedure/specification of ^{18}F-fluoride PET or PET/CT study

Preparation and precautions

Examinations should be avoided in pregnant women, unless the potential benefits outweigh the radiation risk to the mother and fetus [26]. Prior to the clinical study, patients should be well hydrated to promote rapid excretion of the radiopharmaceutical, to decrease radiation dose, and to improve image quality [27]. Intense tracer activity in the urinary bladder degrades image quality and can confound interpretation of findings in the pelvis. Hydration and a loop diuretic, without or with bladder catheterization, may be used to reduce accumulated urinary tracer activity in the bladder. Patients should drink two or more 224-mL glasses of water within 1 h before the examination, and another two or more 224-mL glasses of water after administration of ^{18}F-fluoride, according to the SNM guideline [26]. Patients do not need to fast and may take their usual medications. The impact of treatments such as chemotherapy and radiotherapy on the uptake of ^{18}F-fluoride is yet to be determined.

Accreditation of PET or PET/CT scanners and determination of the data acquisition protocol

The Core Laboratory should be used to determine whether PET or PET/CT data are acquired under appropriate conditions and whether appropriate QC is implemented for the scanner. To ascertain the validity of the acquisition protocol and image reconstruction parameters, phantom experiments should be conducted in compliance with the aforementioned guideline [26]. The items investigated include (1) scanner manufacturer and model type, (2) frequency and content of QC, (3) availability of FDG, (4) injection method, (5) injected dose, (6) uptake duration, (7) data acquisition mode, (8) scan duration, (9) availability of list mode, (10) image reconstruction method, (11) image reconstruction parameters, (12) history of phantom experiments, and (13) evaluation of phantom experiment results. Body phantoms and ^{18}F-solution have been used in experiments involving acquisition of PET data on a simulated torso of the human body with varying scan duration. The obtained images were both physically and visually evaluated. Phantom background activity concentration is controlled at 2.65 kBq/mL and the hot sphere activity is controlled at four times the background activity. Emission scan duration is 12 min with 3D list-mode acquisition. When the list mode is not available, the default acquisition duration used in the clinical PET/CT examinations is used to acquire the data. The phantom noise equivalent count ($NEC_{phantom}$), visualization of the 10-mm sphere (visual score), image noise (N_{10mm}), % contrast ($Q_{H,10mm}/N_{10mm}$), and relative recovery coefficient (RC) are evaluated.

Imaging protocol

CT may be performed for attenuation correction of emission images and localization of positive lesions. The need for additional diagnostic information should be weighed against the increased radiation exposure from CT. Dose parameters should be consistent with the ALARA (as low as reasonably achievable) principle. Emission images of the axial skeleton may begin as soon as 30–45 min after administration of ^{18}F-fluoride, because of the rapid localization of ^{18}F-fluoride in the skeleton and its rapid clearance from the circulation. High-quality images will be obtained with a start time of 90–120 min for whole-body imaging. Images can be acquired in two- or three-dimensional mode, but the three-dimensional mode is recommended for whole-body imaging because the higher count rates compensate for the shorter acquisition times required for whole-body imaging [26].

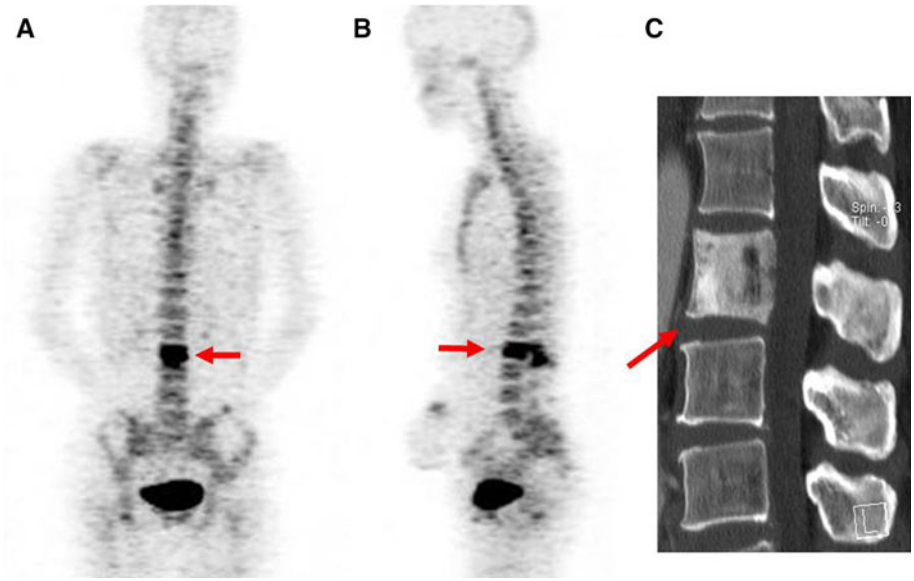

Fig. 1 Typical bone metastasis on ^{18}F-fluoride PET in a patient with breast carcinoma. Focal increased uptake of ^{18}F-fluoride is identified on MIP images (**a**, **b**). Corresponding sagittal CT image shows blastic/sclerotic change (**c**)

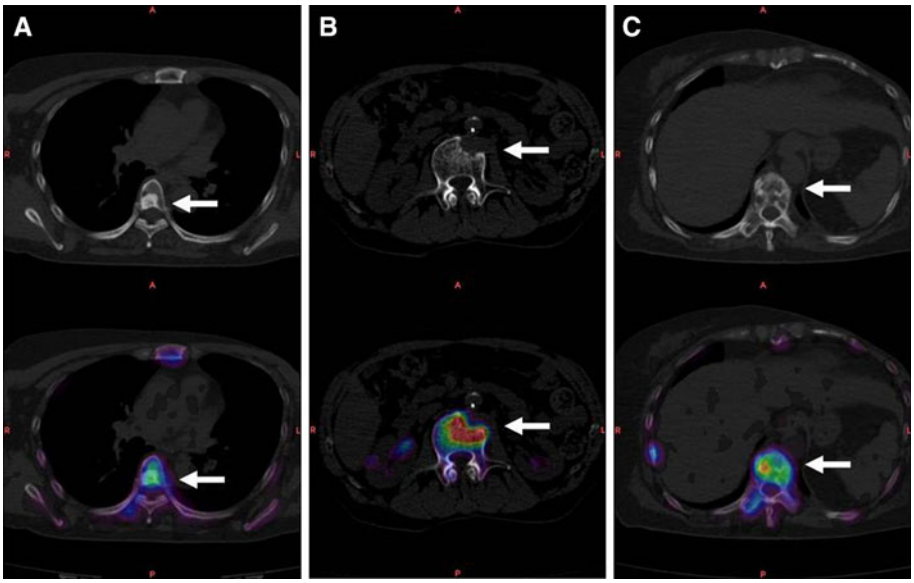

Fig. 2 Morphological classification of bone metastasis based on CT. ^{18}F-fluoride PET/CT shows three patterns of bone metastasis: blastic/sclerotic (**a**), lytic/lucent (**b**), and mixed (**c**)

Acquisition time per bed position will vary depending on the amount of injected radioactivity, decay time, body mass index, and camera factors [6]. Widely used acquisition times are 2–5 min per bed position. Favorable images of the axial skeleton may be obtained with an acquisition time of 3 min/bed position starting 45 min after injection of 185 MBq (5 mCi) of ^{18}F-fluoride. Whole-body images can be obtained with an acquisition time of 3 min/ bed position starting 2 h after injection of 370 MBq (10 mCi) of ^{18}F-fluoride according to the guideline [26]. The optimal number of iterations and subsets, filters, and other reconstruction parameters will depend on patient and camera factors.

Image interpretation criteria

^{18}F-fluoride uptake that is visibly higher or lower than uptake in adjacent bone, or uptake in the corresponding contralateral region, indicates an alteration in bone metabolism (Figs. 1, 2). Physiological accumulation of ^{18}F-fluoride occurs in the entire skeleton, urinary tract, and soft tissues. ^{18}F-fluoride uptake in the skeleton is generally uniform in adults. Normal growth causes increased localization in the metaphyses of children and adolescents. Symmetric uptake between the left and right sides is generally observed in individuals of all ages. Soft-tissue accumulation reflects the amount of circulating ^{18}F-fluoride

Table 1 All data extracted for the meta-analysis

Ref. number	Author	Years	Patients	Age	Inclusion criteria	Design	PET	CT	BS	Definition	Reference standard	Examination
33	Hoh	1993	14	(24–87)	PET	Retrospective	5–10 mCi 60 min	NA	NA	Visual Active ratio	CT/MR/XR/FU	NaF PET
34	Hoegerle	1998	30	51 (13–76)	Suspected metastasis	Prospective	2.7 mCi 90 min	NA	NA	Visual	CT/MR/CR/BS BX	NaF PET
31	Schirrmeister	1999	34	52.3 (37–75)	PET + BS	Prospective	10 mCi 60 min	NA	20 mCi	Visual	CT/MR/XR/FU	NaF PET BS Planar
35	Schirrmeister	1999	44	NA	Known metastasis Suspected metastasis	Retrospective	10 mCi 60 min	NA	20 mCi	Visual	CT/MR/FU/^{131}I-iodine scintigraphy	NaF PET BS Planar
36	Schirrmeister	2001	53	63.2 (43–78) (43–78)	Lung cancer stage IV PET BS/SPECT	Prospective	10–15 mCi 75–180 min	NA	20–27 mCi	Visual	CT/MR/FDG	NaF PET BS Planar BS/SPECT
37	Hetzel	2003	103	62 (38–81)	Lung cancer	Retrospective	7–20 mCi 75–180 min	NA	20–27 mCi	Visual	BS/NaF/MR/FU	NaF PET BS Planar BS/SPECT
38	Even-Sapir	2004	44	52 (15–81)	PET/CT	Retrospective	8–12 mCi 45 min	80 mA, 140 kV, 0.8 s, 6 pitch	NA	Visual	CT/MR/XR/FU BX/PETCT	NaF PET NaF PET/CT
39	Even-Sapir	2006	44	71.6	Prostate carcinoma GS > 8, PSA > 20 CT negative BS/SPECT	Prospective	8–12 mCi 60–90 min	80 mA, 140 kV, 0.8 s, 6 pitch	25 mCi	Visual	CT/FU	NaF PET/CT NaF PET BS Planar BS/SPECT
40	Beheshti	2008	38	69 NA	Prostate carcinoma	Retrospective	10–15 mCi 60 min	80 mA, 140 kV, 0.5 s, ?pitch	NA	Visual	BX/FU/PETCT	NaF PET/CT
41	Iagaru	2009	14	50.4 (19–75)	NA Multicenter	Prospective	10 mCi 60 min	NA		Visual	NA	NaF PET/CT
42	Krüger	2009	58	NA	Lung cancer	Retrospective	10–15 mCi 75–180 min	80 mA, 140kVp, 0.5 s, 1.5pitch	20 mCi	Visual	Imaging	NaF PET BS/SPECT
43	Kawaguchi	2010	7	66 (57–74)	Prostate carcinoma Breast carcinoma HCC	Retrospective	5 mCi 60 min	80 mA, 140kVp, 0.5 s	20 mCi	Visual	CT/MR/FU	NaF PET/CT NaF PET BS Planar
44	Chan SC	2012	80	NA	Head and neck cancer	Retrospective	7 mCi 50 min	NA	NA	Visual	FU/imaging	NaF PET NaF PET/CT

BS bone scintigraphy, *SPECT* single-photon emission computed tomography, *PET* positron emission tomography, *CT* computed tomography, *GS* Gleason score, *PSA* prostate specific antigen, *AC* adjuvant chemotherapy, *NAC* neoadjuvant chemotherapy, *pt* patient, *MR* magnetic resonance imaging, *XR* radiography, *FU* follow-up, *FDG* fluorodeoxyglucose, *BX* biopsy, *NA* not applicable

Table 2 Extracted data based on a patient-by-patient analysis

Ref. number	Author	Year	Patients	Age	Design	Data type	Definition	Examination	TP	FP	TN	FN	EQ
33	Hoh	1993	14	(24–87)	Retrospective	Pt + lesion	Visual	NaF PET	13	0	1	0	0
							Active ratio						
31	Schirrmeister	1999	34	52.3 (37–75)	Prospective	Pt + lesion	Visual	NaF PET	18	0	15	0	1
								BS Planar	13	2	11	3	5
35	Schirrmeister	1999	44	NA	Retrospective	Pt + lesion	Visual	NaF PET	15	0	29	0	0
								BS Planar	13	9	20	2	0
36	Schirrmeister	2001	53	63.2 (43–78)	Prospective	Pt	Visual	NaF PET	11	0	41	0	0
								BS Planar	5	2	35	6	5
								BS/SPECT	9	0	41	1	2
37	Hetzel	2003	103	62 (38–81)	Retrospective	Pt	Visual	NaF PET	30	0	68	2	0
								BS Planar	17	0	13	60	0
								BS/SPECT	20	0	69	4	0
38	Even-Sapir	2004	44	52 (15–81)	Retrospective	Pt + lesion	Visual	NaF PET	23	7	11	3	0
								NaF PET/CT	26	2	16	0	0
39	Even-Sapir	2006	44	71.6	Prospective	Pt + lesion	Visual	NaF PET/CT	20	0	21	0	3
								NaF PET	11	0	13	1	19
								BS Planar	8	10	12	1	13
								BS/SPECT	9	5	14	3	13
41	Iagaru	2009	14	50.4 (19–75)	Prospective	Pt	Visual	NaF PET/CT	7	0	7	0	0
42	Krüger	2009	58	NA	Retrospective	Pt	Visual	NaF PET	17	0	50	1	0
								BS/SPECT	11	0	42	3	2
44	Chan SC	2012	80	NA	Retrospective	Pt + lesion	Visual	NaF PET	13	4	58	5	0
								NaF PET/CT	13	2	60	5	0

BS bone scintigraphy, *SPECT* single-photon emission computed tomography, *PET* positron emission tomography, *CT* computed tomography, *pt* patient, *TP* true positive, *FP* false positive, *TN* true negative, *FN* false negative, *EQ* equivocal, *NA* not applicable

in the blood pool at the time of imaging. Local or regional hyperemia may cause increased visualization of the soft tissues. ^{18}F-fluoride localization in the skeleton is dependent on regional blood flow, as well as on the surface of new bone. ^{18}F-fluoride uptake is higher in new bone (osteoid) because of the higher availability of binding sites [6]. Correlation with skeletal roentgenograms and other anatomical imaging is essential for diagnosis. Asymmetric periarticular ^{18}F-fluoride uptake is observed in subclinical joint disease. ^{18}F-fluoride PET or PET/CT images are assessed for the presence of bone metastases using a five-point grading system. Images are scored from 0 to 4 (0 = definitely negative, 1 = probably negative, 2 = possibly positive, 3 = probably positive and 4 = definitely positive) for each individual lesion [31]. Thus, grade 3 or 4 lesions on PET or PET/CT are considered to be suspected bone metastases. The use of quantitative indices, such as standardized uptake value and kinetic model parameters K1–K4, has not been validated. The clinical relevance of quantitative indices is undefined. Accurate interpretation requires correlation with other information including clinical history, symptoms, prior imaging studies, and other diagnostic tests.

Eligibility of data sources for meta-analysis

Two additional articles have become available for analysis since the publication of our previous meta-analysis study [32]. In this article, we update our previous meta-analysis data. The Medline (from 1966 to November, 2012), SCOPUS, and Biological Abstracts databases were searched using a search algorithm based on combinations of the

Table 3 Extracted data based on a lesion-by-lesion analysis

Ref. number	Author	Year	Patients	Age	Design	Data type	Definition	Examination	TP	FP	TN	FN	EQ	Total numbers
29	Hoh	1993	14	(24–87)	Retrospective	Pt + lesion	Visual Active ratio	NaF PET	43	0	1	0	NA	44
30	Hoegerle	1998	30	51 (13–76)	Prospective	Lesion	Visual	NaF PET	17	4	11	2	0	34
31	Schirrmeister	1999	34	52.3 (37–75)	Prospective	Pt + lesion	Visual	NaF PET	64	0	96	0	8	168
								BS Planar	29	7	39	2	12	89
32	Schirrmeister	1999	44	NA	Retrospective	Pt + lesion	Visual	NaF PET	45	1	0	60	2	108
								BS Planar	42	3	5	45	13	108
35	Even-Sapir	2004	44	52 (15–81)	Retrospective	Pt + lesion	Visual	NaF PET	80	25	64	31	12	212
								NaF PET/CT	94	3	86	17	12	212
36	Even-Sapir	2006	44	71.6	Prospective	Pt + lesion	Visual	NaF PET/CT	46	0	99	0	11	156
								NaF PET	19	3	78	0	56	156
								BS Planar	13	2	82	35	24	156
								BS/SPECT	12	3	86	22	33	156
37	Beheshti	2008	38	69 NA	Retrospective	Lesion	Visual	NaF PET/CT	116	84	71	35	15	321
40	Kawaguchi	2010	7	66 (57–74)	Retrospective	Pt	Visual	NaF PET/CT	85	0	35	0	1	121
								NaF PET	76	4	27	7	7	121
								BS Planar	35	1	33	44	8	121
41	Chan SC	2012	80	NA	Retrospective	Pt + lesion	Visual	NaF PET	65	16	288	33	0	402
								NaF PET/CT	68	3	302	30	0	403

BS bone scintigraphy, *SPECT* single-photon emission computed tomography, *PET* positron emission tomography, *pt* patient, *TP* true positive, *FP* false positive, *TN* true negative, *FN* false negative, *EQ* equivocal, *NA* not applicable

terms: (1) ^{18}F-fluoride, ^{18}F-fluoride PET, or ^{18}F-fluoride PET/CT, (2) bone scintigraphy, (3) bone metastasis, metastatic bone tumor, without language restriction. Reviewers independently assessed potentially relevant citations for inclusion, and disagreements were resolved by consensus. Articles referenced in the retrieved studies were screened to identify additional studies. The investigators of eligible studies were contacted and asked to provide supplementary data when information relevant to the meta-analysis was missing. We excluded studies with verification bias, including patients with non-solid tumors such as hematological malignancies. Studies assessing by ^{18}F-FDG alone or BS alone, and those not making comparisons with ^{18}F-fluoride, were excluded. Studies using ^{18}F-fluoride PET or PET/CT, or BS for evaluation of status after treatment including recurrence were excluded. Studies that contained patients whose disease was not diagnosed in accordance with the reference standard, regardless of information provided by the author, or who presented concomitant diseases were excluded. We also excluded case reports, case series without precise data descriptions regarding the type and number of patients, and studies without descriptions regarding the definition of positive test results.

Data extraction

The following data were collected: author names, journal, year of publication, country of origin, number of patients, age of patients, inclusion and exclusion criteria, study design, injected dose, imaging camera, imaging technical characteristics and protocol, data type (patient- or lesion-based), number of reviewers who assessed and interpreted the results of the imaging, definition of positive test results (qualitative or quantitative), and reference standard. The number of true-positive, false-positive, true-negative, false-negative, and equivocal findings for each modality were also recorded considering both patient- and lesion-based data. Several studies contained accurate data for ^{18}F-fluoride PET or PET/CT, as well as for BS. Therefore, we also evaluated the accuracy of ^{18}F-fluoride PET or PET/CT, BS and/or BS/SPECT, where these data were available. Imaging modalities other than ^{18}F-fluoride PET or PET/

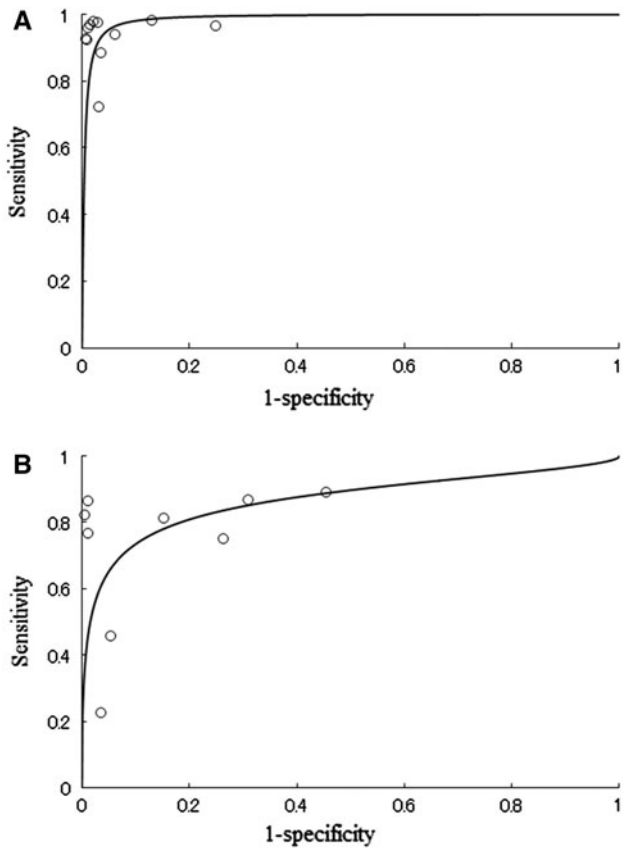

Fig. 3 Summary receiver operating characteristic (SROC) curve for the diagnostic performance of ^{18}F-fluoride PET or PET/CT (**a**) and BS and/or SPECT (**b**) on a patient basis. The *size of the circles* indicates the weight of each study. The area under the SROC curve (Az value) is 0.987 for ^{18}F-fluoride PET or PET/CT and 0.867 for BS and/or SPECT

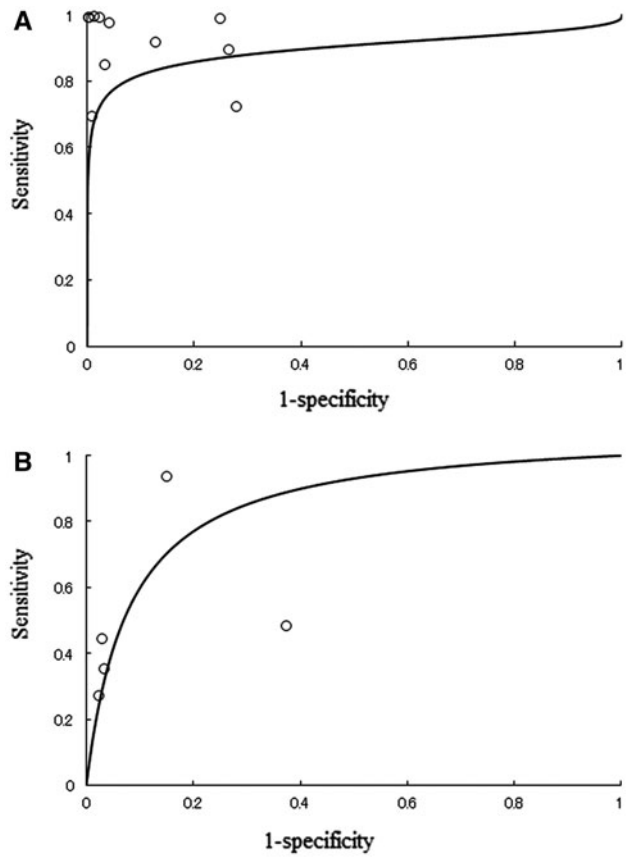

Fig. 4 Summary receiver operating characteristic (SROC) curve for the diagnostic performance of ^{18}F-fluoride PET or PET/CT (**a**) and BS and/or SPECT (**b**) on a lesion basis. The *size of the circles* indicates the weight of each study. The area under the SROC curve (Az value) is 0.894 for ^{18}F-fluoride PET or PET/CT and 0.854 for BS and/or SPECT

CT, BS and/or BS/SPECT were not considered in the statistical analyses.

Results of the meta-analysis

Our literature search yielded 36 articles; 22 were excluded after reading the abstracts because they did not contain any diagnostic information. Thus, 14 articles, representing a total of 563 patients [31, 33–44], were available for our analysis. Of these 14 studies, nine contained patient-based data for planar BS or planar BS plus SPECT and 12 contained patient-based data for ^{18}F-fluoride PET or PET/CT; instead, 5 contained lesion-based data for planar BS or planar BS plus SPECT, and 12 contained lesion-based data for ^{18}F-fluoride PET or PET/CT. A total of 563 patients were included in the patient-based analysis of diagnostic accuracy for detecting metastatic bone tumor, while 335 patients were included in the lesion-based analysis, which included 1,566 lesions evaluated by ^{18}F-fluoride PET and/or PET/CT and 477 lesions evaluated by planar BS or planar BS plus SPECT.

Tables 1, 2 and 3 summarize the data regarding the imaging technical characteristics and inclusion and exclusion criteria. Three of the 14 studies (21 %) were performed using only ^{18}F-fluoride PET or PET/CT without comparison with planar BS or planar BS plus SPECT. Six of the 14 studies (43 %) were stratified by histology of the primary tumor: lung carcinoma in three studies, prostate carcinoma in two, and head and neck cancer in one. Five studies (36 %) stated that they were prospective. All the papers reported that evaluation of the study results had been done in a qualitative manner, whereas one study stated explicitly that evaluation had also been performed by a quantitative method using active ratio of lesion. The reference standard consisted of other imaging studies including CT, MRI, radiography, ^{18}F-FDG PET, clinical follow-up, and biopsy. However, one study did not comment on the reference standard method. The corresponding author of that study was contacted and we were informed that follow-up CT and MRI were used as reference standard.

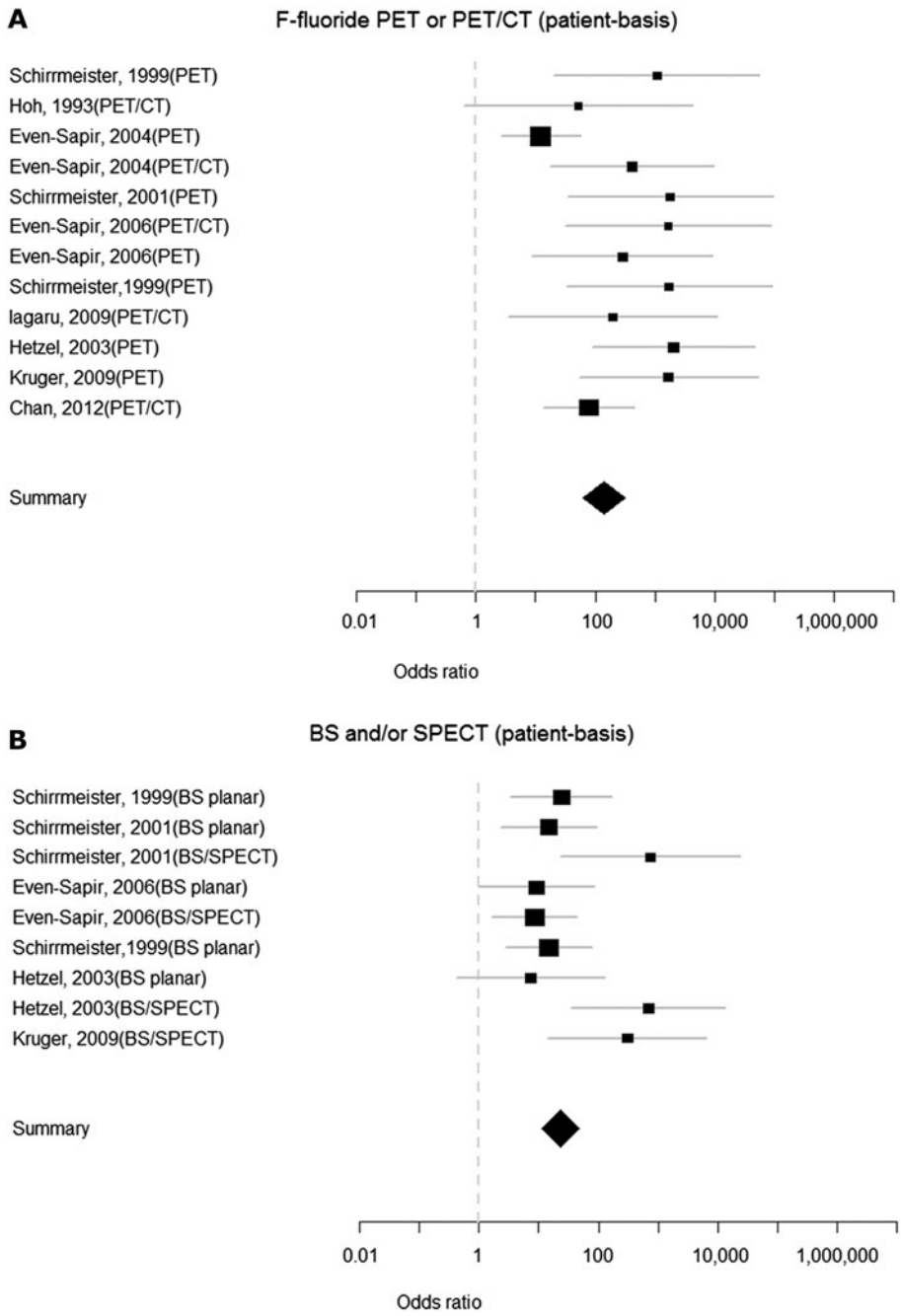

Fig. 5 The Forest plot of diagnostic odds ratio from each study for the diagnostic performance of ^{18}F-fluoride PET or PET/CT (**a**, **b**) and BS and/or SPECT (**c**, **d**). Diagnostic odds ratios were plotted on a logarithmic scale. Diagnostic odds ratio was defined by "(odds of sensitivity)/(odds of (1-specificity))"

Comparison of all the studies with data on ^{18}F-fluoride PET or PET/CT showed sensitivity and specificity values of 91.9 and 97.1 % on a patient basis and 83.3 and 86.8 % on a lesion basis. On the other hand, the sensitivity and specificity of planar BS alone and planar BS plus SPECT were 47.0 and 94.1 % on a patient basis and 55.4 and 91.7 % on a lesion basis. The Az values of ^{18}F-fluoride PET or PET/CT were 0.987 on a patient basis and 0.894 on a lesion basis, whereas those of BS or BS plus SPECT were 0.867 on a patient basis and 0.854 on a lesion basis. The summary receiver operating characteristic curves and the Forest plot of odds ratio showed excellent diagnostic performance of ^{18}F-fluoride PET and combined PET/CT studies on a patient basis and a lesion basis and a considerably good performance in combined BS planar and SPECT studies (Figs. 3, 4, 5).

Radiation safety

Patient radiation doses were estimated for both ^{18}F-fluoride PET or PET/CT and planar BS (and/or SPECT) from the data available in the extracted articles. Effective doses from the

Fig. 5 continued

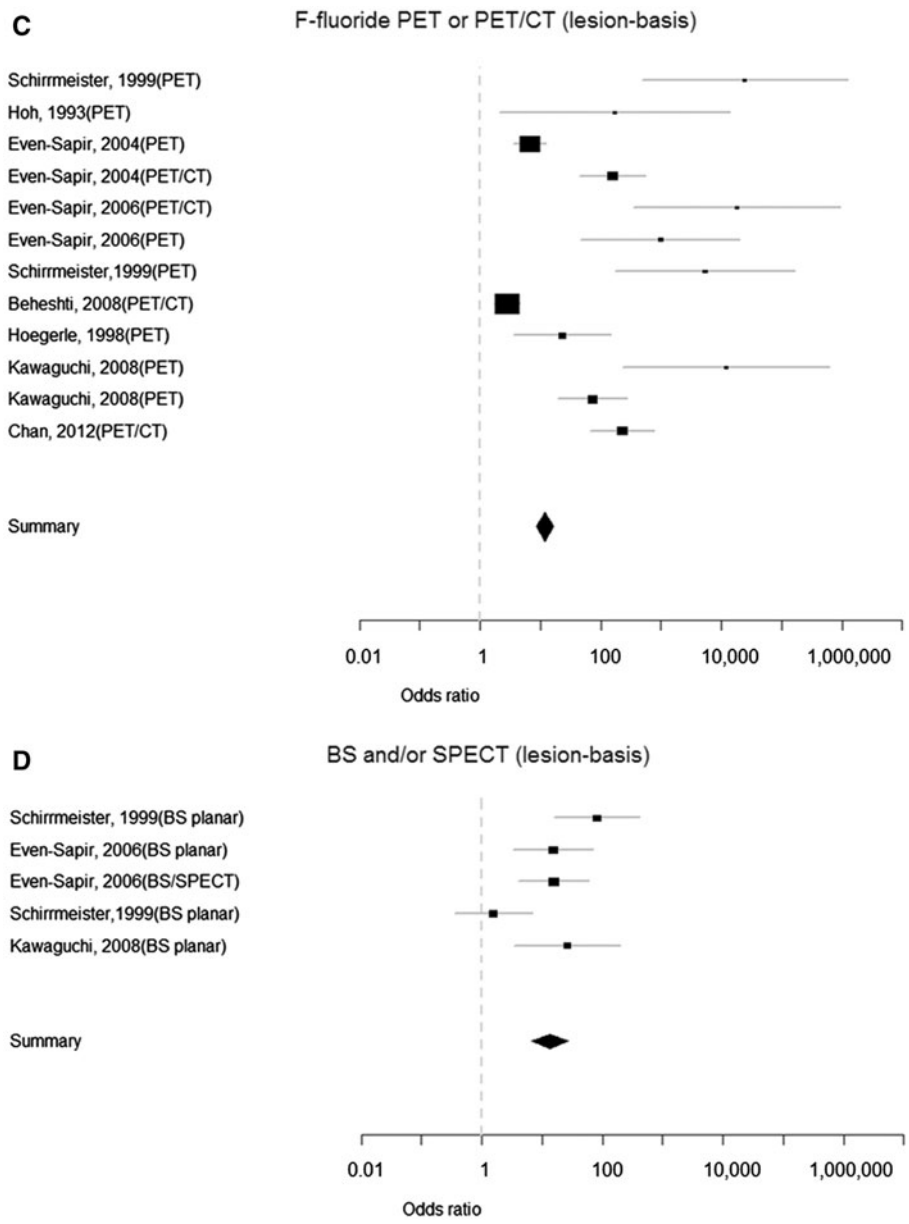

CT portion were calculated using the ImPACT CT patient dosimetry Excel spreadsheet [45]. The effective doses for the head, chest, and abdominal regions were calculated separately and these values were summed to obtain the effective dose for the whole body [46]. Absorbed and effective doses from radiopharmaceuticals in each organ and tissue were obtained from the International Commission on Radiological Protection (ICRP), publication 80 [47].

^{18}F-fluoride is injected intravenously by direct venipuncture or intravenous catheter. The activity for adults is approximately 185–370 MBq (5–10 mCi). Pediatric activity should be weight-based (2.22 MBq/kg [0.06 mCi/kg]), using a range of 18.5–185 MBq (0.5–5 mCi). Therefore, the effective dose for ^{18}F-fluoride is 0.024 mSv/MBq (0.089 mrem/mCi). The literature research revealed that the effective doses from injected ^{18}F-fluoride ranged from 2.7 to 15.0 mSv, whereas these values ranged from 4.2 to 5.7 mSv for BS studies. The effective dose from the CT portion of the PET/CT study ranged from 8.4 to 13 mSv. Therefore, the considerable effective dose of ^{18}F-fluoride PET or PET/CT, as calculated from the included studies, ranged from 2.7 to 28.0 mSv.

Cost-effectiveness

In all the extracted studies, cost-effectiveness was compared between each modality: planar BS and/or SPECT, ^{18}F-fluoride PET, and ^{18}F-fluoride PET/CT. The expected effectiveness was defined as the proportion of correctly diagnosed patients. Direct costs were considered from the

perspective of Japanese and American hospitals. Expected costs were calculated in US$ for 2012, based on the CMS Medicare rates for BS. Since ^{18}F-fluoride is not reimbursed by Japanese insurance and CMS Medicare or private payers in the US, hospital charges for ^{18}F-FDG PET or PET/CT were estimated based on the published ranges of official charges and CPT codes. Average cost-effectiveness ratios were calculated by dividing expected costs by the expected effectiveness, which corresponded to the accuracy of literature studies [32], and expressed in US$ and Euro (EUR) applying the exchange rate as of November 13, 2012. The average cost per study in the US was estimated based on the published ranges of CPT codes. For ^{18}F-fluoride PET or PET/CT, the average cost per study ranged from 1,000 US$ to 1,500 US$. The average cost-effectiveness ratio ranged from 1,038 to 1,558 US$ (1,298 EUR to 1,948 EUR). Similarly, the average cost per study, based on the CMS Medicare rates, was 297 US$ for planar BS or planar BS plus SPECT. The average cost-effectiveness ratio would be 404 US$ (505 EUR) per study for planar BS or planar BS plus SPECT.

Conclusions

This meta-analysis allowed us to investigate how ^{18}F-fluoride PET or PET/CT can contribute to the diagnosis of metastatic bone tumor. Planar BS or planar BS plus SPECT appear to have limited sensitivity but similar specificity to detect metastatic bone tumor both on a patient and on a lesion basis. The question of whether there is an incremental diagnostic improvement with ^{18}F-fluoride PET or PET/CT for bone metastasis needs to be addressed in further studies, as do the issues of radiation dose, cost-effectiveness, and potential complications against the yield of information.

Conflict of interest The authors declare that they have no conflict of interest.

References

1. Ghanem N, Uhl M, Brink I, Schäfer O, Kelly T, Moser E et al (2005) Diagnostic value of MRI in comparison to scintigraphy, PET, MS-CT and PET/CT for the detection of metastases of bone. Eur J Radiol 55:41–55
2. Goudarzi B, Kishimoto R, Komatsu S, Ishikawa H, Yoshikawa K, Kandatsu S et al (2010) Detection of bone metastases using diffusion weighted magnetic resonance imaging: comparison with 11C-methionine PET and bone scintigraphy. Magn Reson Imaging 28:372–379
3. Antoch G, Bockisch A (2009) Combined PET/MRI: a new dimension in whole-body oncology imaging? Eur J Nucl Med Mol Imaging 36:S113–S120
4. Buchbender C, Heusner TA, Lauenstein C et al (2012) Oncologic PET/MRI, part 1: tumor of the brain, head and neck, chest, abdomen, and pelvis. J Nucl Med 53:928–938
5. Buchbender C, Heusner TA, Lauenstein TC et al (2012) Oncologic PET/MRI, part 2: bone tumors, soft-tissue tumors, melanoma, and lymphoma. J Nucl Med 53:1244–1252
6. Grant FD, Fahey FH, Packard AB, Davis RT, Alavi A, Treves ST (2008) Skeletal PET with ^{18}F-fluoride: applying new technology to an old tracer. J Nucl Med 49:68–78
7. Ovadia D, Metser U, Lievshitz G, Yaniv M, Wientroub S, Even-Sapir E (2007) Back pain in adolescents: assessment with integrated ^{18}F-fluoride positron-emission tomography–computed tomography. J Pediatr Orthop 27:90–93
8. Lim R, Fahey FH, Drubach LA, Connolly LP, Treves ST (2007) Early experience with fluorine-18 sodium fluoride bone PET in young patients with back pain. J Pediatr Orthop 227:277–282
9. Fischer DR, Maquieira GJ, Espinosa N et al (2010) Therapeutic impact of [18F]fluoride positron-emission tomography/computed tomography on patients with unclear foot pain. Skeletal Radiol 39:987–997
10. Drubach LA, Sapp MV, Laffin S, Kleinman PK (2008) Fluorine-18 NaF PET imaging of child abuse. Pediatr Radiol 38:776–779
11. Drubach LA, Johnston PR, Newton AW, Perez-Rossello JMP, Grant FD, Kleinman PK (2010) Skeletal trauma in child abuse: detection with ^{18}F-NaF PET. Radiology 255:174–181
12. Dasa V, Adbel-Nabi H, Anders MJ, Mihalko WM (2008) F-18 fluoride positron emission tomography of the hip for osteonecrosis. Clin Orthop Relat Res 466:1081–1086
13. AratakeYoshifumi MT, Takahashi A, Takeuchi R, Inoue T, Saito T (2009) Evaluation of lesion in a spontaneous osteonecrosis of the knee using ^{18}F-fluoride positron emission tomography. Knee Surg Sports Traumatol Arthrosc 17:53–59
14. Raje N, Woo SB, Hande K et al (2008) Clinical, radiographic, and biochemical characterization of multiple myeloma patients with osteonecrosis of the jaw. Clin Cancer Res 14:2387–2395
15. Wilde F, Steinhoff K, Frerich B et al (2009) Positron-emission tomography imaging in the diagnosis of bisphosphonate-related osteonecrosis of the jaw. Oral Surg Oral Med Oral Pathol Oral Radiol Endod 107:412–419
16. Laverick S, Bounds G, Wong WL (2009) [18F]-fluoride positron emission tomography for imaging condylar hyperplasia. Br J Oral Maxillofac Surg 47:196–199
17. Saridin CP, Raijmakers PG, Kloet RW, Tuinzing DB, Becking AG, Lammertsma AA (2009) No signs of metabolic hyperactivity in patients with unilateral condylar hyperactivity: an in vivo positron emission tomography study. J Oral Maxillofac Surg 67:576–581
18. Uchida K, Nakajima H, Miyazaki T et al (2009) Effects of alendronate on bone metabolism in glucocorticoid-induced osteoporosis measured by ^{18}F-fluoride PET: a prospective study. J Nucl Med 50:1808–1814
19. Installe′ J, Nzeusseu A, Bol A, Depresseux G, Devogelaer JP, Lonneux M (2005) (18)F-fluoride PET for monitoring therapeutic response in Paget's disease of bone. J Nucl Med 46:1650–1658
20. Brenner W, Vernon C, Conrad EU, Eary JF (2004) Assessment of the metabolic activity of bone grafts with ^{18}F-fluoride PET. Eur J Nucl Med Mol Imaging 31:1291–1298
21. Temmerman OP, Raijmakers PG, Heyligers IC et al (2008) Bone metabolism after total hip revision surgery with impacted grafting: evaluation using $H_2^{15}O$ and [^{18}F] fluoride PET: a pilot study. Mol Imaging Biol 10:288–293
22. Ullmark G, Sörensen J, Nilsson O (2009) Bone healing of severe acetabular defects after revision arthroplasty. Acta Orthop 80:179–183
23. Dweck MR, Chow MW, Joshi NV, Williams MC, Jones C, Fletcher AM et al (2012) Coronary arterial ^{18}F-sodium fluoride

uptake: a novel marker of plaque biology. J Am Coll Cardiol 59:1539–1548
24. Beheshti M, Saboury B, Mehta NN, Torigian DA, Werner T, Mohler E et al (2011) Detection and global quantification of cardiovascular molecular calcification by fluoro18-fluoride positron emission tomography/computed tomography—a novel concept. Hell J Nucl Med 14:114–120
25. Tateishi U, Tateishi K, Shizukuishi K et al (2013) ^{18}F-fluoride PET/CT allows detection of hyperostosis and osseous involvement in meningioma: initial experience. Clin Nucl Med 38:e125–e131. doi:10.1097/RLU.0b013e318279fd79
26. Segall G, Delbeke D, Stabin MG et al (2010) SNM practice guideline for sodium ^{18}F-fluoride PET/CT bone scans 1.0. J Nucl Med 51:1813–1820
27. Vallabhajosula S (2007) (18)F-labeled positron emission tomographic radiopharmaceuticals in oncology: an overview of radiochemistry and mechanisms of tumor localization. Semin Nucl Med 37:400–419
28. Cook GJ, Fogelman I (2001) Detection of bone metastases in cancer patients by ^{18}F-fluoride and ^{18}F-fluorodeoxyglucose positron emission tomography. Q J Nucl Med 45:47–52
29. Vallabhajosula S (2007) (18)F-labeled positron emission tomographic radiopharmaceuticals in oncology: an overview of radiochemistry and mechanisms of tumor localization. Semin Nucl Med 37:400–419
30. Even-Sapir E, Mishani E, Flusser G, Metser U (2007) ^{18}F-fluoride positron emission tomography and positron emission tomography/computed tomography. Semin Nucl Med 37:462–469
31. Schirrmeister H, Guhlmann A, Kotzerke J, Santjohanser C, Kühn T, Kreienberg R et al (1999) Early detection and accurate description of extent of metastatic bone disease in breast cancer with fluoride ion and positron emission tomography. J Clin Oncol 17:2381–2389
32. Tateishi U, Morita S, Taguri M et al (2010) A meta-analysis of (18)F-fluoride positron emission tomography for assessment of metastatic bone tumor. Ann Nucl Med 24:523–531
33. Hoh CK, Hawkins RA, Dahlbom M et al (1993) Whole body skeletal imaging with [18F]fluoride ion and PET. J Comput Assist Tomogr 17:34–41
34. Hoegerle S, Juengling F, Otte A, Altehoefer C, Moser EA, Nitzsche EU (1998) Combined FDG and [F-18]fluoride whole-body PET: a feasible two-in-one approach to cancer imaging? Radiology 209:253–258
35. Schirrmeister H, Guhlmann A, Elsner K, Kotzerke J, Glatting G, Rentschler M et al (1999) Sensitivity in detecting osseous lesions depends on anatomic localization: planar bone scintigraphy versus ^{18}F PET. J Nucl Med 40:1623–1629
36. Schirrmeister H, Glatting G, Hetzel J, Nüssle K, Arslandemir C, Buck AK et al (2001) Prospective evaluation of the clinical value of planar bone scans, SPECT, and (18)F-labeled NaF PET in newly diagnosed lung cancer. J Nucl Med 42:1800–1804
37. Hetzel M, Arslandemir C, König HH et al (2003) F-18 NaF PET for detection of bone metastases in lung cancer: accuracy, cost-effectiveness, and impact on patient management. J Bone Miner Res 18:2206–2214
38. Even-Sapir E, Metser U, Flusser G, Kollender Y, Lerman H, Lievshitz G et al (2004) Assessment of malignant skeletal disease: initial experience with ^{18}F-fluoride PET/CT and comparison between ^{18}F-fluoride PET and ^{18}F-fluoride PET/CT. J Nucl Med 45:272–278
39. Even-Sapir E, Metser U, Mishani E, Lievshitz G, Lerman H, Leibovitch I (2006) The detection of bone metastases in patients with high-risk prostate cancer: ^{99m}Tc-MDP planar bone scintigraphy, single- and multi-field-of-view SPECT, ^{18}F-fluoride PET, and ^{18}F-fluoride PET/CT. J Nucl Med 47:287–297
40. Beheshti M, Vali R, Waldenberger P, Fitz F, Nader M, Loidl W et al (2008) Detection of bone metastases in patients with prostate cancer by ^{18}F fluorocholine and ^{18}F fluoride PET-CT: a comparative study. Eur J Nucl Med Mol Imaging 35:1766–1774
41. Iagaru A, Mittra E, Yaghoubi SS, Dick DW, Quon A, Goris ML et al (2009) Novel strategy for a cocktail ^{18}F-fluoride and ^{18}F-FDG PET/CT scan for evaluation of malignancy: results of the pilot-phase study. J Nucl Med 50:501–505
42. Krüger S, Buck AK, Mottaghy FM, Hasenkamp E, Pauls S, Schumann C et al (2009) Detection of bone metastases in patients with lung cancer: ^{99m}Tc-MDP planar bone scintigraphy, ^{18}F-fluoride PET or ^{18}F-FDG PET/CT. Eur J Nucl Med Mol Imaging 36:1807–1812
43. Kawaguchi M, Tateishi U, Shizukuishi K, Suzuki A, Inoue T (2010) F-18 fluoride uptake in bone metastasis: morphologic and metabolic analysis on integrated PET/CT. Ann Nucl Med 24:241–247
44. Chan SC, Wang HM, Ng SH, Hsu CL, Lin YJ, Lin CY et al (2012) Utility of ^{18}F-fluoride PET/CT and ^{18}F-FDG PET/CT in the detection of bony metastases in heightened-risk head and neck cancer patients. J Nucl Med 53:1730–1735
45. ImPACT (2004) CT patient dosimetry Excel spreadsheet (version 0.99v, 17 June 2004). http://www.impactscan.org/
46. Jones D, Shrimpton P (1993) NRPB-SR250: Normalised organ doses for X-ray computed tomography calculated using Monte Carlo techniques. National Radiological Protection Board
47. ICRP (1991) 1990 recommendations of the international commission on radiological protection. ICRP PUBLICATION 80. Annals of the ICRP, vol 21, issue no 1–3. Elsevier Science Ltd, Oxford