

(hemoglobin 8.9 g/dL), thrombocytopenia (platelet count, $90 \times 10^9/L$) and raised liver enzymes. Antinuclear antibody (ANA) test was positive (2+); speckled pattern and anti-Ro La was present in high titers in both mother and infant. VDRL of mother and baby was non-reactive. Ultrasound abdomen, electrocardiogram and echocardiography were normal. We diagnosed neonatal lupus erythematosus, and advised tacrolimus 0.03% ointment once daily with strict photo-protection. The patient showed marked improvement in the lesions in the next three months.

Neonatal lupus erythematosus (NLE) is a rare, often misdiagnosed immune-mediated disease. It is usually associated with maternal antibodies to proteins Ro/ La (SSA/SSB) which are transferred by the placenta. Differential diagnoses of NLE include tinea corporis (centrifugal skin lesions with more inflammation at periphery), seborrheic dermatitis (scaly and yellowish round or annular pattern of lesions), congenital syphilis (positive VDRL test), annular erythema of infancy, and aplasia cutis (absence of skin since birth). Congenital heart block and cardiomyopathy are cardiac manifestations of NLE. Management of cutaneous lesions include photo-protection and low-potency topical corticosteroids. Systemic corticosteroids, intravenous immunoglobulins, and immunosuppressive agents have also been tried.

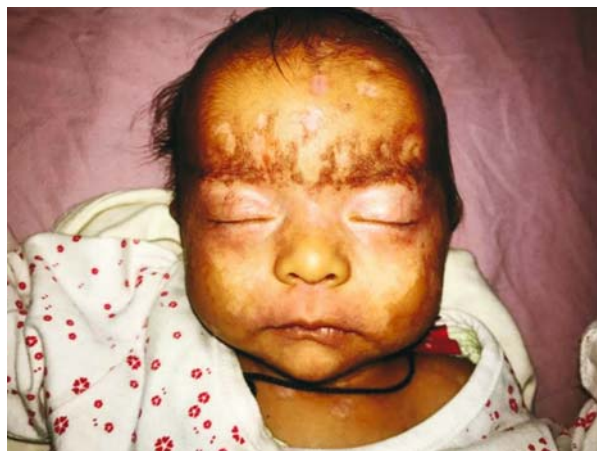


Fig. 1 Multiple depressed, atrophic and hypopigmented plaques on forehead, cheeks, periorbital area and scalp.

Majority of patients with NLE of the skin, liver or blood have transient disease that spontaneously resolves after 4-6 months, but can have substantial morbidity and mortality if there is congenital heart block.

VIBHU MENDIRATTA AND ANUJA YADAV*

*Department of Dermatology and STD,
Lady Hardinge Medical College, New Delhi, India.
anujarao12@gmail.com

BOOK REVIEW



Top 3 Differentials in Pediatric Radiology

REBECCA STEIN-WEXLER

Thieme Publisher, Germany.

Pages: 410; Price: Not mentioned.

Top 3 Differentials in Pediatric Radiology by Rebecca Stein-Wexler is a comprehensive compilation of common and clinically relevant cases encountered in Pediatric Radiology practice. The book is divided into six sections based on imaging of different body systems. A short clinical history is provided with each radiological image to generate an appropriate clinical perspective, followed by description of the salient imaging findings.

The top three imaging differential diagnoses are well discussed, and along with imaging features that justify the diagnosis, a brief description of the classical clinical features and suggested management is also provided. This is followed by the final diagnosis of the case and the

important take away points from the discussion. The description of each case is concise, yet provides all essential and relevant information about the topic under consideration. One caveat is that 'arrows' or other appropriate pointers are often missing from the images and legends, which makes it difficult for reader to spot the radiological findings accurately.

Overall, this book is very well-written, informative, and includes all aspects of Pediatric Radiology in terms of the organ systems and radiological modalities (*i.e.* conventional X-rays, special X-ray investigations, ultrasound, doppler, Computed tomography and Magnetic resonance imaging), simultaneously incorporating cases of varying levels of difficulty. The book will be very beneficial for both Pediatricians and Pediatric Radiologists – residents, teachers as well as practitioners.

NATASHA GUPTA

*Consultant Radiologist,
CNBC Pediatric Hospital and GTB Hospital,
Govt of NCT, Delhi, India.
drnatashagupta@gmail.com*