

Three is a crowd

N. Lahrouchi · E. F. D. Wever · J. C. Balt

Published online: 29 August 2014

© The Author(s) 2014. This article is published with open access at Springerlink.com

Question

A 40-year-old woman was seen at our outpatient clinic because of episodes of palpitations that lasted several hours. She reported no syncopal episodes or family history of sudden cardiac death and was not on any medication. The resting ECG and ECG recorded during

the palpitations are shown in Fig. 1a and b. What is the (differential) diagnosis?

Answer

You will find the answer elsewhere in this issue.

N. Lahrouchi (✉)
Department of Experimental Cardiology, Academic Medical Center,
University of Amsterdam, Meibergdreef 15, Room L2-109, 1105
AZ Amsterdam, the Netherlands
e-mail: n.lahrouchi@amc.uva.nl

E. F. D. Wever · J. C. Balt
Department of Cardiology, St Antonius Hospital, PO Box 2500,
3430 EM Nieuwegein, the Netherlands

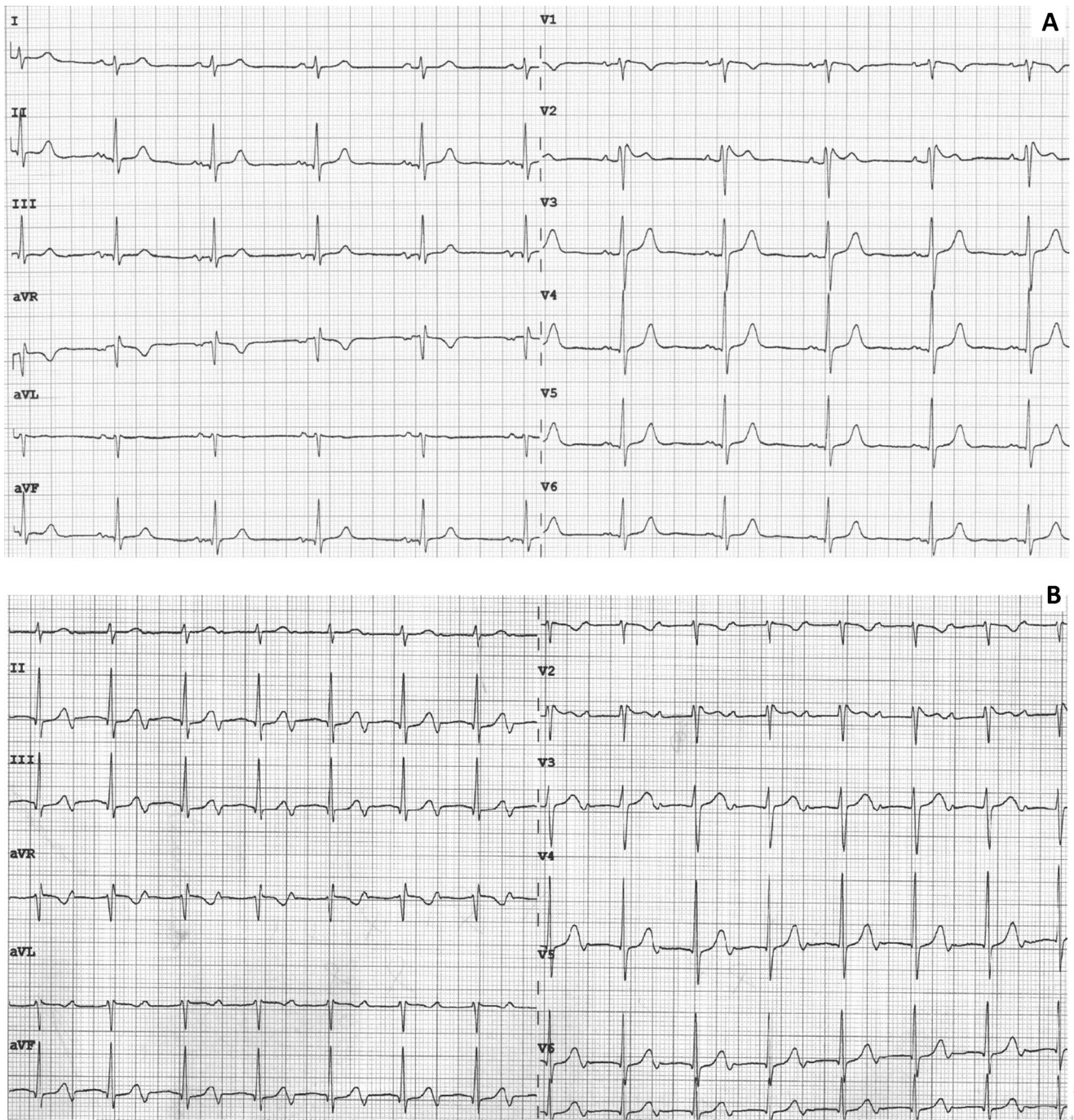


Fig. 1 a ECG at baseline. b ECG during symptoms

Open Access This article is distributed under the terms of the Creative Commons Attribution License which permits any use, distribution, and reproduction in any medium, provided the original author(s) and the source are credited.