

Erratum to: Ventricular pacing site separation by cardiac computed tomography: validation for the prediction of clinical response to cardiac resynchronization therapy

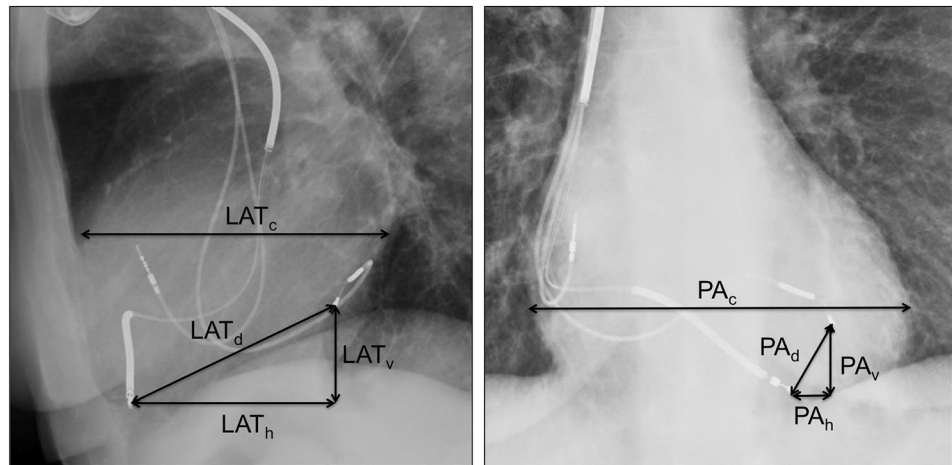
S. Modi¹ · Raymond Yee¹ · David Scholl² · John Stirrat² · Jorge A. Wong¹ · Carmen Lydell^{3,4} · Vamshi Kotha^{3,4} · Lorne J. Gula¹ · Allan C. Skanes¹ · Peter Leong-Sit¹ · David McCarty¹ · Maria Drangova² · James A. White^{3,4}

Published online: 3 May 2017
© Springer Science+Business Media Dordrecht 2017

Erratum to: Int J Cardiovasc Imaging DOI [10.1007/s10554-017-1120-4](https://doi.org/10.1007/s10554-017-1120-4)

The original publication contained an incorrect Fig. 2. The correct Fig. 2 is shown here.

Fig. 2 Fluoroscopic assessment of inter-lead separation—(*left*) lateral chest X-ray showing lateral cardiac size (LAT_c), vertical separation (LAT_v), horizontal separation (LAT_h) and direct lead tip separation (LAT_d); (*right*) PA chest X-ray showing PA cardiac size (PA_c), vertical separation (PA_v), horizontal separation (PA_h) and direct leadtip separation (PA_d)



The online version of the original article can be found under doi:[10.1007/s10554-017-1120-4](https://doi.org/10.1007/s10554-017-1120-4).

✉ James A. White
jawhit@ucalgary.ca

- ¹ Division of Cardiology, Schulich School of Medicine & Dentistry, London, Canada
- ² Robarts Research Institute, University of Western Ontario, London, Canada
- ³ Stephenson Cardiac Imaging Centre, Libin Cardiovascular Institute, Calgary, AB, Canada
- ⁴ Department of Diagnostic Imaging, University of Calgary, Calgary, AB, Canada