

Avishalom Sharon · Ron Auslander ·  
Orly Brandes-Klein · Zvi Alter ·  
Yuval Kaufman · Arie Lissak

## Cystoscopy after total or subtotal laparoscopic hysterectomy: the value of a routine procedure

Received: 27 June 2005 / Accepted: 29 November 2005 / Published online: 3 March 2006  
© Springer-Verlag Berlin / Heidelberg 2006

**Abstract** Ureteral injury during hysterectomy is one of the most troubling complications gynecologists need to be aware of. In various studies, such injury occurred in laparotomy, laparoscopy, and vaginal hysterectomy. The objective of our study was to assess the necessity, efficiency, and cost-effectiveness of cystoscopy at the end of total or subtotal laparoscopic hysterectomy (TLH/STLH). This is a retrospective analysis of 7 years' experience in a university-affiliated hospital. All hysterectomies were performed on an overnight basis by experienced surgeons. Out of 338 patients, 106 patients underwent TLH, and 232 underwent STLH. Four cases (1.18%) of ureter injury were noted (one after TLH and three after STLH). Diagnosis was clinically made by postoperative vaginal sonography and was confirmed by intravenous pyelography. A cystoscopy was performed after intravenous indigo carmine injection. The study period consisted of two phases. In the first phase, we used bipolar cautery to occlude the uterine artery; consequently, a nearby thermal injury could be misdiagnosed. In the second phase we clipped the uterine artery with a new hemoclip called Hem-o-lok (Weck Closure Systems, USA), which forced an exact uterine artery closure. As a result, in the second phase no cases of ureteral injury were noted. In view of the fact that the equipment for cystoscopy is used during surgery for TLH/STLH and is sterile and available, the only additional cost of the cystoscopy is an ampule of indigo carmine. Therefore, we conclude that

cystoscopy at the end of surgery for TLH/STLH is an important evaluation and provides the following significant advantages: In patients presenting with postoperative flank pain, cystoscopy may prevent the need for further evaluation and expensive testing, and cystoscopy increases the surgeon's and the patient's confidence in the integrity of the urinary tract during the recovery period.

**Keywords** Laparoscopic hysterectomy · Ureteral injury · Cystoscopy

### Introduction

One of the most troublesome problems in gynecological surgeries for hysterectomy is the potential occurrence of ureteral or bladder injury. Seventy-five percent of ureteral injuries occur during gynecological procedures, especially hysterectomies, while the rest occur during other abdominal operations [1]. The injuries in gynecology have been noted to occur after total or subtotal hysterectomy by laparotomy (TAH/STAH), after laparoscopic total or subtotal hysterectomy (TLH/STLH), and after laparoscopically-assisted vaginal hysterectomy (LAVH) or vaginal hysterectomy (VH). The injury has also been recorded after ovarian or endometriosis operations; 85% of cases occurred during dissection of the cervix. According to the literature, the rate for such injuries resulting from hysterectomy by laparotomy is 0.03–2% [2–4], is less in VH [2–5], and is up to 3.8% in LAVH [6].

Anatomically, the uterine artery passes anteriorly and above the ureter at the level of the cervix and in the cardinal ligament. Ureteral injury during laparoscopy is typically caused by either partial or complete transection, by thermal injury, by kinking with a nearby suture, or by stapler. Most injuries involve the lower 3 cm of the ureter and are usually unilateral. Injury to the ureter during laparoscopy can also occur unexpectedly during a difficult (e.g., malignancy, adhesions) or careless surgery. Thus, the objective of our study was to assess the necessity, efficacy, and cost-effectiveness of a routine cystoscopy after laparoscopic

A. Sharon (✉) · R. Auslander · O. Brandes-Klein ·  
Z. Alter · Y. Kaufman · A. Lissak  
Department of Obstetrics and Gynecology,  
Gynecoendoscopic Unit, Carmel Medical Center,  
7th Michal Street,  
34362 Haifa, Israel  
e-mail: drsharon@bezeqint.net  
Tel.: +972-4-8250336  
Fax: +972-4-8213258

A. Sharon · R. Auslander · O. Brandes-Klein ·  
Z. Alter · Y. Kaufman · A. Lissak  
Rapaport School of Medicine,  
Technion-Israel Institute of Technology,  
Haifa, Israel

hysterectomy. We examined the data for both total and subtotal laparoscopic hysterectomies.

## Materials and methods

A retrospective analysis of 480 women during a 7-year period from January 1998 to August 2004 was performed. The indications for hysterectomy were either benign or malignant uterine diseases (Table 1). The following patients were not included in the study: those with a uterus larger than 16 weeks, those with pelvic inflammatory disease, and those with contraindications to laparoscopy due to anesthetic high risk (ASA 4). Preoperative evaluation included history, physical examination, gynecological ultrasound, and blood and urine tests. An endometrial sampling was performed in cases of metrorrhagia. All patients had undergone a Papanicolaou smear within the year before the hysterectomy. One hundred thirty-nine patients underwent total hysterectomy, and 341 underwent subtotal hysterectomy; 268 patients also had unilateral or bilateral salpingo-oophorectomy. After receiving a thorough explanation, all patients provided their informed consent. Three experienced laparoscopic surgeons performed all operations.

The patients consisted of two groups: 1) 203 patients who did not undergo cystoscopy at the end of surgery, and 2) 277 patients that did undergo cystoscopy at the end of surgery. The study period consisted of two phases. In the first phase, from January 1998 to May 2001, a bipolar cautery was used to occlude the uterine artery; consequently, a nearby thermal injury could be misdiagnosed or not seen during the cauterization. In the second phase, this

protocol was changed: the uterine artery was clipped with a new hemoclip called Hem-o-lok (Weck Closure Systems, USA), which forced an exact identification of the uterine artery, its closure, and cutting.

Total hysterectomies had been done for cases of endometrial hyperplasia, chronic cervicitis, cervical intraepithelial neoplasia, and endometrial carcinoma, and at patient request. The laparoscopies were performed in the operating room at the hospital day-care unit. Patients were admitted to the day-care unit and, after a very short administrative procedure, were operated on the same morning. All patients received prophylactic antibiotics 1 h before surgery. After surgery, the patients were hospitalized for 24 h and then were discharged home.

## Description of surgery

All surgeries were performed with the patients under general anesthesia in lithotomy position. A Foley catheter was placed into the urinary bladder, and the urine amount was measured constantly. In all cases we inserted the Koh Colpotomizer and the RUMI manipulator (CooperSurgical, USA) transvaginally to manipulate the uterus. In addition, the manipulator was used to elevate the fornices of the vagina so that the ureters deviated laterally. A subumbilical cutaneous incision 1 cm long was made, through which a Veress needle was then inserted into the peritoneal cavity and CO<sub>2</sub> was insufflated. After an optimal intraperitoneal insufflation (pressure was limited to 15 mmHg and flow to 3.5 l/min), the Veress needle was replaced by a 10-mm trocar.

**Table 1** Patient characteristics (TLH laparoscopic total hysterectomy, BSO bilateral salpingo-oophorectomy, STLH laparoscopic subtotal hysterectomy)

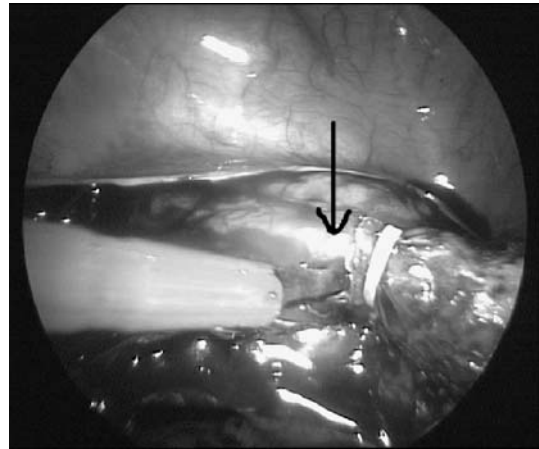
Characteristics	Phase 1 (January 1998–May 2001)	Phase 2 (June 2001–August 2004)	<i>p</i> -value
Number of patients	203	277	
Mean age in years (SD)	49.8 (6.5)	49.4 (6.7)	0.46
Age range in years	34–75	35–76	
Number at menopause	103 (50.74%)	135 (48.74%)	0.66
Indications:			
Fibroid uterus	161 (79.31%)	214 (77.26%)	0.59
Self/familial breast cancer	5 (2.46%)	12 (4.33%)	0.27
Menorrhagia	83 (40.89%)	105 (37.91%)	0.51
Metrorrhagia	1 (0.49%)	3 (1.08%)	0.64
Menometrorrhagia	47 (23.15%)	52 (18.77%)	0.24
Cervical intraepithelial neoplasia 2–3	1 (0.49%)	3 (1.08%)	0.64
Recurrent endometrial polyp	3 (1.48%)	3 (1.08%)	0.70
Recurrent postmenopausal bleeding	16 (7.88%)	26 (9.39%)	0.56
Ovarian cyst	5 (2.46%)	11 (3.97%)	0.36
Pelvic pain	11 (5.42%)	28 (10.11%)	0.063
Endometrial complex hyperplasia	9 (4.43%)	13 (4.69%)	0.89
Endometrial carcinoma	0	9 (3.25%)	0.012
Type of operation:			
TLH [TLH+BSO]	90 [80] (44.33%)	49 [43] (17.68%)	<0.001
STLH [STLH+BSO]	113 [88] (55.67%)	228 [158] (82.31%)	

The camera-laparoscope was then placed through the trocar, and the first intraperitoneal view was enabled. The pelvis and abdominal organs, including the upper abdomen, were thoroughly inspected. Two other trocars, 12 mm in diameter each, had been placed under vision in the lower abdomen bilaterally, about 2 cm above the McBurney point and lateral to the superficial inferior epigastric artery. Then a screw was placed into the lateral fundal myometrium and, together with the vaginal manipulator, delivered enhanced traction capabilities during the various stages of the operation dissection. The dissection was started by bipolar cauterization, scissors, and EndoGIA up to the level of the uterine artery, leaving the adnexa intact to the pelvic wall rather than to the uterus. Using this technique, we could reach the area of the uterine artery more safely and without the adnexa disturbing our visual field. The bladder was pushed down before dissection of the uterine artery area began.

During the first cases and at the beginning of our learning curve, we occluded the uterine vessels by bipolar cauterization and then cut the vessel with scissors. Later, we changed the system and occluded the uterine artery by three flexible hemoclips of the Hem-o-lok (Fig. 1) after a meticulous dissection and isolation of the uterine artery, and cut it between the medial clip and the other two (Fig. 2). The clips were always placed on the uterine artery and not on its branches.

After performing the procedure bilaterally in cases of STLH, the uterus was morcellated. We found it easier and faster to morcellate the uterus without disconnecting it from the cervix prior to the morcellation procedure. Anchoring the uterus to the cervix makes the uterus stable and prevents it from rolling around. Two kinds of morcellators were used, the X-Tract Tissue Morcellator (Gynecare, Ethicon, Johnson & Johnson) and the SAWALHE Electromechanical Morcellator (Karl Storz). Cauterization of the cervical stump and cervical canal was then done by unipolar cautery.

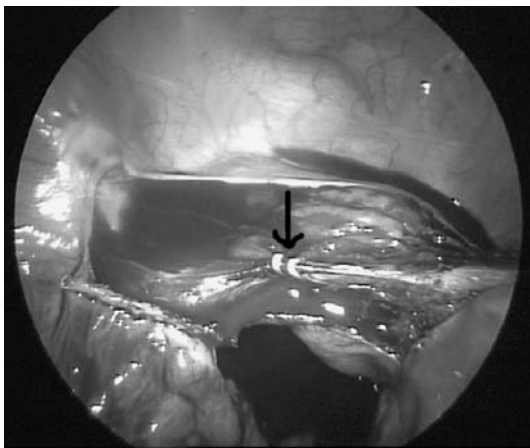
In cases of TLH (Fig. 3), the manipulator was pushed cranially, and the colpotomy was made along the fornices



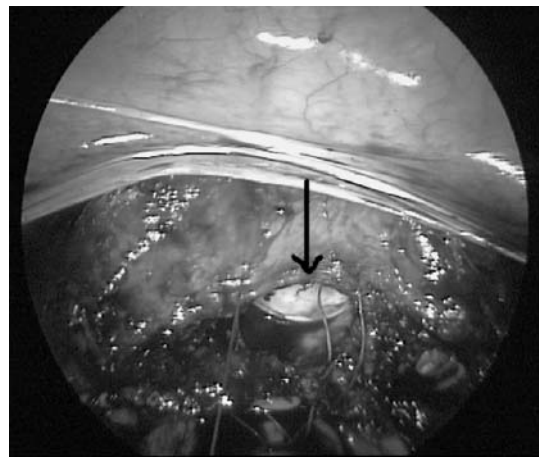
**Fig. 2** The uterine vessels are cut lateral to the medial clip

by a unipolar cauter. The importance of pushing the manipulator is paramount, resulting in a clear definition of the vaginal fornices and an accurate dissection and control while leaving the ureters far apart laterally. The uterus was then pulled out through the vagina, and the vaginal stump was closed laparoscopically by intracorporeal stitches using Vicryl 0 with a 30-mm curved needle. If the ovaries had to be removed, they were resected using bipolar cauterization and scissors.

At the end of surgery, 4 cc of a blue dyeing material, indigo carmine, was administered intravenously, and cystoscopy was carried out. An inspection of the inner bladder wall was performed, along with visualization of a blue urine stream through the ureteral orifices bilaterally. Usually, the blue dye was seen within 5 min from injection. After the procedure, the patient was monitored in the recovery room for 3 h. At the end of the recovery period, the Foley catheter was removed, and the patient got up from her bed and sat upright in a chair in the recovery unit for an additional hour. About 6 h postoperatively, the patient could walk within the unit by herself and was also able to urinate spontaneously. On the morning following



**Fig. 1** The Hem-o-lok clips are closed tightly on the uterine vessels after a meticulous dissection. The bulging of the vaginal manipulator can be clearly seen



**Fig. 3** Total laparoscopic hysterectomy. The vaginal cuff is sutured intracorporeally. The balloon of the manipulator is seen in the vagina to prevent gas leak after removal of the uterus

their operations, most patients were discharged to their homes.

### Statistical analysis

Binary patient characteristics and injury frequencies were compared between the two phases (groups) using the  $\chi^2$  test (and Fisher's exact test when appropriate). Mean age was compared between the phases using *t*-tests. Differences were considered statistically significant at  $p \leq 0.05$ .

### Results

The mean age of the patients was 49.16 years (range 34–76 years). In our study, there were four cases of ureteral injury and one bladder laceration, all found in the noncystoscopy group (Table 2). No cases of ureteral or bladder injury were noted in patients who underwent routine cystoscopy. The bladder laceration happened during TLH, was diagnosed intraoperatively, and was then repaired laparoscopically. Three cases of ureteral injuries were found following STLH and one following TLH. The diagnosis in all patients

was made postoperatively, 7–14 days after surgery, due to patients' complaints of prolonged flank pain and lower abdominal pressure. No systemic fever was recorded. Diagnosis was made clinically and by vaginal sonography, which demonstrated a urinoma.

The diagnosis was then confirmed by intravenous pyelography (IVP) or by computerized tomography. At that point, we consulted with the urologists, and they were involved in the treatment afterward. Out of the four patients, one was treated satisfactorily by ureteral stent, and three patients had to undergo nephrostomy for 3 weeks [7], followed by definitive correction by reimplantation of the ureter.

### Discussion

Most intraoperative ureteral injuries occur during gynecological procedures [1]. The rate of urinary tract injury after laparoscopic hysterectomy ranges between 1.4% and 2.8% [8–10]. We think this kind of complication may occur because of a perceptual error of the anatomy using the two-dimensional view rather than the three-dimensional scope [11]. In 1995 Whiskind and Thompson [12] showed that

**Table 2** Ureteral and bladder injuries (TLH laparoscopic total hysterectomy, BSO bilateral salpingo-oophorectomy, STLH laparoscopic subtotal hysterectomy)

	First phase (n=203)	Second phase (n=277)	p-value
Bladder injury	1 (0.49%)	0 (0%)	NS
Ureteral injury	4 (1.97%)	0 (0%)	0.031
Any urinary tract injury	5 (2.46%)	0 (0%)	0.013
Characteristics	Phase 1 (January 1998–May 2001)	Phase 2 (June 2001–August 2004)	p-value
Number of patients	203	277	
Mean age in years (SD)	49.8 (6.5)	49.4 (6.7)	0.46
Age range in years	34–75	35–76	
Number at menopause	103 (50.74%)	135 (48.74%)	0.66
Indications:			
Fibroid uterus	161 (79.31%)	214 (77.26%)	0.59
Self/familial breast cancer	5 (2.46%)	12 (4.33%)	0.27
Menorrhagia	83 (40.89%)	105 (37.91%)	0.51
Metrorrhagia	1 (0.49%)	3 (1.08%)	0.64
Menometrorrhagia	47 (23.15%)	52 (18.77%)	0.24
Cervical intraepithelial neoplasia 2–3	1 (0.49%)	3 (1.08%)	0.64
Recurrent endometrial polyp	3 (1.48%)	3 (1.08%)	0.70
Recurrent postmenopausal bleeding	16 (7.88%)	26 (9.39%)	0.56
Ovarian cyst	5 (2.46%)	11 (3.97%)	0.36
Pelvic pain	11 (5.42%)	28 (10.11%)	0.063
Endometrial complex hyperplasia	9 (4.43%)	13 (4.69%)	0.89
Endometrial carcinoma	0	9 (3.25%)	0.012
Type of operation:			
TLH [TLH+BSO]	90 [80] (44.33%)	49 [43] (17.68%)	<0.001
STLH [STLH+BSO]	113 [88] (55.67%)	228 [158] (82.31%)	
	First phase (n=203)	Second phase (n=277)	p-value
Bladder injury	1 (0.49%)	0 (0%)	NS
Ureteral injury	4 (1.97%)	0 (0%)	0.031
Any urinary tract injury	5 (2.46%)	0 (0%)	0.013



most ureteral injuries had not been noticed by the surgeons, and that in extreme cases the delay in diagnosis may lead to a permanent loss of renal function or to ureterovaginal fistula. Therefore, they recommended performing a cystoscopy after every hysterectomy.

Makinen et al. [4] screened 2,434 cases of total laparoscopic hysterectomies in Finland from 1996 and found a rate of 1.1% ureteral injuries, with 2.2% when the surgeon had less experience (<30 surgeries) and 0.5% with experienced hands. A similar rate was found also by Seman et al. with LAVH [13], and a much higher rate, 3.4%, was found following TLH with vault suspension, according to Riberio et al. [14]. Wattiez et al. [15], published in 2002, found in their experience 0.6% ureteral damage and 1.6% bladder lacerations in the first 700 cases and only 0.2% and 0.6% ureteral and bladder injuries, respectively, in the last 950 cases. They showed an actual improvement in surgical performance along the learning curve. In the current study, we also demonstrated a similar trend of improved prevention of ureteral and bladder damage in the ensuing years (Table 1).

A question that arises concerning routine cystoscopy after laparoscopy is its cost-effectiveness. In 2001 Visco et al. [16] evaluated the cost-effectiveness of routine cystoscopy at the time of abdominal hysterectomy, VH, and LAVH in terms of cost per ureteral injury identified and treated. They found that it was dependent on the rate of ureteral injury. If the rate exceeds 1.5% for abdominal hysterectomy and 2% for LAVH or VH, then routine cystoscopy is cost-effective. However, in the current description, cystoscopy is suggested during a specific procedure: laparoscopy. Because all the cystoscopic equipment during laparoscopy is available and sterile, the only additional cost would be the ampule of indigo carmine. The cystoscopy is performed by one surgeon, while at the same time the other surgeon closes the fascia and the skin, so there is little or no additional operating time.

An interesting observation is that in three out of the four mentioned cases, ureteral injuries occurred during supra-cervical hysterectomies rather than in total hysterectomies. Accordingly, one would expect to find more of such injuries in total hysterectomies because of this procedure's further and deeper dissection. The explanation for this result was the complexity and anatomical difficulty in these three patients, which is why they were scheduled for STLH in the first place. The symptoms of ureteral injury depend on the type of the injury, whether it is a cutting damage (complete or incomplete) or closure. The patient might complain of flank pain and lower abdominal pressure. Upon examination, costovertebral tenderness may be detected. In the case of delayed diagnosis, the patient may present with fever, ileus, urine peritonitis (due to urinoma), and pyelonephritis. Anuria may occur in cases of complete bilateral occlusion or be due to peritonitis. Sonographic signs of absence of a ureteric jet, ascites, and the presence or absence of hydronephrosis are significant for differentiating complete, partial, or non-obstructive surgical ureteral injuries [17].

During laparoscopy, ureteral damage can occur directly by transection with scissors or by misapplication of a clamp. Thermal damage direct to the ureter or propagating from a distance may also occur. Thermal damage usually shows a late onset. Another cause of occlusion is kinking with a nearby suture.

A complete obstruction of the ureter does not necessarily compromise the ipsilateral renal function. Shapiro and Bennett [18] presented three cases with a recovery of renal function after apparent occlusion for 28–158 days. Cases of renal recovery after complete occlusion of more than 100 days were also reported by Everett and Williams [19]. The significance of these findings is that even in the 3rd month following hysterectomy, if ureter occlusion is suspected then it is reasonable to relieve the obstruction to salvage the kidney. However, if symptoms of infection occur, antibiotic treatment must be given before urologic surgery in order to avoid intra- and postoperative complications.

Once an injury to the ureter has occurred and has been diagnosed during laparoscopy, the ureter should be repaired at the same time. In most medical centers, consultation with a urologist is recommended for proper handling of the case. Exposure of the ureter is mandatory for achieving successful correction. Nezhat and Nezhat [20] were the first to describe laparoscopic repair of the ureter; however, if laparoscopic repair is not possible, a laparotomy should be done.

Performing a cystoscopy at the end of laparoscopic hysterectomy is also important because it has educational value for young residents as a routine procedure and allows them to gain experience in that procedure [21].

Regarding thermal damage to the ureter, it is possible that cystoscopy at the end of the hysterectomy could show a patent ureter, as the result of the damage may not show until some days later. To avoid such a pitfall (or at least minimize it), we insist on seeing a symmetrical, good, wide jet of blue urine coming out through the orifice of both ureters. Also, as mentioned above, the use of diathermy for closing the uterine vessels, which is the main area of possible thermal damage to the ureter, was abandoned for selective clamping with the Hem-o-lok.

In summary, cystoscopy at the end of laparoscopic hysterectomy is as important as hemostasis inspection. It enables immediate recognition and correction of a possible ureteral injury in the same session and, as a result, a decreased morbidity rate. The cystoscopy also gives confidence to the surgeon and patient. In patients presenting with urinary complaints during the recovery period, cystoscopic inspection at the end of laparoscopic hysterectomy prevents the need for expensive and invasive tests (which are also inconvenient for the patient), the vast majority of which will show no injury.

From our study, we drew the following two lessons: 1) using Hem-o-lok clips for closing the uterine vessels after a thorough dissection of the uterine vessels, rather than using coagulation, and 2) conducting a routine cystoscopy at the end of every laparoscopic hysterectomy.

## References

1. Dowling RA, Corriere JN Jr, Sandler CM (1986) Iatrogenic ureteral injury. *J Urol* 133:912–915
2. Carley ME, McIntire D, Carley JM et al (2002) Incidence, risk factors and morbidity of unintended bladder or ureter injury during hysterectomy. *Int Urogynecol J Pelvic Floor Dysfunct* 13(1):18–21
3. Cosson M, Lambaudie E, Boukerrou M et al (2001) Vaginal, laparoscopic, or abdominal hysterectomies for benign disorders: immediate and early postoperative complications. *Eur J Obstet Gynecol Reprod Biol* 98(2):231–236
4. Makinen J, Johansson J, Tomas C et al (2001) Morbidity of 10,110 hysterectomies by type of approach. *Hum Reprod* 16(7):1473–1478
5. Mathevet P, Valencia P, Cousin C et al (2001) Operative injuries during vaginal hysterectomy. *Eur J Obstet Gynecol Reprod Biol* 97(1):71–75
6. Visco AG, Barber MD, Myers ER (2002) Early physician experience with laparoscopically assisted vaginal hysterectomy and rates of surgical complications and conversion to laparotomy. *Am J Obstet Gynecol* 187(4):1008–1012
7. Rafique M, Arif MH (2002) Management of iatrogenic ureteric injuries associated with gynecological surgery. *Int Urol Nephrol* 34(1):31–35
8. Garry R, Phillips G (1995) How safe is the laparoscopic approach to hysterectomy? *Gynaecol Endosc* 4:77–79
9. Harkki-Siren P, Sjoberg J, Makinen J et al (1997) Finnish national register of laparoscopic hysterectomies: a review and complications of 1,165 operations. *Am J Obstet Gynecol* 176:118–122
10. Mage G, Masson FN, Canis M et al (1995) Laparoscopic hysterectomy. *Curr Opin Obstet Gynecol* 7:283–289
11. Way LW, Stewart LS, Gantert W et al (2003) Causes and prevention of laparoscopic bile duct injuries—analysis of 252 cases from a human factors and cognitive psychology perspective. *Ann Surg* 237(4):460–469
12. Wiskind AK, Thompson JD (1995) Should cystoscopy be performed at every gynecologic operation to diagnose unsuspected ureteral injury? *J Pelvic Surg* 1:134–137
13. Seman EI, O'Shea RT, Gordon S et al (2001) Routine cystoscopy after laparoscopically assisted hysterectomy: what's the point? *Gynecol Endosc* 10(4):253–256
14. Ribiero S, Reich H, Rosenberg J et al (1999) The value of intraoperative cystoscopy at the time of laparoscopic hysterectomy. *Hum Reprod* 14(7):1727–1729
15. Wattiez A, Soriano D, Cohen SB et al (2002) The learning curve of total laparoscopic hysterectomy: comparative analysis of 1647 cases. *J Am Assoc Gynecol Laparosc* 9(3):339–345
16. Visco AG, Taber KH, Weidner AC et al (2001) Cost-effectiveness of universal cystoscopy to identify ureteral injury at hysterectomy. *Obstet Gynecol* 97(5 Pt 1):685–692
17. Hung MJ, Huang CH, Chou MM et al (2000) Ultrasonic diagnosis of ureteral injury after laparoscopically-assisted vaginal hysterectomy. *Ultrasound Obstet Gynecol* 16(3):279–283
18. Shapiro SR, Bennett AH (1976) Recovery of renal function after prolonged unilateral ureteral obstruction. *J Urol* 115:136–140
19. Everett HS, Williams TJ (1970) Urology in the female. In: Campbell MF, Harrison JB (eds) *Urology*, vol 3, 3rd edn. WB Saunders, Philadelphia, pp 1957–1970
20. Nezhat C, Nezhat F (1992) Laparoscopic repair of ureter. *Obstet Gynecol* 80:543–544
21. Hibbert ML, Salminen ER, Dainty LA et al (2000) Credentialing residents for intraoperative cystoscopy. *Obstet Gynecol* 96(6):1014–1017