

Erratum to: The impact of hydrophobic hernia mesh coating by omega fatty acid on atraumatic fibrin sealant fixation

S. Gruber-Blum · J. Brand · C. Keibl · H. Redl ·
R. H. Fortelny · C. May · A. H. Petter-Puchner

Published online: 20 February 2015
© Springer-Verlag France 2015

Erratum to: Hernia
DOI 10.1007/s10029-014-1304-y

The authors would like to notify readers that unfortunately, Fig. 1 and associated captions are incorrectly published in the original publication. The correct figure and legend are given here:

The online version of the original article can be found under doi:[10.1007/s10029-014-1304-y](https://doi.org/10.1007/s10029-014-1304-y).

S. Gruber-Blum · C. Keibl · H. Redl ·
A. H. Petter-Puchner (✉)

Ludwig Boltzmann Institute for Experimental and Clinical
Traumatology, Cluster for Tissue Regeneration,
Donaueschingenstrasse 13, 1200 Vienna, Austria
e-mail: alexander.petter@trauma.lbg.ac.at

J. Brand
Department of Traumatology, Federal Hospital Horn,
Spitalgasse 10, 3580 Horn, Austria

R. H. Fortelny · C. May · A. H. Petter-Puchner
Department of General, Visceral and Oncological Surgery,
Wilhelminenspital, Montleartstrasse 37, 1171 Vienna, Austria

R. H. Fortelny
Paracelsus Medizinische Privatuniversität, Strubergasse 21,
5020 Salzburg, Austria

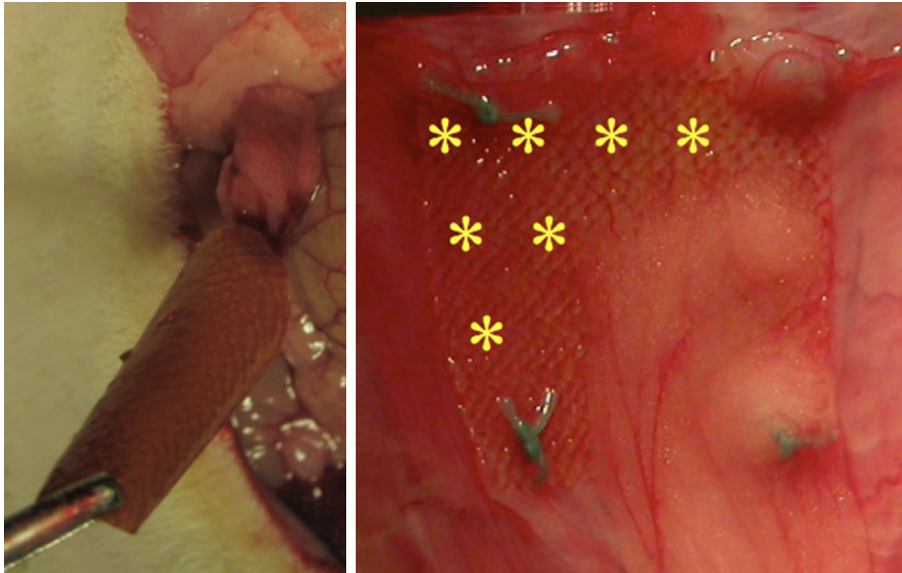


Fig. 1 Fibrin sealant- versus suture fixation in the IPOM position at 6 weeks follow-up. The sealed mesh (*left picture*) is not adherent to the abdominal wall. *Asterisks* mark incomplete tissue integration of

mesh margins and surface in the sutured implant. Adhesion strands are mainly covering sutures and mesh borders