

Temporal lobe epilepsy associated with GAD autoimmunity

Atsushi Obata¹ · Yumiko Kutoku² · Yoshihide Sunada² · Seizo Okauchi¹ ·
Tomohiko Kimura¹ · Hidenori Hirukawa¹ · Akihito Tanabe¹ · Tomoe Kinoshita¹ ·
Kenji Kohara¹ · Fuminori Tatsumi¹ · Masashi Shimoda¹ · Shinji Kamei¹ ·
Shuhei Nakanishi¹ · Tomoatsu Mune¹ · Kohei Kaku¹ · Hideaki Kaneto¹

Received: 19 July 2016 / Accepted: 1 September 2016 / Published online: 8 September 2016
© The Author(s) 2016. This article is published with open access at Springerlink.com

Dear Editor,

Slowly progressive insulin-dependent diabetes mellitus (SPIDDM) and latent autoimmune diabetes in adults (LADA) are classified as a form of type 1 diabetes that has an autoimmune basis. They are also characterized by the presence of glutamic acid decarboxylase (GAD) antibody. GAD catalyzes the synthesis of gamma aminobutyric acid (GABA), which is the major inhibitory neurotransmitter in the central nervous system. Antibodies against GAD have been confirmed in patients with a number of neurological conditions such as stiff person syndrome, cerebellar ataxia, limbic encephalitis, myoclonus and epilepsy [1–4]. We herein report a case of a subject who had high titer GAD antibody and finally developed temporal lobe epilepsy. We also followed the change of GAD antibody titer for 3 years.

A 28-year-old female visited our hospital as her urinary glucose became positive during her pregnancy. She had no past medical history and no family history of epilepsy. On the first visit, she was in her second trimester pregnancy. In laboratory test, HbA1c was 5.5 % and fasting blood glucose level was 4.1 mmol/l. She was diagnosed with gestational diabetes mellitus after oral glucose tolerance test. In addition, serum GAD antibody was extremely elevated up to 8230 U/ml. These data suggested that she was complicated with SPIDDM/

LADA. As her postprandial blood glucose level was high, we started insulin injection and she obtained good glycemic control and finally delivered a healthy baby. As glucose intolerance persisted even after the delivery, we continued insulin therapy. GAD antibody titer in this patient was constantly very high and was gradually further increased up to nearly 20,000 U/ml (Fig. 1a). About 3 years after the first visit when GAD antibody titer was nearly 20,000 U/ml, she felt tightness of the chest and palpitation which continued for a few minutes which was followed by the development of automatism of mouth and hands. She also had amnesia for automatism and conversation during the episodes. She underwent brain MRI, which revealed a high intensity area in right amygdala in FLAIR images (Fig. 1b). Although there were no obvious findings in electroencephalography, we diagnosed her with temporal lobe epilepsy from clinical symptoms and MRI findings. Paraneoplastic syndrome was ruled out by systemic imaging screening [5]. In laboratory examination, HSV, CMV, measles, mumps and EBV showed patterns of past infection and HIV was negative. Antinuclear antibody (ANA), anti-ss-DNA antibody, anti-ds-DNA antibody, anti-cardiolipin antibody, anti-SS-A antibody, anti-SS-B antibody, anti-cyclic citrullinated peptide antibody (anti-CCP antibody), proteinase3 anti-neutrophil cytoplasmic antibody (PR3-ANCA) and myeloperoxidase anti-neutrophil cytoplasmic antibody (MPO-ANCA) were all negative. Only anti-thyroglobulin antibody was positive (80.4 IU/ml). These results indicated no sign of active viral infection, other autoimmune diseases such as systemic lupus erythematosus, anti-phospholipid syndrome, Sjögren's syndrome, rheumatoid arthritis and vasculitis. In cerebrospinal fluid (CSF) examination, CSF appearance was clear and cell counts, glucose concentration, total protein and IgG index were all within normal range: 2 cells/ μ l (100 % monocyte), 4 mmol/l, 0.25 g/l and 0.43 (normal range 0.3–0.7), respectively. PCR test for HSV,

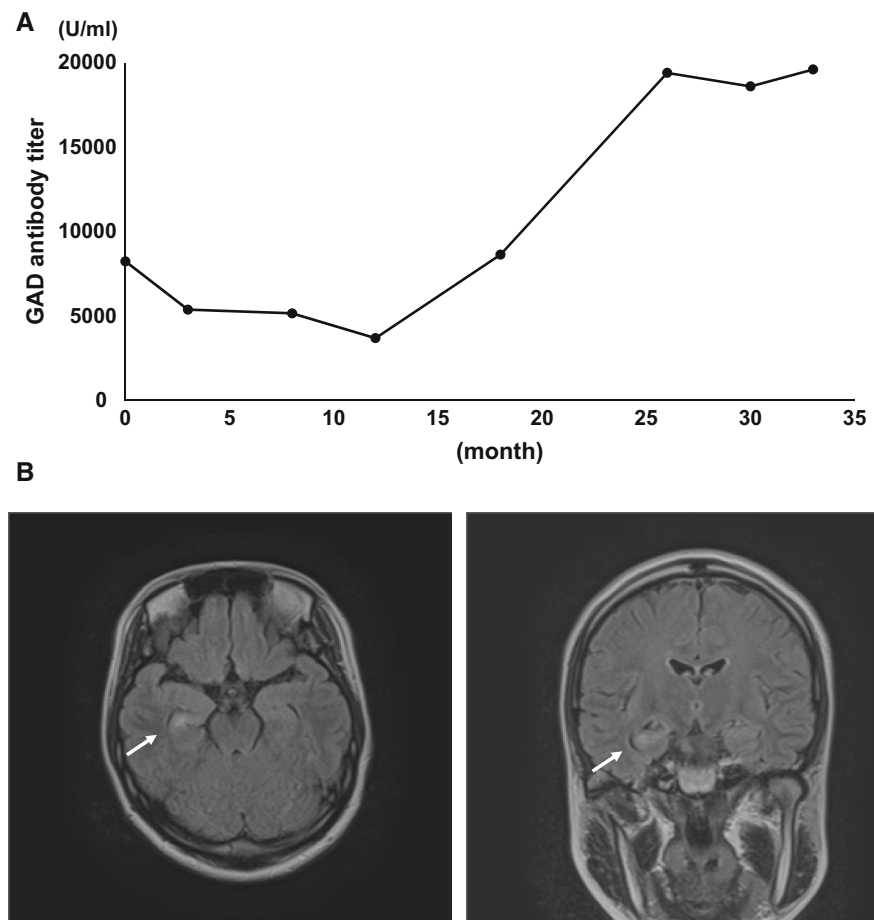
Managed by Antonio Secchi.

✉ Atsushi Obata
obata-ky@med.kawasaki-m.ac.jp

¹ Department of Diabetes, Endocrinology and Metabolism, Kawasaki Medical School, 577 Matsushima, Kurashiki 701-0192, Japan

² Department of Neurology, Kawasaki Medical School, 577 Matsushima, Kurashiki 701-0192, Japan

Fig. 1 a Change of GAD antibody titer from the first visit to the onset of temporal epilepsy. **b** Brain MRI (FLAIR images) showing a high intensity area in right amygdala (arrows)



CMV, measles, mumps and HHV-6 in CSF was all negative. GAD antibody in CSF was elevated up to 425 U/ml. It is hard to rule out the other autoimmune antibody-associated encephalopathy as our screening did not cover all autoimmune antibodies. However, temporal lobe epilepsy associated with GAD antibody was strongly suspected in this case from its clinical course as temporal lobe epilepsy developed accompanied with further elevation of GAD antibody titer.

Taken together, we think that temporal lobe epilepsy was associated with GAD autoimmunity in this patient. After starting carbamazepine, her symptom was gradually mitigated. However, since it has been reported that GAD-associated central nerve system disorders are refractory and drug resistant, we think that we should be careful about the exacerbation of the disease in the future.

In conclusion, we propose that physicians need to pay attention to neurological symptoms in patients with high titer GAD antibody.

Acknowledgments We thank Y.K. and Y.S. for their excellent advice from specialist's point of view. A.O. is the guarantor of this work and, as such, had full access to all the data in the study and takes responsibility for the integrity of the data and the accuracy of the data analysis.

Authors' contributions A.O. wrote the manuscript. H.K. reviewed the manuscript. S.O., T.Kim, H.H., A.T., T.Kino., K.Ko., F.T., M.S., S.K., S.N., T.M. and K.Ka. contributed to the discussion.

Compliance with ethical standards

Conflict of interest The authors declare that they have no conflict of interest.

Ethical standard All procedures followed were in accordance with the ethical standards of the responsible national committee on human experimentation and with the Helsinki Declaration of 1975, as revised in 2008.

Human and animal rights statement All procedures followed were in accordance with the ethical standards of the responsible committee on human experimentation (institutional and national) and with the Helsinki Declaration of 1975, as revised in 2008.

Informed consent statement Informed consent was obtained from the patient for being included in the study.

Open Access This article is distributed under the terms of the Creative Commons Attribution 4.0 International License (<http://creativecommons.org/licenses/by/4.0/>), which permits unrestricted use, distribution, and reproduction in any medium, provided you give appropriate credit to the original author(s) and the source, provide a link to the Creative Commons license, and indicate if changes were made.

References

1. Nemni R, Braghi S, Natali-Sora MG, Lampasona V, Bonifacio E, Comi G, Canal N (1994) Autoantibodies to glutamic acid decarboxylase in palatal myoclonus and epilepsy. *Ann Neurol* 36:665–667
2. Solimena M, Folli F, Denis-Donini S, Comi GC, Pozza G, De Camilli P, Vicari AM (1988) Autoantibodies to glutamic acid decarboxylase in a patient with stiff-man syndrome, epilepsy, and type I diabetes mellitus. *N Engl J Med* 318:1012–1020
3. Solimena M, Folli F, Aparisi R, Pozza G, De Camilli P (1990) Autoantibodies to GABA-ergic neurons and pancreatic beta cells in stiff-man syndrome. *N Engl J Med* 322:1555–1560
4. Baekkeskov S, Aanstoot HJ, Christgau S, Reetz A, Solimena M, Cascalho M, Folli F, Richter-Olesen H, De Camilli P (1990) Identification of the 64K autoantigen in insulin-dependent diabetes as the GABA-synthesizing enzyme glutamic acid decarboxylase. *Nature* 347:151–156
5. Folli F, Solimena M, Cofield R, Austoni M, Tallini G, Fassetta G, Bates D, Cartledge N, Bottazzo GF, Piccolo G, De Camilli P et al (1993) Autoantibodies to a 128-kd synaptic protein in three women with the stiff-man syndrome and breast cancer. *N Engl J Med* 328:546–551