

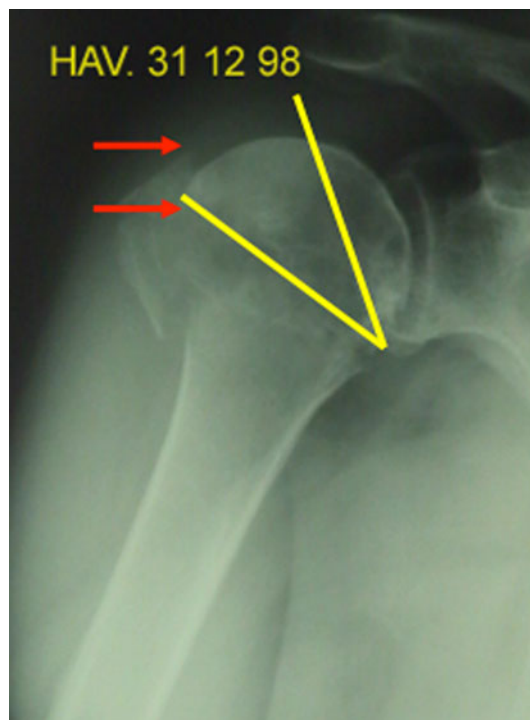## Erratum to: AST classification of proximal humeral fractures: introduction and interobserver reliability assessment

Christian Cuny · Cedric Baumann · Julien Mayer ·  
Didier Guignand · M'barek Irrazi · Aboubekr Berrichi ·  
Nicolas Ionescu · Francis Guillemin

Published online: 22 February 2013  
© Springer-Verlag France 2013

**Erratum to: Eur J Orthop Surg Traumatol (2013)**  
**23:35–40**  
**DOI 10.1007/s00590-011-0916-5**

Unfortunately, critical information on Figs. 8 and 9 was missing in the original article. Hereby, the correct figures are published and we apologize for the inconvenience.

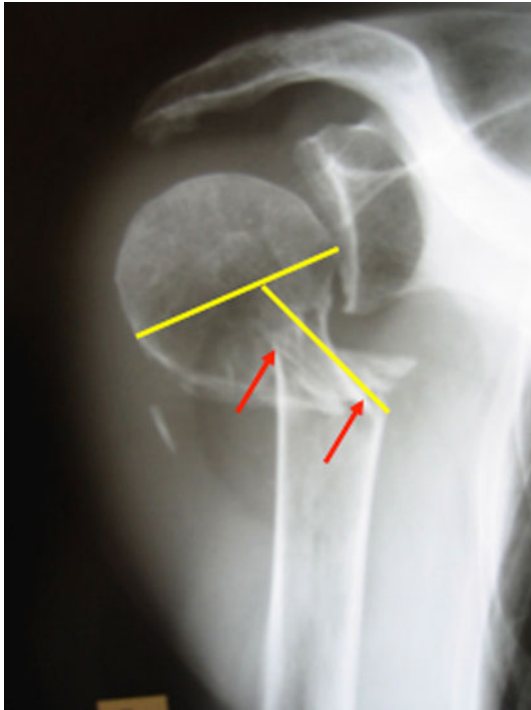


**Fig. 8** “A2-40°-10 mm” (Articular impacted with 40° of cephalic tilting and 10 mm of linear displacement)

The online version of the original article can be found under  
doi:[10.1007/s00590-011-0916-5](https://doi.org/10.1007/s00590-011-0916-5).

C. Cuny (✉) · J. Mayer · D. Guignand · M. Irrazi · A. Berrichi ·  
N. Ionescu  
Department of Orthopaedics and Traumatology,  
CHR Metz Bon-Secours, 57038 Metz Cedex, France  
e-mail: [c.cuny@chr-metz-thionville.fr](mailto:c.cuny@chr-metz-thionville.fr)

C. Baumann · F. Guillemin  
Department of Clinical Epidemiology, CHU Nancy,  
Rue du Morvan, 54511 Vandoeuvre-lès-Nancy, France



**Fig. 9** “S-60°-20 mm” (Surgical neck with an angle of 60° and 20 mm of linear displacement)