

## Erratum to: Appearances of screen-detected versus symptomatic colorectal cancers at CT colonography

Andrew A. Plumb<sup>1</sup> · Fiona Pathiraja<sup>1</sup> · Claire Nickerson<sup>2</sup> · Katherine Wooldrage<sup>3</sup> · David Burling<sup>4</sup> · Stuart A. Taylor<sup>1</sup> · Wendy S. Atkin<sup>3</sup> · Steve Halligan<sup>1</sup>

Published online: 17 May 2016  
© European Society of Radiology 2016

**Erratum to: Eur Radiol**  
**DOI 10.1007/s00330-016-4293-7**

Owing to an oversight in typesetting, Fig. 2 was duplicated and Fig. 3 (below) omitted from the original publication. The mistake has since been corrected. The publisher apologises for this error and the inconvenience caused.

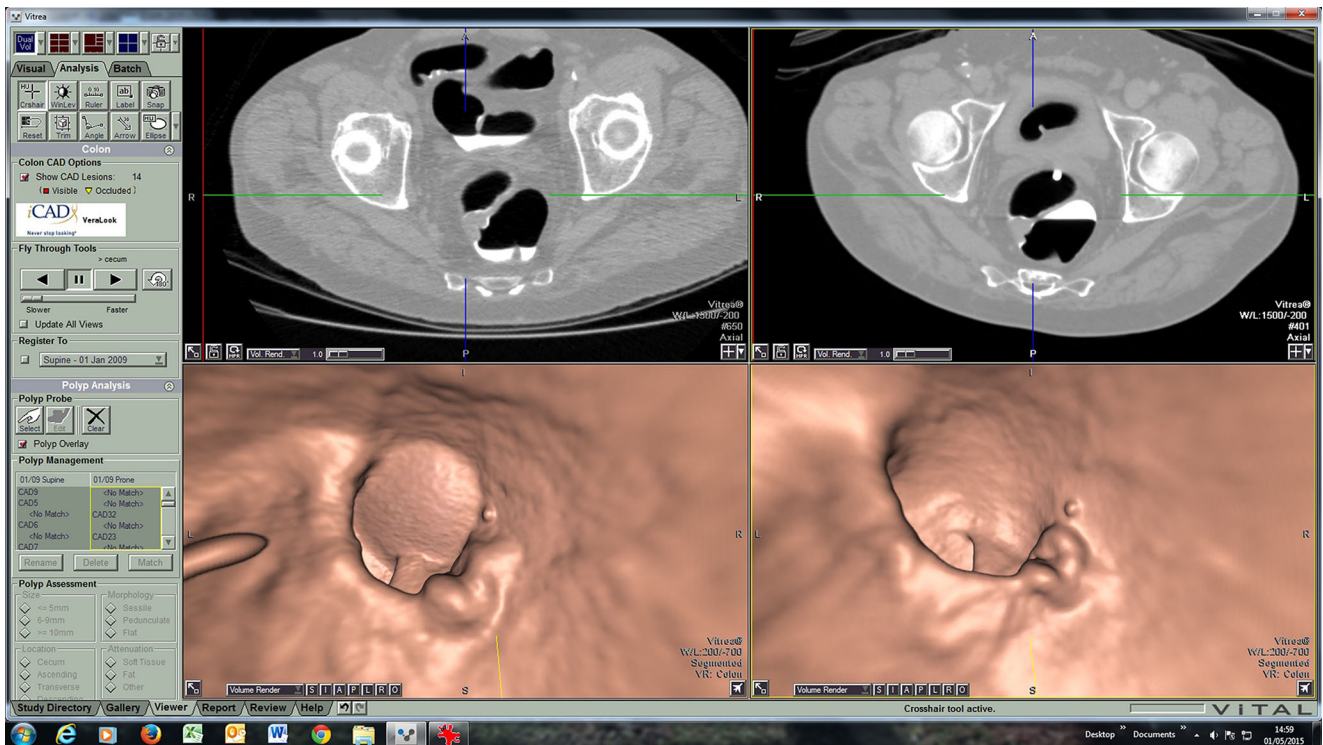
---

The online version of the original article can be found at <http://dx.doi.org/10.1007/s00330-016-4293-7>.

---

✉ Steve Halligan  
s.halligan@ucl.ac.uk; yangcan.gong@nhs.net

- <sup>1</sup> Centre for Medical Imaging, University College London, London, UK
- <sup>2</sup> Public Health England, Fulwood House, Sheffield, UK
- <sup>3</sup> Department of Surgery and Cancer, Imperial College London, London, UK
- <sup>4</sup> Intestinal Imaging Centre, St Mark's Hospital, Harrow, UK



**Fig. 3** Example of an upper rectal tumour missed by computer-aided detection (CAD) in a screening patient. Image quality was judged to be good by both readers, with a small amount of residual fluid which was well tagged