

Inside-Out versus Outside-In models for virus induced demyelination: axonal damage triggering demyelination

Ikuro Tsunoda, Robert S. Fujinami

Department of Neurology, 3R330 School of Medicine, University of Utah, 30 North 1900 East, Salt Lake City, Utah 84132-2305, USA

Abstract. The primary target in multiple sclerosis (MS) is believed to be either myelin itself (myelinopathy) or the myelin-forming cell, the oligodendrocyte (oligodendroglipathy). Although axonal injury occurs in MS, it is regarded as a secondary event to the myelin damage. Here, the lesion develops from myelin (outside) to the axon (inside) (Outside-In model). Recently, gray matter lesions and axonal injury in normal-appearing white matter have also been reported in MS. This raises two questions. 1) Is axonal injury exclusively secondary to myelin damage or from a direct insult to the axon or neurons (axonopathy)? (2) Is the injured axon regarded as only an end result of pathology or disease, or can axonal injury contribute to the spread of secondary damage, including demyelination? The former is raised from the fact that axonal damage has been reported in several virus infections, including human immunodeficiency virus, human T-lymphotropic virus 1, herpes simplex virus and coronavirus, which also cause demyelination. The latter possibility where axonal injury leads to other changes is raised from the rather unexpected similarity between spinal cord injury (SCI) and MS where axonal injury, oligodendrocyte apoptosis and demyelination are all present. In SCI, transection of axons leads to delayed oligodendrocyte apoptosis with secondary demyelination. Neurofilament immunostaining of spinal cord sections demonstrates that axonal injury with oligodendrocyte apoptosis also precedes demyelination in an animal model for MS, Theiler's murine encephalomyelitis virus infection. This implies that axonal injury could trigger demyelination. In this instance, lesions develop from the axon (inside) to the myelin (outside) (Inside-Out model).

Introduction

Is multiple sclerosis a pure oligodendroglipathy/myelinopathy, but not an axonopathy?

Multiple sclerosis (MS) is an inflammatory demyelinating disease of the central nervous system (CNS). Although its precise etiology is unknown, MS is considered to

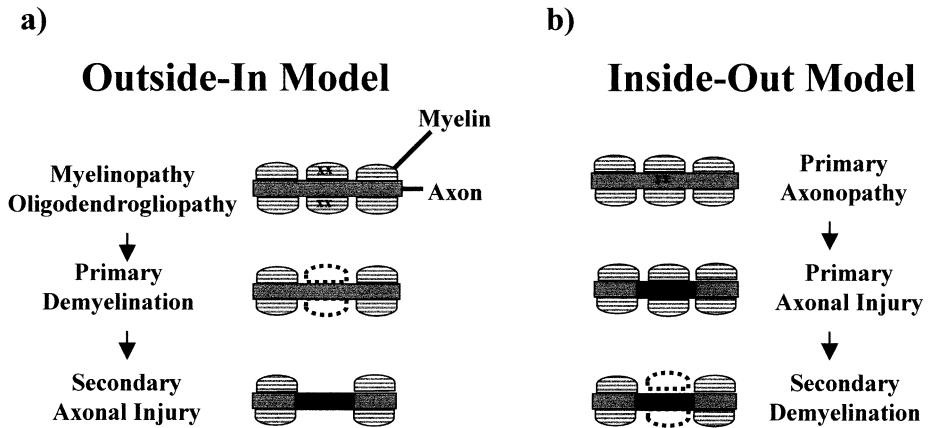


Fig. 1a,b. Outside-In and Inside-Out models for demyelinating diseases. **a** Outside-In model. The lesion develops from the outside to the inside. The primary target is myelin or the myelin forming cell, oligodendrocyte. After primary myelin destruction, the axon is damaged secondarily. **b** Inside-Out model. The lesion develops from the inside to the outside. The primary target is the axon or its cell body, the neuron. Primary axonal injury leads to secondary demyelination

be an immune-mediated disease, occurring in genetically susceptible individuals, precipitated by one or more environmental agents, most likely infectious in nature. Virus infections have been associated with MS or models of MS [7, 26, 88, 99].

The primary target of MS is believed to be either myelin itself (myelinopathy) or the myelin-forming cell, the oligodendrocyte (oligodendroglipathy). Although axonal injury has been demonstrated in MS [23, 84], it is believed to be secondary to myelin injury [48]. In this scenario, the lesion develops from myelin (outside) to the axon (inside) (Outside-In model) (Fig. 1a). In this Outside-In model, myelin and/or oligodendrocytes can be damaged by: (1) direct virus infection; (2) cytotoxic T cells and macrophages; (3) toxic substances, including cytokines and proteases, produced by T cells, macrophages, and glial cells; and/or (4) autoantibodies against myelin and oligodendrocytes. Recently, gray matter involvement, occurring in normal-appearing gray matter (NAGM) [78], and axonal injury present in normal-appearing white matter (NAWM) have been demonstrated in MS [12, 43, 48]. This raises two questions. First, does axonal injury arise from destruction of myelin surrounding axons due to a bystander effect or from a direct insult to axons or neurons (primary axonopathy)? Second, regardless of the cause of axonal damage, is this simply an end product, or could this contribute to secondary damage or trigger demyelination?

Can axons be the primary target in MS? Axonal form of Guillain-Barré syndrome

This question relates to the recent proposal for an axonal form of Guillain-Barré syndrome (GBS). While MS is an inflammatory demyelinating disease in the CNS, its counterpart in the peripheral nervous system (PNS) is acute or chronic inflammatory demyelinating polyradiculoneuropathy (AIDP or CIDP). Classical pathological studies of GBS showed the presence of prominent demyelination and inflammatory infiltrates in the spinal roots and nerves. On this basis, GBS has been considered to be

synonymous with the pathological designation, AIDP [21]. In 1986, however, Feasby et al. [22] described an axonal form of GBS and challenged the existing notion of GBS being a primarily demyelinating disease [14]. In axonal GBS, axonal degeneration can be seen without demyelination or lymphocyte infiltration [29]. This is contrary to the traditional belief that axonal involvement in GBS occurs secondarily to or by a bystander fashion following severe demyelination. In axonal GBS, frequent associations with antecedent *Campylobacter jejuni* infections and with anti-ganglioside antibodies have been demonstrated. Molecular mimicry between *C. jejuni* and a neural epitope has been proposed as a mechanism for immunopathology. This is further supported by an animal model of axonal GBS that is induced by sensitization with GM1 ganglioside [103]. Although axonal degeneration is increasingly recognized in MS, it is regarded as only a secondary or bystander event. Is there primary axonal damage in MS and its animal model Theiler's murine encephalomyelitis virus (TMEV) infection?

Can axonal injury contribute to demyelination in MS as in spinal cord injury?

This question is raised from a rather unexpected area, spinal cord injury (SCI). Recently, similarities in neuroimmunology and neuropathology have shown that in both MS and SCI; axonal injury, oligodendrocyte apoptosis and demyelination are all present [9, 10]. In SCI, transection of an axon leads to delayed oligodendrocyte apoptosis and secondary demyelination. Neurofilament immunostaining of spinal cord sections from TMEV-infected mice visualizes axonal injury with oligodendrocyte apoptosis preceding the demyelination [90]. This suggests that axonal injury may well trigger demyelination. In this review, we propose a new model for the development of demyelination, in which lesions develop from the axon (inside) to the myelin (outside) (Inside-Out model) (Fig. 1b).

The first section of this review provides a brief overview of the findings and theories in axonal pathology both in MS and a variety of virus infections, and introduces recent findings of axonal pathology and oligodendrocyte apoptosis in TMEV infection. In the second part we will discuss similarities between TMEV infection and SCI, and review possible mechanisms of close association between axonal injury and demyelination: (1) disruption of cross-talk between the axon and the oligodendrocyte; (2) activation of microglia/macrophages and induction of oligodendrocyte apoptosis; and (3) induction of autoimmunity by CNS injury. Lastly, we will discuss the possible association of the Inside-Out versus Outside-In models, in which the two models are not mutually exclusive, and could be useful in explaining different pathological features which, in reality, may be simply due to looking at different aspects of a consecutive series of events.

Axonal pathology in MS

Using a silver impregnation technique and electron microscopy [82], early studies demonstrated axonal degeneration in MS [32, 37]. However, little attention was paid to this axonal degeneration as compared to primary demyelination, extensive myelin loss with 'relative' preservation of axons. Previous emphasis was on relative "preservation" of axons, not on the detectable axonal "degeneration." Three pathological

and neuroimaging studies in recent years have challenged the historical view of preserved axonal integrity in MS [80].

First, immunostaining studies provided direct evidence of axonal damage using antibodies against two markers for injured axons: nonphosphorylated neurofilament (NF) [84], and amyloid precursor protein (APP) [23, 28]. This made possible the identification of earlier and subtler changes than those seen by silver staining [28]. The number of macrophages correlated with the extent of axonal damage that showed spheroid enlargement or axonal swelling. However, acute inflammatory demyelination was not demonstrated to correlate with axonal injury at least in secondary progressive (SP)-MS. Lovas et al. [43] demonstrated a significant reduction of axonal density in SP-MS and there was no significant difference in axonal density in the MS plaque versus contralateral NAWM. They suggest that the equally decreased axonal density in the NAWM and in the plaque could represent the final outcome of multisegmental long-standing inflammation affecting the tracts.

Second, magnetic resonance spectroscopy (MRS) analysis provided information on axonal pathology by analyzing the chemical composition of brain tissue [48]. In practice the ratio of N-acetyl aspartate (NAA) to creatine (Cr) (NAA/Cr) is used, as NAA is confined to neurons and neuronal processes and Cr is more evenly distributed. A reduction in the ratio in the white matter has been attributed to axonal loss, atrophy, degeneration or metabolic dysfunction. Patients with MS have lower levels of NAA than normal controls. Partially reversible signal decrease is observed during the active inflammatory phase, which becomes irreversible during the chronic inactive state. The reversibility is interpreted as the result of the presence of edema, reactive astrocytes and inflammatory cells or as reversible axonal atrophy or metabolic dysfunction. The NAA/Cr signal decrease was also observed in NAWM in both patients with relapsing-remitting (RR)-MS and SP-MS, while SP-MS patients showed lower NAA/Cr ratios than those in RR-MS [24].

Third, atrophy of the brain and the spinal cord has been described on CT and MRI, and it is associated with disturbances in neuropsychological and clinical function [81]. Volume loss occurs in the corpus callosum, cerebellum, spinal cord and in tissues surrounding the third and lateral ventricles. In addition to myelin loss and tissue contraction from gliosis, axonal loss is believed to contribute to the CNS atrophy.

Although there is evidence of axonal injury in MS, the axon has been regarded as an innocent bystander, not as a specific immune target. Axonal destruction, however, may be due to immune attack directed at axonal components [80]. Antibodies to neurofilament and tubulin have been reported to be present in some MS patients. It is uncertain whether these anti-axonal antibodies play a pathogenic role or merely reflect a release of axonal components to the systemic circulation following axonal degeneration.

Axonal pathology in virus infection

Axonal transport and axonal injury in virus infection

Viruses disseminate in the CNS by three ways: (1) within the extracellular space; (2) by axonal transport; and (3) via direct cell-to-cell transmission. Infectious agents, including viruses, prions and bacteria, have been shown to spread within axons [38].

Neurovirulent viruses, including herpes simplex, rabies, influenza, and Borna disease viruses, can be anterogradely or retrogradely transported in axons [38, 55]. In some instances, viruses can be transported intra-axonally more than 1 m, yet this journey occurs intracellularly. Therefore, the virus cannot be inactivated by neutralizing antibody during its transit, and may spread in the CNS without inducing an anti-virus immune response while within the cell. When viruses can spread only intra-axonally and/or via direct cell-to-cell contact, they could potentially escape the attack of antiviral drugs or neutralizing antibodies.

Although axonal transport of virus can lead to axonal degeneration [53], neuronal infection and axonal transport of virus may not result in axonal injury. A recombinant virus vector has been shown to be axonally transported in neurons without tissue damage [13]. Conversely, infections in the neurons or axons are not necessarily required to induce axonal injury as seen in the human demyelinating disease, progressive multifocal leukoencephalopathy (PML), which is caused by JC virus infection of oligodendrocytes. Although the lesions of PML are characteristically described as demyelinating, the sparing of axons is only relative and accumulation of APP was detected within the areas of demyelination [28].

Axonal injury with myelin pallor without infection of neurons by human immunodeficiency virus and human T-lymphotropic virus 1

Retrovirus infection also induces axonal injury without infection in the neuronal cell body and axons. Although myelin pallor, multinucleated giant cells, and neuronal loss are well-established pathological findings in human immunodeficiency virus (HIV) encephalitis, axons have long been considered to be unaffected in HIV encephalitis until the terminal stages. By APP immunostaining, axonal damage was demonstrated not only in HIV encephalitis [28, 66], but also in HIV-positive asymptomatic patients [5]. Raja et al. [66] demonstrated that the prevalence and abundance of APP-positive staining axons paralleled the severity or pallor of myelin staining in the cerebral white matter, where oligodendrocytes were neither reduced in number nor infected. Giometto et al. [28] showed that the appearance of the immunostaining varied from globular (or ballooned) structures to bundles of parallel rods [28]. The globular structures co-localized with areas of poor myelin staining in the deep white matter and were indicative of chronic lesions. The presence of bundles was predominantly in the peripheral regions of the white matter, including the gyri, and correlated with acute changes. The authors hypothesized that axonal changes could contribute to retrograde neuronal degeneration and loss, where neurons are not the target of HIV infection. Similarly, Adle-Biassette et al. [2] suggested neuronal apoptosis occurred via axonal retrograde degeneration in HIV infection, since there was a topographical correlation between neuronal apoptosis, microglial activation, and axonal damage.

Human T-lymphotropic virus 1 (HTLV-I) is another retrovirus that causes axonal degeneration and myelin pallor without infection of neurons. Iwasaki [34] reviewed the neuropathology of HTLV-I-associated myelopathy (HAM) or tropical spastic paraparesis (TSP), using myelin and phosphorylated NF staining. In long-standing lesions, both myelin and axons degenerated equally, while tissue appeared spongy due to the swelling of the myelin sheaths with a concomitant preservation of axons at the margin of the lesions. Although HAM/TSP requires differentiation from the spi-

nal form of MS, severe symmetrical degeneration of the lateral funiculi accompanied by wallerian degeneration of long tracts is unique to HAM/TSP and not found in MS [34]. Using APP immunostaining, Umehara et al. [93] also found axonal damage not only in active inflammatory lesions, but also in inactive chronic lesions without any relationship to inflammation. APP-positive staining axons had intact myelin sheaths while myelin abnormality without axonal changes was rarely found. Therefore, the authors suggest that axonal injury is not secondary to demyelination, but the primary instigator.

Axonal transport of virus and demyelination in herpes simplex virus infection

Herpes simplex virus (HSV) type 2 has been reported to be transported axonally and to cause demyelination with minimal axonal damage. HSV 2 can produce multifocal CNS demyelination in infected mice and gray matter lesions, if found, are relatively minor. If neuronal cell bodies are infected, virus subsequently appears in axons and virions are axonally transported. Using electron microscopy, Martin [46] observed virus particles in a very small portion of axons in demyelinating lesions, but not in surrounding zones of normal white matter. Axonal abnormalities were infrequent, relative to the dominant demyelinating pathology. Martin [46] proposed that neuronal infection and axonal transport of virus may lead to foci of oligodendrocyte infection with destruction and CNS demyelination close to or distant from the infected neuronal cell bodies (Fig. 2a). Here, virus may spread cell-to-cell or extracellularly: (1) from an axon to multiple oligodendrocytes via the inner tongue process of the glial sheath; or (2) from the cell body of one oligodendrocyte to the next oligodendrocyte, which are apposed to one another in longitudinally oriented interfascicular rows. Thus, as previously suggested by Martin [46], the relatively minor gray matter lesions in MS may be important in and not secondary to demyelination. As we will discuss later, axonal transport of virus (Fig. 2b) and oligodendrocyte infection (Fig. 2c) are seen in TMEV infection where a similar pathomechanism of lesion development is observed.

Axonal injury and demyelination in mouse hepatitis virus infection

Some viruses, including TMEV and polyomavirus, are known to induce both axonal injury and demyelination. Murine hepatitis virus (MHV) belongs to the genus *Coronavirus*, family *Coronaviridae*. Mice and rats infected with neurotropic strains of MHV (e.g., JHM and A59) develop demyelinating disease, and are used as experimental animal models for MS [31]. Using antibody against nonphosphorylated NF, Dandekar et al. [18] observed a modicum of axonal damage with extensive viral replication, but without demyelination, in MHV-infected RAG1^{-/-} mice that are defective in recombinase activating gene 1 expression, and thus lack mature B or T cells. Adoptive transfer of spleen cells from immune MHV B6 mice into MHV-infected RAG mice resulted in demyelination with increased axonal damage. Macrophages or microglia were abundant in areas of demyelination and axonal damage, but viral antigen was present at lower levels than in mice not receiving transferred immune spleen cells. This suggests that both direct virus infection and MHV-specific immune responses contribute to axonal injury in MHV infection.

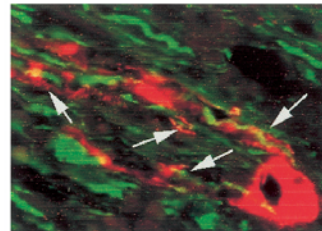
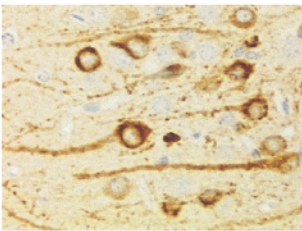
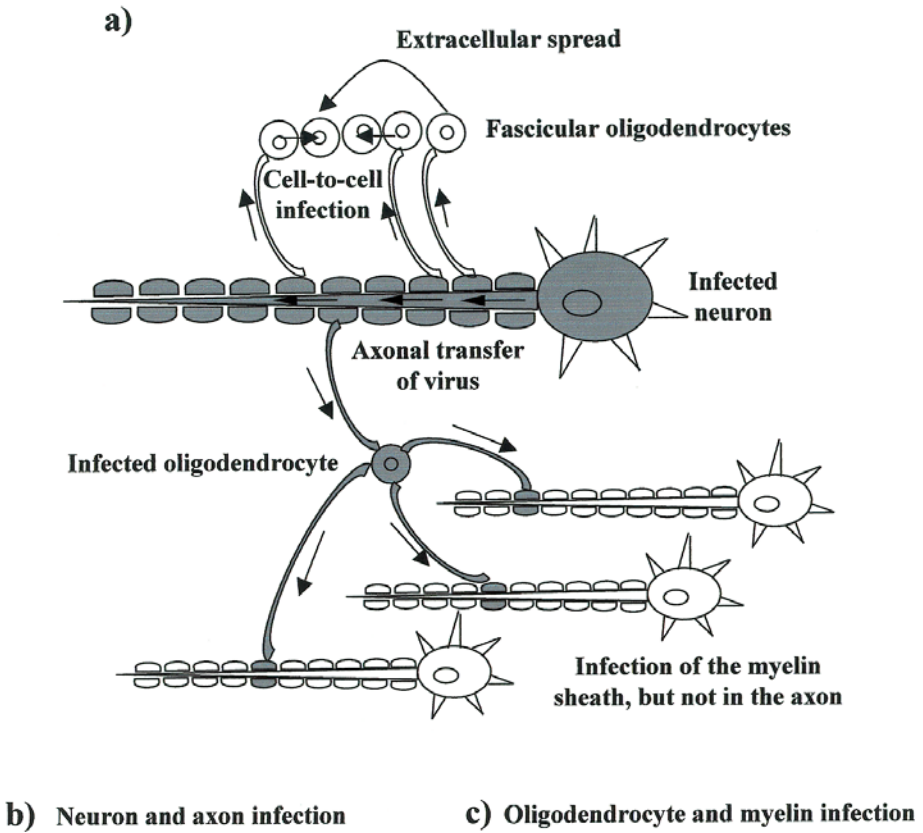


Fig. 2. a Possible mechanisms amplifying the spread of HSV proposed by Martin [46]. Axonally transported virus infects multiple oligodendrocytes; this can result in one single infected axon with demyelination. This leads to spread of virus within interfascicular rows of oligodendrocytes by either cell-to-cell or extracellular infection. Since a single oligodendrocyte wraps multiple axons, this might result in multiple demyelinating myelin sheaths without axonal injury or infection, at least, before virus spreads further from oligodendrocyte to axons. **b** TMEV antigen (*brown*, diaminobenzidine) is detected in axons and cell bodies of neurons in the pyramidal cell layer of the hippocampus during the acute stage of TMEV infection. **c** TMEV antigen (*red*, TRITC) is seen in the cell body of a single oligodendrocyte and its multiple processes and myelin sheaths (*arrows*), 3 weeks after DA virus infection. Virus antigen-positive myelin sheaths wrap axons immunostained with phosphorylated neurofilament (*green*, FITC) (*TMEV*; Theiler's mouse encephalomyelitis virus). **b** $\times 200$, **c** $\times 400$

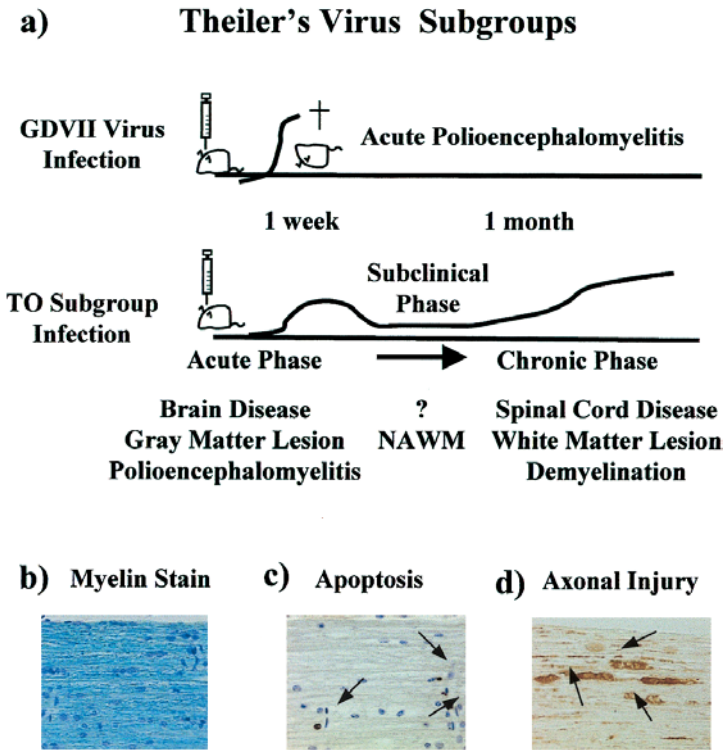


Fig. 3. a TMEV subgroups. GDVII subgroup viruses induce acute fatal polioencephalomyelitis. TO subgroup viruses, including DA and BeAn viruses, cause biphasic disease. During the acute phase, virus infects neurons and causes acute polioencephalomyelitis in the gray matter of the brain. At 1 month after infection (chronic phase), mice develop inflammatory demyelinating disease in the white matter of the spinal cord. During the subclinical stage, 2–4 weeks after infection, minimal or no lesion is detected in the spinal cord white matter by routine myelin or H&E staining (normal appearing white matter; *NAWM*). **b–d** During the acute phase of GDVII virus infection, the spinal cord white matter appears normal by routine myelin staining (**b**). However, oligodendrocyte apoptosis (*arrows*) is evident by the TUNEL method (**c**), and axonal swelling (*arrows*) is visualized by nonphosphorylated neurofilament immunostaining (**d**). (**b–d**) $\times 120$

Theiler's murine encephalomyelitis virus

TMEV is a non-enveloped, icosahedral, positive-sense, single-stranded RNA virus, belonging to the genus *Cardiovirus*, family *Picornaviridae*. TMEV is a common cause of asymptomatic enteric infections in mouse colonies. TMEV is subdivided into two subgroups, GDVII and TO. The GDVII subgroup is neurovirulent and its representative strain is the GDVII virus. The TO subgroup is less virulent, and DA and BeAn viruses are its representative strains. Serological evidence indicates that *Mus musculus* (family *Muridae*, subfamily *Murinae*) is the natural host of TMEV [42], although anti-TMEV antibodies have been detected in a different subfamily *Microtinae*, including meadow, water and bank voles [19].

Disease course in TMEV infection

Intracerebral infection of mice with the GDVII subgroup causes a fatal polioencephalomyelitis [89], and was once widely used as an animal model for poliomyelitis (Fig. 3a). On the other hand, intracerebral infection of mice with the TO subgroup causes a biphasic disease (Fig. 3a). During the acute phase, 1 week after infection, TMEV predominantly infects neurons in the gray matter and causes acute polioencephalomyelitis mainly of the brain. Although infected mice recover from the acute disease, mice develop an inflammatory demyelinating disease in the white matter of the spinal cord 1 month after infection. During this chronic phase, the anterior and lateral columns, including the ventral nerve exit zone, are first involved, and the posterior column changes occur usually as a later event. Here the cuneatus fasciculus is demyelinated, but the gracile fasciculus and the corticospinal tract are relatively spared [92]. Although the reason for the predilection of the cuneatus fasciculus is unclear, this may reflect the observation that small-diameter fibers are relatively preserved compared to larger fibers in TMEV infection [50, 76]. Small diameter axons are present within the corticospinal tract and the center of the posterior column while larger diameter axons comprise the lateral part of the posterior column [56]. In the demyelinating lesion, TMEV has been reported to persist in oligodendrocytes, astrocytes and microglia/macrophages, but not neurons ([61], reviewed in [88]).

Oligodendroglipathy and myelinopathy caused by the TO subgroup of TMEV

In general, virus infection causes damage in the nervous system by two mechanisms: direct infection of neuronal cells and immune-mediated tissue injury, immunopathology. The mechanisms leading to TMEV-induced demyelinating disease are also believed to involve either virus-induced pathology or immunopathology in the CNS, both depending on viral persistence (Table 1). Since oligodendrocytes, the myelin-forming cells, are infected with TMEV during the chronic phase [104], direct lytic infection could result in demyelination. In contrast, virtually all types of immune responses have been proposed to play important roles in the pathogenesis of demyelination and in virus clearance. One possibility is that the demyelination is caused by a similar immune-mediated mechanism to experimental allergic encephalomyelitis (EAE), another animal model of MS, in which CD4⁺ Th1 cells mediate a delayed-

Table 1. Virus- and/or immune-mediated demyelination in Theiler's murine encephalomyelitis virus infection: possible immunopathogenesis in the Outside-In model

Immune effector	Immunopathology
–	Direct virus infection of oligodendrocytes leads to demyelination
CD4 ⁺ Th1 cell	DTH response to virus damages myelin in a bystander fashion Anti-myelin specific Th1 cells generated by antigen spreading
CD8 ⁺ T cell	CD8 ⁺ CTL kills virus-infected oligodendrocytes FasL ⁺ CD8 ⁺ autoreactive cytotoxic cells kill oligodendrocyte
B cell	Anti-virus antibody cross-reacts with myelin lipid, galactocerebroside
Macrophage	Phagocytosis of myelin Release of cytotoxic factors: cytokines, protease, NO metabolites

DTH; delayed-type hypersensitivity

type hypersensitivity response with epitope spreading [52]. TMEV-induced CD8⁺ T cells have been suggested to function as autoreactive cytotoxic cells or regulator cells [73, 85]. Antibody against TMEV cross-reacts with galactocerebroside, and passive transfer of anti-TMEV antibody can augment demyelination in EAE [100]. Intracerebral inoculation with a TMEV-infected macrophage cell line induces acute focal demyelination [89] and depletion of macrophage ameliorates TMEV-induced demyelination [61, 71].

Apoptosis in TMEV infection

Apoptosis is involved in the pathogenesis caused by a variety of viruses such as poliovirus and influenza virus [4, 25, 54, 55]. Accumulating evidence has suggested that apoptosis may serve the innate host defense mechanism against intracellular pathogens, thereby curtailing their further spread to surrounding tissues. On the other hand, because of the post-mitotic nature of neurons, apoptotic neuronal death would result in permanent loss of cerebral functions, precipitating disease. In addition, apoptosis of the oligodendrocyte can lead to demyelination. Oligodendroglial apoptosis has been demonstrated in several demyelinating diseases, including MS [44, 57, 96], EAE, [62, 87] and the twitcher mouse, a murine model of globoid cell leukodystrophy [83]. During the acute stage of both DA (TO subgroup) and GDVII virus infection, both infected and uninfected neurons have been demonstrated to die by apoptosis, using terminal deoxynucleotidyl-transferase-mediated dUTP-biotin nick-end labeling (TUNEL) [91]. The number of apoptotic neurons is much greater in GDVII virus-infected mice than in DA virus infection. Although elimination of virus-infected host cells by apoptosis prior to the assembly of infectious virus could inhibit viral replication, the absence of an inflammatory reaction [4], another feature of apoptosis, may favor viral spread in GDVII virus infection, leading to fatal encephalomyelitis. During the chronic phase of DA virus infection, TUNEL-positive nuclei were co-labeled with oligodendrocyte and macrophage/microglia markers, but not with viral antigen or the astrocyte marker, glial fibrillary acidic protein (GFAP) [74, 91], while TUNEL-positive cells were co-labeled with GFAP in BeAn virus (TO subgroup) infection [60]. Interestingly, oligodendrocyte apoptosis is detected in the white matter as early as 1 week after infection either in GDVII or DA virus infection (Fig. 3d). In vitro TMEV infection results in apoptosis of neurons in explant cultures of the murine cerebellum [6], neuroblastoma cell line [91], macrophage cell lines [27, 35], and microglia [104], but not of astrocytes [104].

Axonal transport of TMEV

TMEV shifts from infection of gray matter in the brain during the acute phase to white matter in the spinal cord during the chronic phase. Although the mechanism of the transition is unknown, one hypothesis is that the virus first spreads from the neuronal cell body of the gray matter to axons in the white matter by axonal transport, and then infects neighboring cells, such as oligodendrocytes and microglia. TMEV has been demonstrated to use axonal transport in vivo. Viral antigens have been detected in axons, dendrites and the neuronal cell body by immunohistochemistry (Fig. 2b). Wada and Fujinami [97] showed that the limbic system is important for the

spread of TMEV in the brain. Using footpad inoculation of mice with the GDVII virus, Martinat et al. [47] showed that GDVII virus infection in the spinal cord was prevented by sectioning the sciatic nerve, and was delayed by treatment with colchicine, which inhibits fast axonal transport. Since viral RNA was first detected in the spinal cord 2 days after footpad inoculation, the authors estimated the rate of transport in the sciatic nerve at approximately 20 mm/day, which is consistent with fast axonal transport.

Axonal injury during the late chronic phase in TMEV infection

Although an early ultrastructural study by Dal Canto and Lipton [17] demonstrated primary demyelination, myelin destruction with intact axons, in SJL/J mice infected with DA virus, they also reported a few dystrophic axons occasionally detected on days 100 and 214 post infection. In this study, it was not shown whether axonal injury was accompanied by mononuclear cell (MNC) infiltration or demyelination. Recently, axonal damage during the late chronic phase of TMEV infection has been studied by Moses Rodriguez's group in SJL/J mice infected for 6–9 months with DA virus (reviewed in [95]). Using plastic-embedded 1- μ m sections, McGavern et al. [50, 51] demonstrated spinal cord atrophy in the anterior and lateral columns, but not in the posterior column. A significant reduction in spinal cord areas was observed at 195–220 days after infection, in which a 25% reduction in the anterior and lateral columns was detected, compared with the 12% area reduction seen at 45 and 92–100 days post infection. A significant decrease in medium to large myelinated axon fibers was also detected in normally myelinated areas on days 195–220. Neurological deficit correlated with demyelination, spinal cord atrophy, and axonal loss in the NAWM. Axonal loss was examined in regions with minimal pathology, because automated calculation of axonal area frequencies was not possible in regions with demyelination or other extensive pathology [51]. Since resistant C57BL/10 mice infected for 195 days showed no spinal cord atrophy compared with uninfected SJL/J mouse spinal cord, the authors suggested that the atrophy was the result of a chronic demyelinating disease, but not the result of neuronal infection during the acute phase, which is seen in both resistant and susceptible mice. Analyzing a single demyelinated spinal cord lesion ultrastructurally, the same group showed results similar to the previous studies [76]. They also found increased intra-axonal mitochondria, which can be an indicator of axonal injury, in normally myelinated, remyelinated, and demyelinated axons. In addition, Ure and Rodriguez [94] demonstrated that retrograde Fluoro-Gold labeling from T11/T12 of rubrospinal, reticulospinal/raphespinal and vestibulospinal neurons was reduced in mice 9 months, but not 1 month, after DA virus infection. They suggested that the majority of neurons in descending populations had lost their normal connectivity to T11/T12, which was either due to axon or neuron degeneration or to functional impairment of retrograde axonal transport. In this study, it is unknown whether DA virus infects these neurons during the acute phase. The precise mechanism of axonal damage during the late chronic phase of TMEV infection is not clear. Rivera-Quinones et al. [67] have suggested a role for major histocompatibility complex (MHC) class I-restricted CD8⁺ T cells in the development of axonal injury, since axons were relatively preserved in class I-deficient mice compared to susceptible SJL/J mice, signifying a role for immune-mediated pathology.

Axonal injury in TMEV infection during the acute and subclinical phases

Although axonal damage has been demonstrated in both MS and TMEV infection, it has been interpreted to be solely secondary to myelin destruction. Recently, however, we demonstrated that the axonal injury heralds demyelination in TMEV infection [90]. Using nonphosphorylated NF immunostaining, we found obvious axonal injury in the white matter of the spinal cord of DA virus-infected mice 2 weeks post infection, approximately 2 weeks earlier than the onset of demyelination. The number and distribution of damaged axons correlated with that of microglia/macrophages, but not that of viral antigen. During this subclinical phase, prior to the onset of clinical signs and demyelination, axonal injury was seen in regions where subsequent demyelination usually occurs such as the ventral root exit zone [87]. Similarly axonal damage was rarely seen in the posterior column where demyelination is not usually observed [92]. In GDVII virus infection, severe axonal damage was observed in NAWM within 1 week post infection (Fig. 3b,d). The distribution of damaged axons in the white matter did not correlate with the presence of T cells or viral antigens, which was mainly present in the gray matter. This suggests that neither T cells nor direct virus attack on axons is necessary for the induction of axonal injury. Axonal damage was also detected without myelin damage *in vitro* in myelinated mouse cerebellar explant cultures infected with DA variant Ds [6].

We do not know whether the axonal damage in this early phase of TMEV infection is permanent or reversible; functional axonal damage would not necessarily be followed by fragmentation and degeneration. An et al. [5] found accumulation of APP in the CNS of HIV-positive individuals without AIDS. They suggested that this axonal damage might be reversible and the axonal flow re-established and the accumulation of APP could disappear. It appears that HIV dementia can partially be reversed and brain metabolic changes visible on MRS in AIDS patients disappear after retroviral treatment [28].

Mechanisms of axonal injury and demyelination, Inside-Out and Outside-In models

During the preclinical stage of TMEV infection, axonal injury and oligodendrocyte apoptosis with microglia activation can be seen only after special staining techniques in otherwise NAWM. Unexpectedly, this situation parallels in some aspects the pathological changes observed in SCI.

Oligodendrocyte apoptosis after spinal cord injury

The initial mechanical tissue disruption of SCI is followed by a period of secondary injury that increases the size of the lesion. This includes chronic demyelination of fiber tracts away from the injury [9, 10]. During the acute stage, a central region of hemorrhagic necrosis characterizes the lesion. Later time periods, however, are characterized by the apoptosis of a substantial number of oligodendrocytes, which occurs along the fiber tracts undergoing wallerian degeneration extending into regions far remote from the lesion [1, 15] (Fig. 4). The oligodendrocyte death seems to be associated with axonal degeneration induced by the injury. The later stage lasts for a surprisingly long time, at least 3 weeks [98].

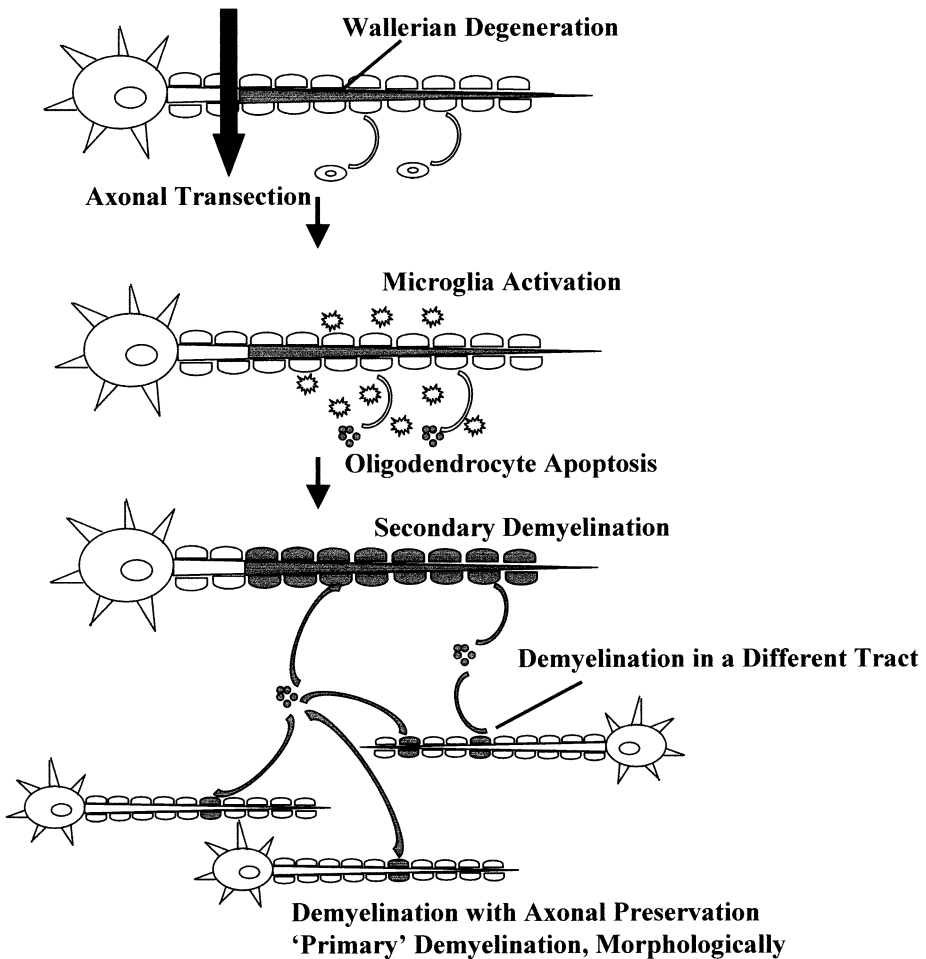


Fig. 4. Axonal injury and delayed oligodendrocyte apoptosis in SCI. SCI induces axonal degeneration at the distal part of the spinal cord from the transection site. Along the fiber tracts undergoing wallerian degeneration, microglial activation and oligodendrocyte apoptosis can be detected even in the regions far remote from the transection site. Oligodendrocyte apoptosis can lead to demyelination of not only transected axons but also intact axons, since a single oligodendrocyte myelinates multiple axons. In the latter case, demyelinated axons can appear as typical ‘primary’ demyelination,’ morphologically. In areas where ascending and descending fiber tracts are intermixed, both tracts may undergo demyelination, if apoptosis occurs in individual oligodendrocytes that ensheath multiple axons in both groups (SCI; spinal cord injury)

Since apoptotic oligodendrocytes are sometimes directly apposed by activated microglia, the oligodendrocyte apoptosis may be due to toxic factors from the microglia, such as tumor necrosis factor (TNF)- α . However, it is not known whether oligodendrocyte death or microglial activation comes first. Microglia can also show condensed and fragmented nuclei that are positive for TUNEL [79]. Some of these profiles might represent microglia that have phagocytosed apoptotic bodies from other cells or apoptosis of microglia, resulting in controlling microglial number. TUNEL-positive microglia/macrophages are also detected in TMEV infection [91].

The mechanism of oligodendrocyte apoptosis is unclear and still controversial. Saito et al. [75] showed the expression of apoptosis-related molecules, p53, p21, Bcl-2, and Bax, as early as 30 min after experimental SCI. Another hypothesis for the oligodendrocyte death is glutamate-mediated excitotoxicity. In an in vitro model of isolated rat dorsal column compression, Li et al. [41] demonstrated a toxic efflux of glutamate through the reversal of Na⁺-dependent glutamate transport, most likely occurring from axons. They also showed that myelin damage was prevented by glutamate receptor blockade or glutamate transport inhibitors, suggesting that glutamate spillover from the lesion can damage oligodendrocytes [41]. Oligodendrocytes are known to be vulnerable to excitotoxic signals mediated by glutamate receptors (AMPA and kainite) [49].

The apoptosis of oligodendrocytes could lead to demyelination of not only damaged axons but also intact axons, since a single oligodendrocyte myelinates multiple axons. Indeed, demyelinating axons that appear ultrastructurally intact are present after SCI. This is the typical neuropathology of 'primary' demyelination, but not of myelin damage 'secondary' to axonal trauma [63].

Cross-talk between axon and oligodendrocyte

An alternative mechanism for oligodendrocyte apoptosis in SCI is that the oligodendrocyte may respond to loss of trophic elements from axons as axons undergo degeneration. Clinical and experimental evidence support the hypothesis that a failure of cell communication between the axon and oligodendrocyte is involved in axonal or oligodendroglial pathology [3]. In the PNS, demyelination in uremic neuropathy and Friedreich ataxia may well be axonally induced [20]. Similar cellular events occur in experimental permanent axotomy in cats where nerves proximal to the permanent axotomy sequentially undergo axonal atrophy and myelin wrinkling. This is followed by secondary segmental demyelination, and finally myelin ovoid and ball formation [20].

The survival of the oligodendrocyte depends on the presence of axons at least during development [8]. Apoptosis of oligodendrocytes occurs selectively in transected neonatal optic nerves in which the axons degenerate [65]. The cell death does not occur in optic nerves from C57BL/Wld mice, wallerian degeneration slow mutant mice (formerly known as C57BL/Ola) [65], which show prolonged survival of the distal stumps of transected axons. This prevents the normal influx of monocytes into transected nerves in both the CNS and PNS. Purified neurons, but not neuron-conditioned culture medium, promote the survival of purified oligodendrocytes in vitro [65]. Therefore, the axonal signal that regulates oligodendrocyte survival is contact mediated. This supports the hypothesis that there is competition for axon-dependent survival signals by oligodendrocytes that normally helps adjust the number of oligodendrocytes to the number of axons that require myelination.

Conversely, Griffiths et al. [30] suggested that myelinated axons could require local oligodendrocyte support. Although myelin proteolipid proteins (PLP) and its DM20 isoform are the major membrane proteins of CNS myelin, the *Plp* gene knockout mice develop normally and assemble compacted myelin with morphologically normal oligodendrocytes. Unexpectedly, the mice develop widespread axonal swellings and degeneration, associated with predominantly small-caliber nerve fibers. The authors hypothesized that glial ensheathment provides a necessary signal that induces the axonal dependency on glial support [30]. Mutations of the *Plp* gene cause the dysmyelinating diseases Pelizaeus-Merzbacher disease and spastic paraplegia type-2 in

man [77, 102]. In TMEV infection, a decrease in PLP mRNA expression not only in infected but also uninfected oligodendrocytes in the spinal cord has been reported [58, 59, 70, 101]. Oligodendrocytes have also been suggested to play a role in maintaining normal axons during development [11].

Demyelination develops from outside to inside, or from inside to outside?

If the initial step of demyelination is either the loss of contact between the axon and the oligodendrocyte or cell-to-cell transmission of virus from the axon to the oligodendrocyte, lesions are most likely to be seen first in the innermost part of myelin, the inner loop. However, oligodendrocyte damage can also result in degeneration in the most distal part as suggested by a dying-back process. In the demyelinating disease induced by Cuprizone, oligodendrocytes can undergo a dying-back process, with degeneration starting in the most distal part, the inner loop of the oligodendrocyte cell processes. This eventually progresses proximally to involve the perikaryon, with resulting demyelination (dying-back (oligodendro)gliopathy, [45]). Rodriguez [68] demonstrated a similar ultrastructural disease picture during the early stages of DA virus infection (11, 28, 45 days after infection) prior to the degeneration of the myelin sheaths. Although ultrastructural abnormalities were seen in the inner oligodendroglial loops, viral antigen was expressed in both the inner and outer loops [69]. Using electron microscopy, Rodriguez et al. [72] found a widening of the inner myelin lamellae and degeneration of the inner glial loops in biopsy brain specimens from clinically definite MS patients. The presence of early degeneration in the inner myelin sheaths and in the glial loops of oligodendrocytes was noted in most biopsy specimens. Such changes were not described in biopsy cases of MS by others [82]. Kirk [36] also demonstrated vesicular degeneration most frequently in the inner myelin sheaths in a single case of SP-MS. A similar observation was made in myelin-associated glycoprotein (MAG)-deficient mice [40]. In MS lesions, loss of immunoreactivity against MAG is seen in NAWM [33]. Since MAG is localized in periaxonal regions of the myelinated fiber, this finding also supports the hypothesis that the damage in the inner loops precedes that of myelin or oligodendrocytes.

In contrast, Dal Canto and Lipton [17] suggested that demyelination in TMEV infection develops from the outside to inside, demonstrating vesicular disruption at not only the inner but also the outer border of myelin sheaths due to stripping of myelin by invading MNC, as seen in EAE [39]. In support of this, Dal Canto and Barbano [16] found preferential disappearance of myelin basic protein (MBP) compared to MAG. The disappearance of MAG never preceded that of MBP in demyelinating lesions. A uniform widening of the myelin lamellae beginning with the outer layer has been observed in some, but not all [86], immune-mediated demyelinating diseases of the PNS and CNS, including paraproteinemic neuropathy [64] and EAE [39], respectively. Therefore, in TMEV infection, there is an apparent paradox. Does lesion development progress from the inside to the outside, or from the outside to the inside?

Inside-Out and Outside-In models

We have reviewed the evidence that axonal injury can lead to demyelination, where the lesion develops from the inside to the outside. A model for lesion development in

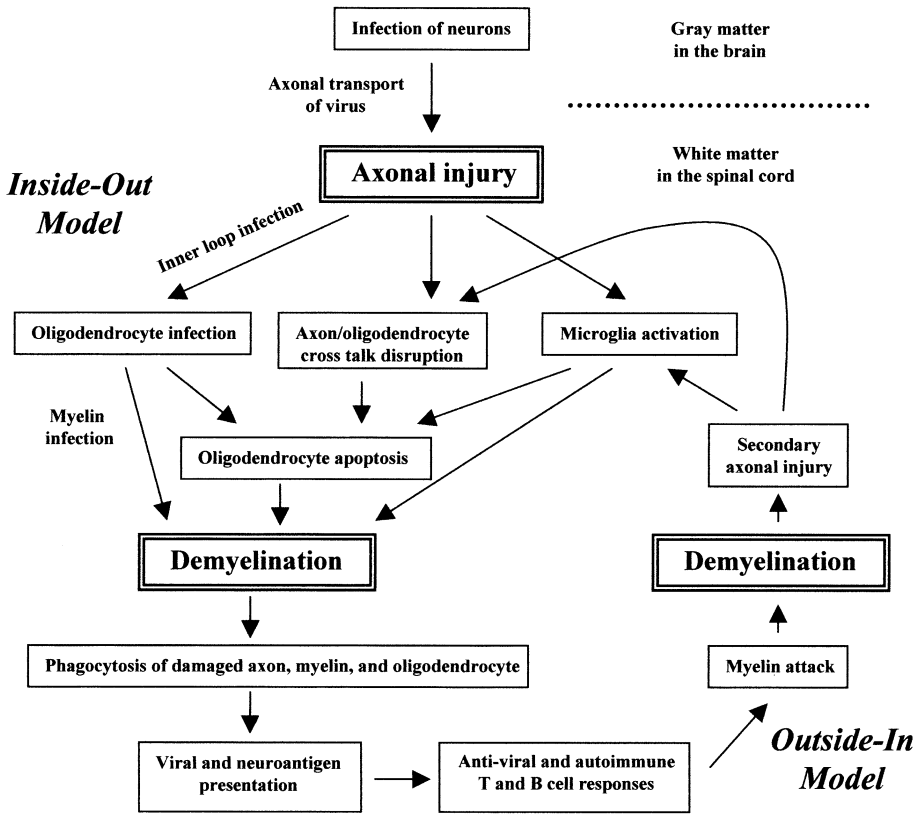


Fig. 5. Inside-Out and Outside-In models in TMEV infection. The lesion first develops from the inside to the outside. TMEV infects neurons in the gray matter of the brain, and is transported axonally, leading to axonal injury in the white matter of the spinal cord. Virus further infects the inner loop of the myelin, and spreads centripetally to the oligodendrocyte cell body, from which it spreads centrifugally to multiple myelin sheaths, resulting in oligodendrocyte apoptosis and demyelination. Axonal injury disrupts cross-talk between the axon and the oligodendrocyte and induces microglia activation, contributing to oligodendrocyte apoptosis and demyelination. Activated microglia/macrophages phagocytose damaged and/or infected axons, myelin, and oligodendrocytes and present viral and neuroantigens. At this time point, the lesion develops from the outside to the inside. Autoimmune and anti-viral immune responses attack myelin specifically or in a bystander fashion, causing primary demyelination. Severe inflammatory reactions further damage axons secondarily, which results in wallerian degeneration in the distal part of the axonal transection sites. This secondary axonal injury triggers the second cascade reaction of demyelination, forming a vicious cycle

TMEV infection with this Inside-Out model is presented in Fig. 5. TMEV infects neurons in the gray matter of the brain and induces degeneration in their processes, the axons, in descending tracts that run mainly in the anterior and lateral columns of the spinal cord. Here, induction of axonal degeneration can be protective to the host, since this will prevent virus from spreading axonally. TMEV is transported axonally which may result in axonal damage. Axonal transport could also lead to direct cell-to-cell infection at the inner loop of myelin that attaches to the axon. TMEV can further spread centripetally from a distally infected site to the oligodendrocyte body. Since a single oligodendrocyte myelinates multiple axons, TMEV will spread centrifugally, at

this stage, from the oligodendrocyte cell body to its distal processes, then to myelin sheaths, and eventually to axons again. Fascicular oligodendrocytes are located close to each other, and this will also contribute to spread from one oligodendrocyte to the other. Infected oligodendrocytes and myelin will be phagocytosed by microglia/macrophages, resulting in demyelination and persistent infection in and/or viral antigen presentation by microglia/macrophages. On the other hand, axonal degeneration itself induces oligodendrocyte apoptosis either by activation of microglia or the loss of support from axons. In most areas of white matter in the lateral and anterior columns, ascending and descending fiber tracts are not discrete bundles but are intermixed or overlapped so that individual oligodendrocytes ensheath axons in both groups. If either the ascending or descending fiber tracts degenerate to the extent where an oligodendrocyte undergoes apoptosis from loss of trophic support, axons that survived the initial injury may undergo demyelination. Activated microglia will release toxic cytokines, such as TNF, and this too will enhance demyelination.

At this time point, lesions can develop from the Outside-In (Table 1), although the original lesion developed from the Inside-Out. Activated microglia/macrophages phagocytose degenerated oligodendrocytes, myelin and axons, whether they are infected with TMEV or not. Then, microglia can produce chemokines and up-regulate adhesion molecules in the CNS, leading to recruitment of T cells. T cells will recognize neuroantigens or viral antigens presented by the activated microglia/macrophages. This will lead to a delayed-type hypersensitivity response to virus or induction of anti-myelin autoimmunity via antigen spreading. CNS tissue damage could also result in the release of neuroantigens into the systemic circulation that would also contribute to further induction of autoimmune T cell and B cell responses. These autoimmune T cells and autoantibodies might attack myelin from the Outside-In. Therefore, the Inside-Out and Outside-In models are not mutually exclusive and may act in synergy.

Conclusions

In this review, we proposed a new model for the pathogenesis of demyelinating diseases, Inside-Out model, in which lesions develop from the inside to the outside; primary axonal injury triggers demyelination that leads to immunopathology. If virus is transported by the axons, this will lead to infection in neighboring cells, including oligodendrocytes and macrophages, contributing to lesion development. After initial destruction, virus antigen and neuroantigen will be released and presented by CNS antigen presenting cells, resulting in the induction of delayed-type hypersensitivity responses and autoimmunity. At this time point, the myelin is attacked from the outside, leading to secondary axonal injury (Outside-In model). Thus, the Inside-Out and Outside-In models can collaborate in a vicious cycle or initiate a cascade of events. Therapeutic strategies targeting each step, including axonal injury, inflammation and demyelination, in these models will be important to prevent disease progression, particularly in primary and secondary progressive MS, and their animal model, TMEV infection.

Acknowledgements. The authors would like to thank Jane E. Libbey, MS, for many helpful discussions, Li-Qing Kuang, MD, Jana L. Blackett, BS, and Isaac Z. M. Igenge for their technical assistance. We are grateful to Ms. Kathleen Borick for preparation of the manuscript. This was supported by the NIH grant NS34497.

References

1. Abe Y, Yamamoto T, Sugiyama Y, et al (1999) Apoptotic cells associated with Wallerian degeneration after experimental spinal cord injury: a possible mechanism of oligodendroglial death. *J Neurotrauma* 16:945
2. Adle-Biassette H, Chrétien F, Wingertsmann L, et al (1999) Neuronal apoptosis does not correlate with dementia in HIV infection but is related to microglial activation and axonal damage. *Neuropathol Appl Neurobiol* 25:123
3. Allt G, Ghabriel MN (1982) Demyelination: a failure of cell communication? *J Neurol Sci* 57:287
4. Ammendolia MG, Tinari A, Calcabrini A, et al (1999) Poliovirus infection induces apoptosis in CaCo-2 cells. *J Med Virol* 59:122
5. An SF, Giometto B, Groves M, et al (1997) Axonal damage revealed by accumulation of β -APP in HIV-positive individuals without AIDS. *J Neuropathol Exp Neurol* 56:1262
6. Anderson R, Harting E, Frey MS, et al (2000) Theiler's murine encephalomyelitis virus induces rapid necrosis and delayed apoptosis in myelinated mouse cerebellar explant cultures. *Brain Res* 868:259
7. Atkins GJ, McQuaid S, Morris-Downes MM, et al (2000) Transient virus infection and multiple sclerosis. *Rev Med Virol* 10:291
8. Barres BA, Raff MC (1999) Axonal control of oligodendrocyte development. *J Cell Biol* 147:1123
9. Beattie MS, Farooqui AA, Bresnahan JC (2000) Review of current evidence for apoptosis after spinal cord injury. *J Neurotrauma* 17:915
10. Beattie MS, Li Q, Bresnahan JC (2000) Cell death and plasticity after experimental spinal cord injury. *Prog Brain Res* 128:9
11. Bernstein M, Lichtman JW (1999) Axonal atrophy: the retraction reaction. *Curr Opin Neurobiol* 9:364
12. Bjartmar C, Kinkel RP, Kidd G, et al (2001) Axonal loss in normal-appearing white matter in a patient with acute MS. *Neurology* 57:1248
13. Cayouette M, Gravel C (1996) Adenovirus-mediated gene transfer to retinal ganglion cells. *Invest Ophthalmol Vis Sci* 37:2022
14. Chowdhury D, Arora A (2001) Axonal Guillain-Barré syndrome: a critical review. *Acta Neurol Scand* 103:267
15. Crowe MJ, Bresnahan JC, Shuman SL, et al (1997) Apoptosis and delayed degeneration after spinal cord injury in rats and monkeys. *Nat Med* 3:73
16. Dal Canto MC, Barbano RL (1985) Immunocytochemical localization of MAG, MBP and P₀ protein in acute and relapsing demyelinating lesions of Theiler's virus infection. *J Neuroimmunol* 10:129
17. Dal Canto MC, Lipton HL (1975) Primary demyelination in Theiler's virus infection. An ultrastructural study. *Lab Invest* 33:626
18. Dandekar AA, Wu GF, Pewe L, et al (2001) Axonal damage is T cell mediated and occurs concomitantly with demyelination in mice infected with a neurotropic coronavirus. *J Virol* 75:6115
19. Descôteaux JP, Mihok S (1986) Serologic study on the prevalence of murine viruses in a population of wild meadow voles (*Microtus pennsylvanicus*). *J Wildl Dis* 22:314
20. Dyck PJ, Nukada H, Lais AC, et al (1984) Permanent axonotomy: a model of chronic neuronal degeneration preceded by axonal atrophy, myelin remodeling, and degeneration. In: Dyck PJ, Thomas PK, Lambert EH, Bunge R (eds) *Peripheral neuropathy*. Saunders, Philadelphia, pp 666–690
21. Evans OB, Vedanarayanan V (1997) Guillain-Barré syndrome. *Pediatr Rev* 18:10
22. Feasby TE, Gilbert JJ, Brown WF, et al (1986) An acute axonal form of Guillain-Barré polyneuropathy. *Brain* 109:1115
23. Ferguson B, Matyszak MK, Esiri MM, et al (1997) Axonal damage in acute multiple sclerosis lesions. *Brain* 120:393
24. Fu L, Matthews PM, De Stefano N, et al (1998) Imaging axonal damage of normal-appearing white matter in multiple sclerosis. *Brain* 121:103
25. Fujimoto I, Pan J, Takizawa T, et al (2000) Virus clearance through apoptosis-dependent phagocytosis of influenza A virus-infected cells by macrophages. *J Virol* 74:3399
26. Fujinami RS, Libbey JE (1999) Endogenous retroviruses: are they the cause of multiple sclerosis? *Trends Microbiol* 7:263
27. Ghadge GD, Ma L, Sato S, et al (1998) A protein critical for a Theiler's virus-induced immune system-mediated demyelinating disease has a cell type-specific antiapoptotic effect and a key role in virus persistence. *J Virol* 72:8605

28. Giometto B, An SF, Groves M, et al (1997) Accumulation of β -amyloid precursor protein in HIV encephalitis: Relationship with neuropsychological abnormalities. *Ann Neurol* 42:34
29. Griffin JW, Li CY, Ho TW, et al (1996) Pathology of the motor-sensory axonal Guillain-Barré syndrome. *Ann Neurol* 39:17
30. Griffiths I, Klugmann M, Anderson T, et al (1998) Axonal swellings and degeneration in mice lacking the major proteolipid of myelin. *Science* 280:1610
31. Houtman JJ, Fleming JO (1996) Pathogenesis of mouse hepatitis virus-induced demyelination. *J NeuroVirol* 2:361
32. Ikuta F, Zimmerman HM (1976) Distribution of plaques in seventy autopsy cases of multiple sclerosis in the United States. *Neurology* 26:26
33. Itoyama Y, Sternberger NH, Webster HD, et al (1980) Immunocytochemical observations on the distribution of myelin-associated glycoprotein and myelin basic protein in multiple sclerosis lesions. *Ann Neurol* 7:167
34. Iwasaki Y (1990) Pathology of chronic myelopathy associated with HTLV-I infection (HAM/TSP). *J Neurol Sci* 96:103
35. Jelachich ML, Lipton HL (1999) Restricted Theiler's murine encephalomyelitis virus infection in murine macrophages induces apoptosis. *J Gen Virol* 80:1701
36. Kirk J (1979) The fine structure of the CNS in multiple sclerosis. II. Vesicular demyelination in an acute case. *Neuropathol Appl Neurobiol* 5:289
37. Kornek B, Lassmann H (1999) Axonal pathology in multiple sclerosis. A historical note. *Brain Pathol* 9:651
38. Kristensson K (1996) Sorting signals and targeting of infectious agents through axons: an annotation to the 100 years' birth of the name "axon". *Brain Res Bull* 41:327
39. Lampert P, Carpenter S (1965) Electron microscopic studies on the vascular permeability and the mechanism of demyelination in experimental allergic encephalomyelitis. *J Neuropathol Exp Neurol* 24:11
40. Lassmann H, Bartsch U, Montag D, et al (1997) Dying-back oligodendroglial pathology: a late sequel of myelin-associated glycoprotein deficiency. *Glia* 19:104
41. Li S, Mealing GA, Morley P, et al (1999) Novel injury mechanism in anoxia and trauma of spinal cord white matter: glutamate release via reverse Na^+ -dependent glutamate transport. *J Neurosci* 19:RC16
42. Lipton HL, Kim BS, Yahikozawa H, et al (2001) Serological evidence that *Mus musculus* is the natural host of Theiler's murine encephalomyelitis virus. *Virus Res* 76:79
43. Lovas G, Szilágyi N, Majtényi K, et al (2000) Axonal changes in chronic demyelinated cervical spinal cord plaques. *Brain* 123:308
44. Lucchinetti CF, Bruck W, Rodriguez M, et al (1996) Distinct patterns of multiple sclerosis pathology indicates heterogeneity on pathogenesis. *Brain Pathol* 6:259
45. Ludwin SK, Johnson ES (1981) Evidence for a "dying-back" gliopathy in demyelinating disease. *Ann Neurol* 9:301
46. Martin JR (1984) Intra-axonal virus in demyelinating lesions of experimental herpes simplex type 2 infection. *J Neurol Sci* 63:63
47. Martinat C, Jarousse N, Prévost MC, et al (1999) The GDVII strain of Theiler's virus spreads via axonal transport. *J Virol* 73:6093
48. Matthews PM, De Stefano N, Narayanan S, et al (1998) Putting magnetic resonance spectroscopy studies in context: axonal damage and disability in multiple sclerosis. *Semin Neurol* 18:327
49. Matute C, Alberdi E, Domercq M, et al (2001) The link between excitotoxic oligodendroglial death and demyelinating diseases. *Trends Neurosci* 24:224
50. McGavern DB, Murray PD, Rivera-Quinones C, et al (2000) Axonal loss results in spinal cord atrophy, electrophysiological abnormalities and neurological deficits following demyelination in a chronic inflammatory model of multiple sclerosis. *Brain* 123:519
51. McGavern DB, Murray PD, Rodriguez M (1999) Quantitation of spinal cord demyelination, remyelination, atrophy, and axonal loss in a model of progressive neurologic injury. *J Neurosci Res* 58:492
52. Miller SD, Vanderlugt CL, Begolka WS, et al (1997) Persistent infection with Theiler's virus leads to CNS autoimmunity via epitope spreading. *Nat Med* 3:1133
53. Minguetti G, Hofmeister RM, Hayashi Y, et al (1997) Ultrastructure of cranial nerves of rats inoculated with rabies virus. *Arq Neuropsiquiatr* 55:680
54. Mori I, Kimura Y (2000) Apoptotic neurodegeneration induced by influenza A virus infection in the mouse brain. *Microbes Infect* 2:1329

55. Mori I, Kimura Y (2001) Neuropathogenesis of influenza virus infection in mice. *Microbes Infect* 3:475
56. Olby NJ, Blakemore WF (1996) Primary demyelination and regeneration of ascending axons in the dorsal funiculus of the rat spinal cord following photochemically induced injury. *J Neurocytol* 25:465
57. Ozawa K, Suchanek G, Breitschopf H, et al (1994) Patterns of oligodendroglia pathology in multiple sclerosis. *Brain* 117:1311
58. Ozden S, Aubert C, Bureau JF, et al (1993) Analysis of proteolipid protein and P₀ transcripts in mice infected with Theiler's virus. *Microb Pathog* 14:123
59. Ozden S, Aubert C, Gonzalez-Dunia D, et al (1991) In situ analysis of proteolipid protein gene transcripts during persistent Theiler's virus infection. *J Histochem Cytochem* 39:1305
60. Palma JP, Yauch RL, Lang S, et al (1999) Potential role of CD4⁺ T cell-mediated apoptosis of activated astrocytes in Theiler's virus-induced demyelination. *J Immunol* 162:6543
61. Pena Rossi C, Delcroix M, Huitinga I, et al (1997) Role of macrophages during Theiler's virus infection. *J Virol* 71:3336
62. Pender MP, Nguyen KB, McCombe PA, et al (1991) Apoptosis in the nervous system in experimental allergic encephalomyelitis. *J Neurol Sci* 104:81
63. Popovich PG, Stokes BT, Whitacre CC (1996) Concept of autoimmunity following spinal cord injury: possible roles for T lymphocytes in the traumatized central nervous system. *J Neurosci Res* 45:349
64. Powell HC, Rodriguez M, Hughes RAC (1984) Microangiopathy of vasa nervorum in dysglobulinemic neuropathy. *Ann Neurol* 15:386
65. Raff MC, Barres BA, Burne JF, et al (1993) Programmed cell death and the control of cell survival: lessons from the nervous system. *Science* 262:695
66. Raja F, Sherriff FE, Morris CS, et al (1997) Cerebral white matter damage in HIV infection demonstrated using β -amyloid precursor protein immunoreactivity. *Acta Neuropathol* 93:184
67. Rivera-Quiñones C, McGavern D, Schmelzer JD, et al (1998) Absence of neurological deficits following extensive demyelination in a class I-deficient murine model of multiple sclerosis. *Nat Med* 4:187
68. Rodriguez M (1985) Virus-induced demyelination in mice: "dying back" of oligodendrocytes. *Mayo Clin Proc* 60:433
69. Rodriguez M, Leibowitz JL, Lampert PW (1983) Persistent infection of oligodendrocytes in Theiler's virus-induced encephalomyelitis. *Ann Neurol* 13:426
70. Rodriguez M, Prayoonwiwat N, Howe C, et al (1994) Proteolipid protein gene expression in demyelination and remyelination of the central nervous system: a model for multiple sclerosis. *J Neuropathol Exp Neurol* 53:136
71. Rodriguez M, Qudus J (1986) Effect of cyclosporin A, silica quartz dust, and protease inhibitors on virus-induced demyelination. *J Neuroimmunol* 13:159
72. Rodriguez M, Scheithauer BW, Forbes G, et al (1993) Oligodendrocyte injury is an early event in lesions of multiple sclerosis [Comment: Ebers GC (1993) Multiple sclerosis: New insights from old tools. *Mayo Clin Proc* 68:711]. *Mayo Clin Proc* 68:627
73. Rodriguez M, Sriram S (1988) Successful therapy of Theiler's virus-induced demyelination (DA strain) with monoclonal anti-Lyt-2 antibody. *J Immunol* 140:2950
74. Rose JW, Hill KE, Wada Y, et al (1998) Nitric oxide synthase inhibitor, aminoguanidine, reduces inflammation and demyelination produced by Theiler's virus infection. *J Neuroimmunol* 81:82
75. Saito N, Yamamoto T, Watanabe T, et al (2000) Implications of p53 protein expression in experimental spinal cord injury. *J Neurotrauma* 17:173
76. Sathornsumetee S, McGavern DB, Ure DR, et al (2000) Quantitative ultrastructural analysis of a single spinal cord demyelinated lesion predicts total lesion load, axonal loss, and neurological dysfunction in a murine model of multiple sclerosis. *Am J Pathol* 157:1365
77. Seitelberger F (1995) Neuropathology and genetics of Pelizaeus-Merzbacher disease. *Brain Pathol* 5:267
78. Sharma R, Narayana PA, Wolinsky JS (2001) Grey matter abnormalities in multiple sclerosis: proton magnetic resonance spectroscopic imaging. *Mult Scler* 7:221
79. Shuman SL, Bresnahan JC, Beattie MS (1997) Apoptosis of microglia and oligodendrocytes after spinal cord contusion in rats. *J Neurosci Res* 50:798
80. Silber E, Sharief MK (1999) Axonal degeneration in the pathogenesis of multiple sclerosis. *J Neurol Sci* 170:11
81. Simon JH (1999) From enhancing lesions to brain atrophy in relapsing MS. *J Neuroimmunol* 98:7

82. Suzuki K, Andrews JM, Waltz JM, et al (1969) Ultrastructural studies of multiple sclerosis. *Lab Invest* 20:444
83. Taniike M, Mohri I, Eguchi N, et al (1999) An apoptotic depletion of oligodendrocytes in the twitcher, a murine model of globoid cell leukodystrophy. *J Neuropathol Exp Neurol* 58:644
84. Trapp BD, Peterson J, Ransohoff RM, et al (1998) Axonal transection in the lesions of multiple sclerosis. *N Engl J Med* 338:278
85. Tsunoda I, Cannon TS, Fujinami RS (1999) Splenic autoreactive cytotoxic response in Theiler's murine encephalomyelitis virus (TMEV) infection. Abstracts of the American Society for Virology, 18th Annual Meeting, University of Massachusetts, July 10–14, 1999. ASV, Amherst, p 79
86. Tsunoda I, Endo K, Hirayama K, et al (1995) POEMS syndrome with central nervous system involvement: a case report. *Fukushima J Med Sci* 41:61
87. Tsunoda I, Fujinami RS (1996) Two models for multiple sclerosis: experimental allergic encephalomyelitis and Theiler's murine encephalomyelitis virus. *J Neuropathol Exp Neurol* 55:673
88. Tsunoda I, Fujinami RS (1999) Theiler's murine encephalomyelitis virus. In: Ahmed R, Chen I (eds) *Persistent viral infections*. John Wiley & Sons Ltd, Chichester, pp 517–536
89. Tsunoda I, Iwasaki Y, Terunuma H, et al (1996) A comparative study of acute and chronic diseases induced by two subgroups of Theiler's murine encephalomyelitis virus. *Acta Neuropathol* 91:595
90. Tsunoda I, Kuang L-Q, Libbey JE, et al (2002) Axonal injury heralds demyelination in Theiler's murine encephalomyelitis virus infection, animal model for multiple sclerosis. Proceeding of the American Society for Microbiology, Salt Lake City, May 20, 2002. 102nd General Meeting ASM Press, p 474
91. Tsunoda I, Kurtz CIB, Fujinami RS (1997) Apoptosis in acute and chronic central nervous system disease induced by Theiler's murine encephalomyelitis virus. *Virology* 228:388
92. Tsunoda I, Tolley ND, Theil DJ, et al (1999) Exacerbation of viral and autoimmune animal models for multiple sclerosis by bacterial DNA. *Brain Pathol* 9:481
93. Umehara F, Abe M, Koreeda Y, et al (2000) Axonal damage revealed by accumulation of β -amyloid precursor protein in HTLV-I-associated myelopathy. *J Neurol Sci* 176:95
94. Ure D, Rodriguez M (2000) Extensive injury of descending neurons demonstrated by retrograde labeling in a virus-induced murine model of chronic inflammatory demyelination. *J Neuropathol Exp Neurol* 59:664
95. Ure DR, McGavern DB, Sathornsumetee S, et al (2001) The contribution of axonal injury to neurologic dysfunction in Theiler's virus-induced inflammatory demyelinating disease. In: Hommes OR, Clanet M, Wekerle H (eds) *Genes and viruses in multiple sclerosis*. Elsevier, Amsterdam, pp 79–88
96. Vartanian T, Li Y, Zhao M, et al (1995) Interferon- γ -induced oligodendrocyte cell death: implications for the pathogenesis of multiple sclerosis. *Mol Med* 1:732
97. Wada Y, Fujinami RS (1993) Viral infection and dissemination through the olfactory pathway and the limbic system by Theiler's virus. *Am J Pathol* 143:221
98. Warden P, Bamber NI, Li H, et al (2001) Delayed glial cell death following wallerian degeneration in white matter tracts after spinal cord dorsal column cordotomy in adult rats. *Exp Neurol* 168:213
99. Wunschmann A, Alldinger S, Kremmer E, et al (1999) Identification of CD4⁺ and CD8⁺ T cell subsets and B cells in the brain of dogs with spontaneous acute, subacute-, and chronic-demyelinating distemper encephalitis. *Vet Immunol Immunopathol* 67:101
100. Yamada M, Zurbriggen A, Fujinami RS (1990) Monoclonal antibody to Theiler's murine encephalomyelitis virus defines a determinant on myelin and oligodendrocytes, and augments demyelination in experimental allergic encephalomyelitis. *J Exp Med* 171:1893
101. Yamada M, Zurbriggen A, Fujinami RS (1990) The relationship between viral RNA, myelin-specific mRNAs, and demyelination in central nervous system disease during Theiler's virus infection. *Am J Pathol* 137:1467
102. Yool DA, Edgar JM, Montague P, et al (2000) The *proteolipid protein* gene and myelin disorders in man and animal models. *Hum Mol Genet* 9:987
103. Yuki N, Yamada M, Koga M, et al (2001) Animal model of axonal Guillain-Barré syndrome induced by sensitization with GM1 ganglioside. *Ann Neurol* 49:712
104. Zheng L, Calenoff MA, Dal Canto MC (2001) Astrocytes, not microglia, are the main cells responsible for viral persistence in Theiler's murine encephalomyelitis virus infection leading to demyelination. *J Neuroimmunol* 118:256