

## Erratum to: The impact of nodal tumour burden on lymphoscintigraphic imaging in patients with melanomas

Lutz Kretschmer · Hans Peter Bertsch · Pawel Bardzik ·  
Johannes Meller · Simin Hellriegel · Kai-Martin Thoms ·  
Michael Peter Schön · Carsten Oliver Sahlmann

Published online: 10 December 2014  
© Springer-Verlag Berlin Heidelberg 2014

**Erratum to: Eur J Nucl Med Mol Imaging**  
**Doi 10.1007/s00259-014-2914-4**

Unfortunately, Fig. 1c was not published; instead, Fig. 1b was duplicated. The missing figure is reproduced here.

---

The online version of the original article can be found at <http://dx.doi.org/10.1007/s00259-014-2914-4>.

---

L. Kretschmer (✉) · H. P. Bertsch · S. Hellriegel · K.-M. Thoms ·  
M. P. Schön  
Department of Dermatology, Venereology and Allergology, Georg  
August University of Göttingen, Robert-Koch-Str 40,  
37075 Göttingen, Germany  
e-mail: [lkre@med.uni-goettingen.de](mailto:lkre@med.uni-goettingen.de)

P. Bardzik · J. Meller · C. O. Sahlmann  
Department of Nuclear Medicine, Georg-August-University of  
Göttingen, 37075 Göttingen, Germany

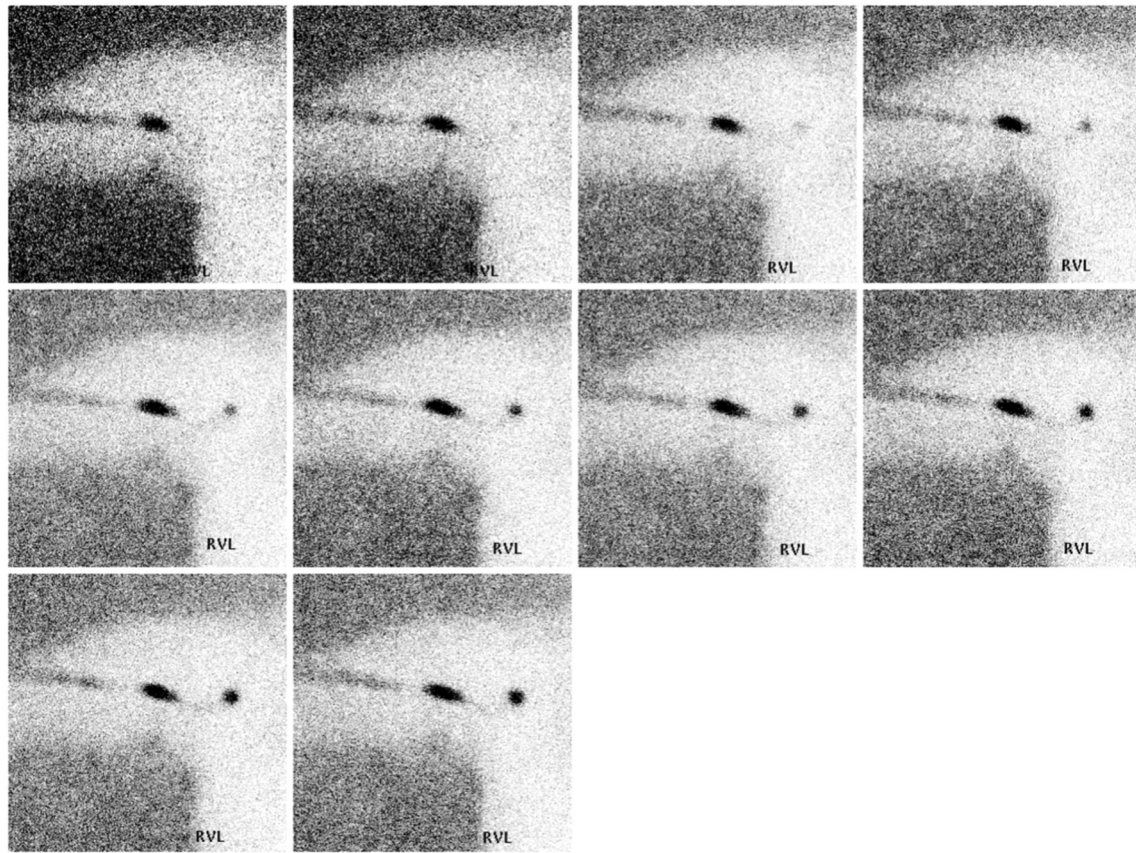


Figure 1c shows a clearly depicted lymphatic vessel. Patients with macrometastasis were more likely to show clear depiction of an afferent lymphatic vessel. In patients with clinically nonsuspicious nodes undergoing sentinel lymph node biopsy

(SLNB), the clear depiction of an afferent vessel was associated with a higher number of radioactive lymph nodes depicted and a higher number of lymph node metastases excised by SLNB plus completion lymphadenectomy.