



Test yourself question: right third toe swelling

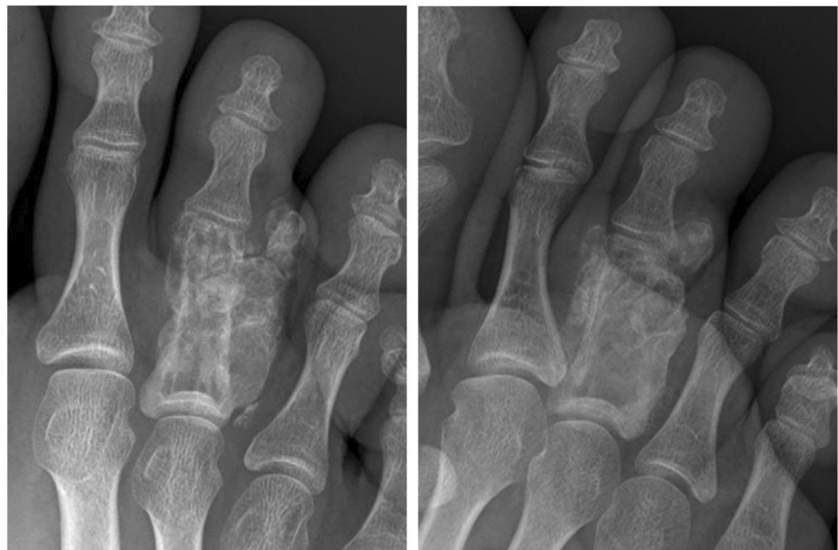Ramanan Rajakulasingam¹  · D. Lindsay² · L. Bayliss³ · A. Saifuddin¹

Published online: 4 July 2020
© ISS 2020

Question

A 21-year-old male presented with a 2-year history of right third toe swelling, which had recently become painful. He was otherwise well (Figs. 1, 2, 3, and 4).

Fig. 1 DP and oblique radiographs of the right forefoot



The diagnosis can be found at <https://doi.org/10.1007/s00256-020-03535-4>

✉ Ramanan Rajakulasingam
Ramanan.rajakulasingam1@nhs.net

D. Lindsay
daniel.lindsay1@nhs.net

L. Bayliss
lee.bayliss1@nhs.net

A. Saifuddin
Asif.saifuddin@nhs.net

¹ Department of Radiology, Royal National Orthopaedic Hospital, Brockley Hill, Stanmore, Middlesex HA7 4LP, UK

² Department of Histopathology, Radiology, Royal National Orthopaedic Hospital, Brockley Hill, Stanmore, Middlesex HA7 4LP, UK

³ Department of Orthopaedic surgery, Royal National Orthopaedic Hospital, Brockley Hill, Stanmore, Middlesex HA7 4LP, UK

Fig. 2 **a** Sagittal T1W TSE and **b** coronal fat suppressed PDW FSE MR images of the right forefoot

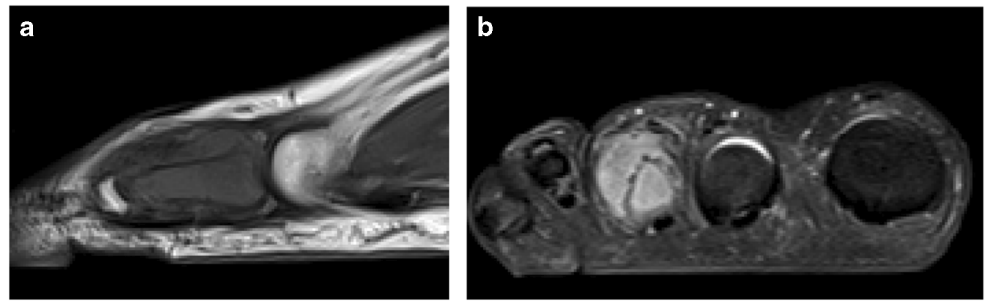


Fig. 3 Coronal CT study of the right forefoot at the time of needle biopsy

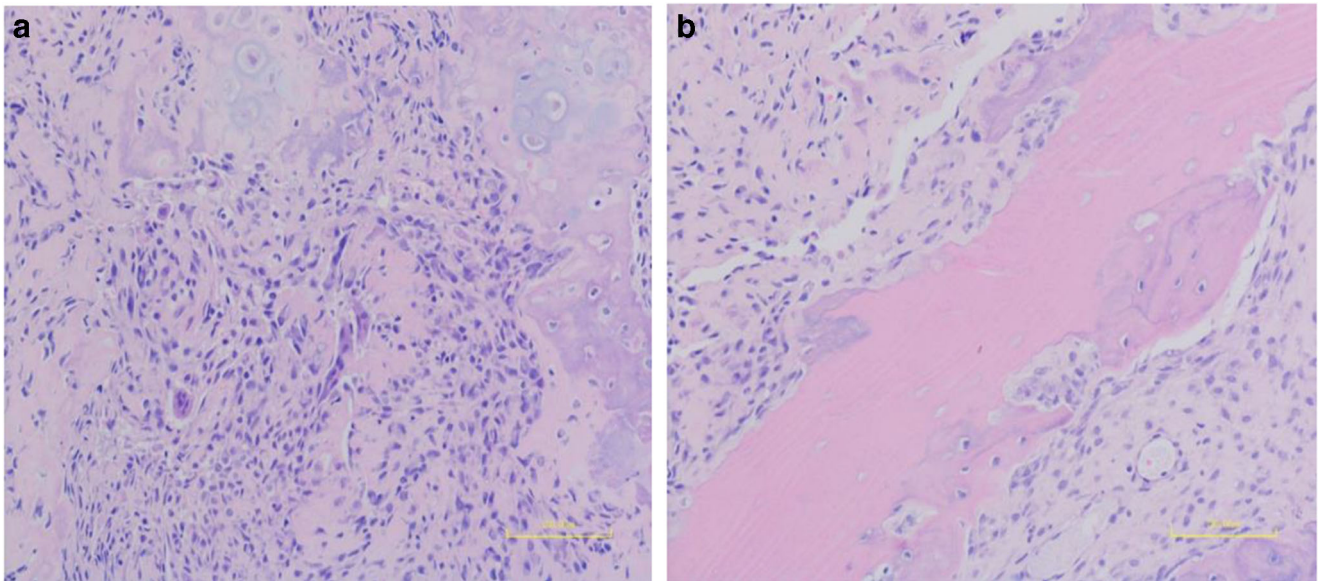
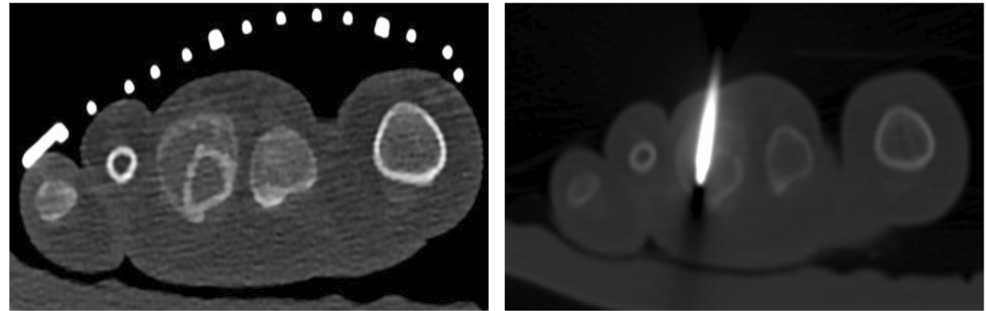


Fig. 4 **a** and **b** Microphotographs (X20, H&E)

Compliance with ethical standards

Conflict of interest The authors declare that they have no conflicts of interest.

Publisher's note Springer Nature remains neutral with regard to jurisdictional claims in published maps and institutional affiliations.