

A 4-year-old with a non-tender dorsal phalangeal lump

Leon Mieczyslaw Sergot¹ · Savvas Andronikou^{2,3} · Simon Thomas³

Published online: 4 November 2017
© ISS 2017

Keywords Pediatric · Radiology · Nora lesion · BPOP

History

A 4-year-old girl with no past medical history presented with a non-traumatic and non-tender firm lump on the dorsum of her right ring finger (Fig. 1). Follow-up imaging over the subsequent 3 months demonstrated an increase in size of the lesion (Fig. 2).

The diagnosis can be found at doi: <https://doi.org/10.1007/s00256-017-2801-8>

✉ Leon Mieczyslaw Sergot
leon.sergot@doctors.org.uk

¹ University Hospitals Bristol NHS Trust, Marlborough Street, Bristol BS1 3NU, England

² Department of Paediatric Radiology, University of Bristol, Bristol, England

³ Bristol Royal Hospital for Children, Bristol, England

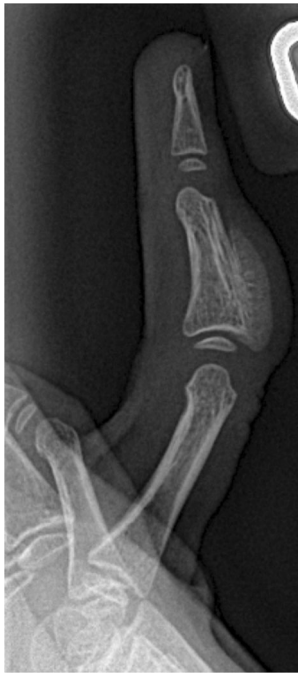

Fig. 1 Radiograph at initial presentation

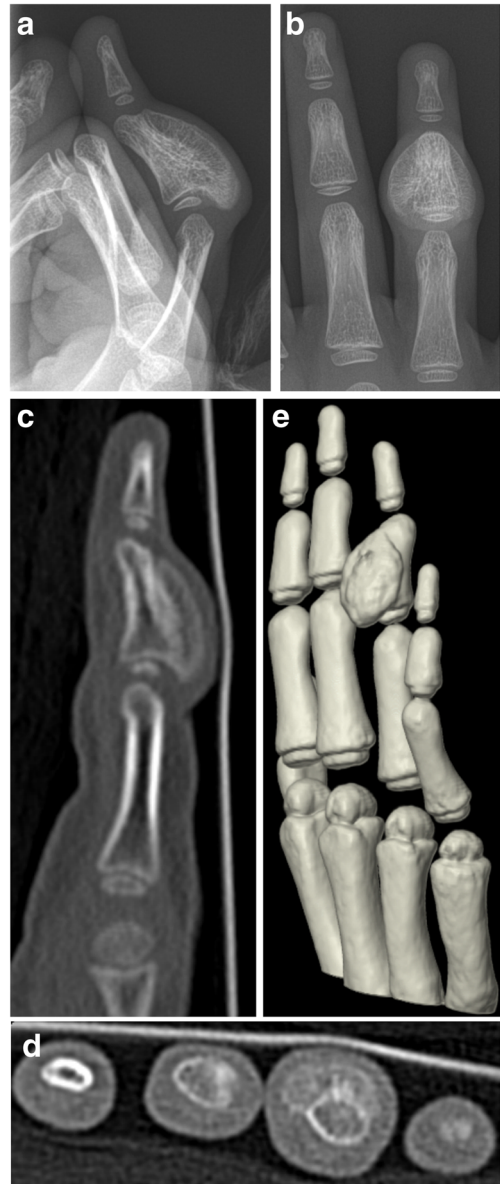


Fig. 2 a, b Radiographs and c–e CT reconstructions at 3-month follow-up