

Hip pain

Nathan R. Webb¹ · M. K. Jesse¹

Published online: 15 January 2016

© ISS 2016

Sixty- eight- year-old female with 6 weeks of progressively worsening right hip/groin pain, now unable to ambulate (Figs. 1, 2, 3, and 4).

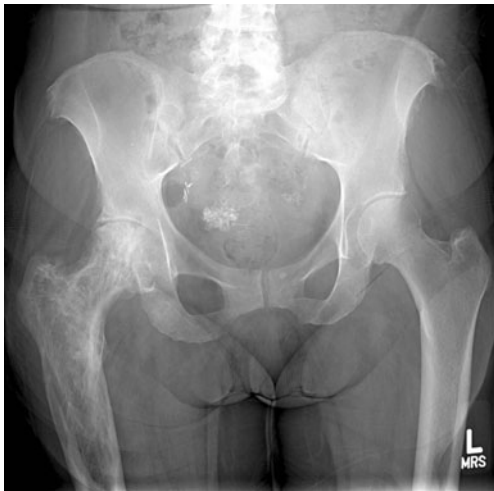

Fig. 1 Frontal pelvis radiograph

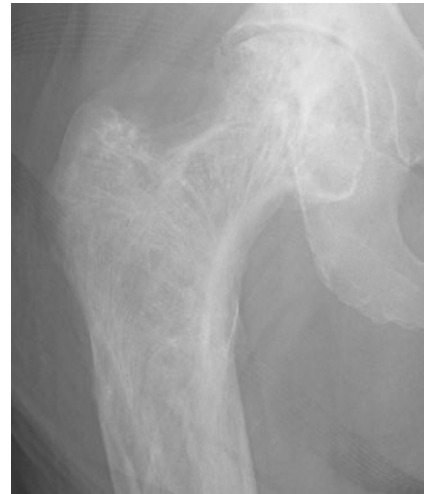

Fig. 2 Magnification view of frontal right hip radiograph

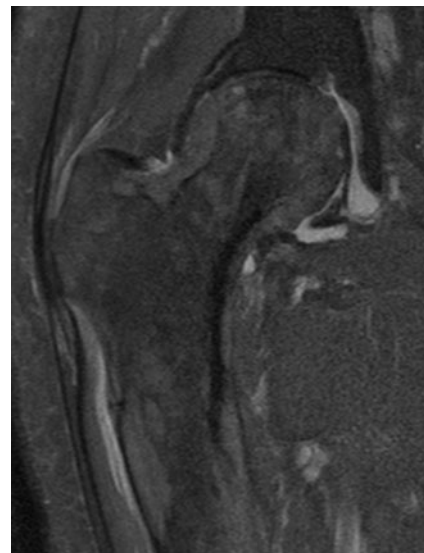


Fig. 3 Coronal PD FS image of right hip

The diagnosis can be found at doi: 10.1007/s00256-016-2337-3

✉ Nathan R. Webb
nathan.webb@ucdenver.edu

¹ Department of Radiology, University of Colorado School of Medicine, Mail Stop 8200, AO1, Rm 2414, 12631 East 17th Avenue, Aurora, CO 80045, USA

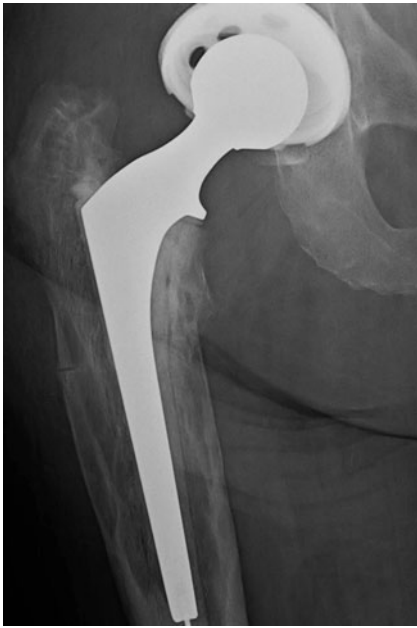

Fig. 4 Magnification view of frontal radiograph of right hip, taken 8 weeks after prior imaging. Patient underwent interval right total hip arthroplasty

Compliance with ethical standards

Conflict of interest The authors declare that they have no conflict of interest.