

Test yourself: right thigh mass

Kerry L. Thomas · Evita Henderson-Jackson ·
Jamie T. Caracciolo

Published online: 12 February 2015
© ISS 2015

TEST YOURSELF:

Question – Painful right thigh mass

Twenty-seven year-old male presents with a 6 month history of a painful right thigh mass with rapid enlargement and new onset of bleeding (Figs. 1, 2, 3 and 4)

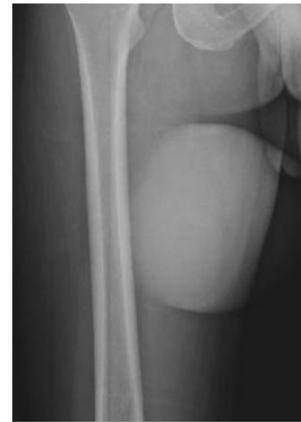

Fig. 1 AP radiograph of the right thigh

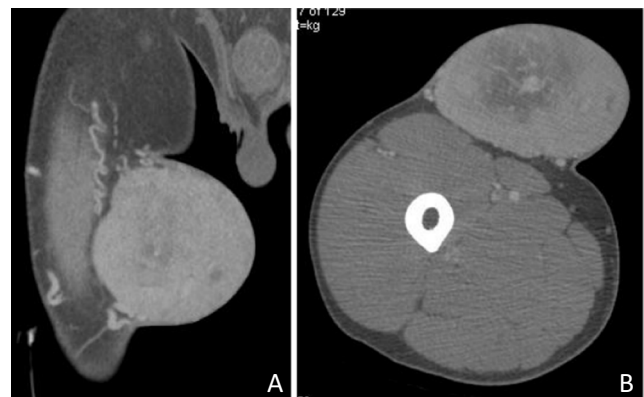

Fig. 2 (a) Coronal and (b) axial contrast-enhanced CT of the right thigh

The diagnosis can be found at doi: [10.1007/s00256-015-2113-9](https://doi.org/10.1007/s00256-015-2113-9)

K. L. Thomas · J. T. Caracciolo (✉)
Department of Diagnostic Imaging, Moffitt Cancer Center,
Tampa, FL, USA
e-mail: jamie.caracciolo@moffitt.org

E. Henderson-Jackson
Department of Anatomic Pathology, Moffitt Cancer Center,
Tampa, FL, USA

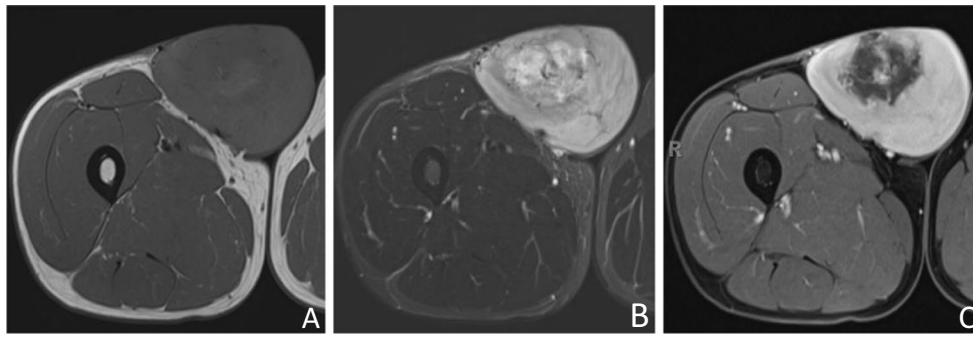


Fig. 3 Axial (a) T1-w, (b) STIR, and (c) fat-suppressed T1-w contrast-enhanced MRI of the right thigh

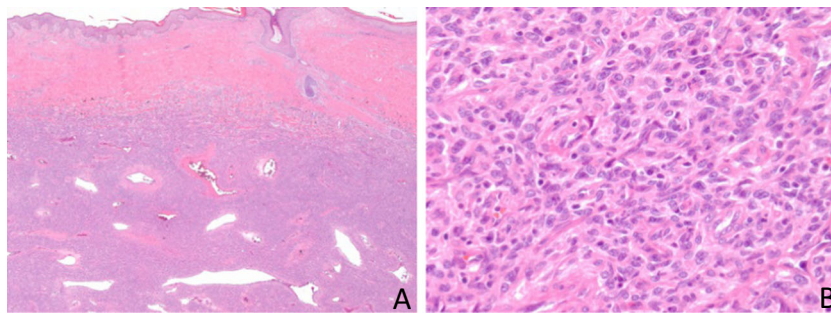


Fig. 4 Histopathological photomicrographs (hematoxylin and eosin staining) at (a) low power depicting lesion involving the subcutis and deep dermis exhibiting a monomorphic storiform pattern with

branching hemangiopericytoma-like vessels and (b) bland-appearing spindle cells with plump, ovoid to elongated vesicular nuclei and indistinct, pale eosinophilic cytoplasm (40x)